

## Multiple cerebral abscesses in decompensated cirrhosis of liver as a mimicker of hepatic encephalopathy: A case report

Vishal Madhukar Sawale<sup>1</sup>, Durjoy Lahiri<sup>1</sup>, Souvik Dubey<sup>2</sup>, Nirmalendu Sarkar<sup>3</sup>

From<sup>1</sup>Resident, <sup>2</sup>Senior Resident, Department of Neurology, <sup>3</sup>Ex-Professor and Head, Department of General Medicine, IPGMER and SSKM Hospital, Kolkata, West Bengal, India

**Correspondence to:** Durjoy Lahiri, Department of Neurology, IPGMER and SSKM Hospital, Kolkata, West Bengal, India.

E-mail: dlahiri1988@gmail.com

Received – 04 June 2018

Initial Review – 28 June 2018

Accepted – 23 July 2018

### ABSTRACT

Cirrhosis of the liver is a state of immune dysregulation. It can give way to many infections. Brain abscess, though uncommonly reported in cirrhotic patients, deserves special attention as it presents a diagnostic and therapeutic challenge for physicians. We present here, the case of a 65-year-old diabetic and hypertensive female patient, with cirrhosis of the liver, who presented to us with fever and altered sensorium. She had mild neutrophilic leukocytosis and her serum ammonia level was slightly elevated. She was managed conservatively for hepatic encephalopathy precipitated by infection. No obvious source of infection was found on routine investigation and culture. Broad-spectrum intravenous antibiotic coverage was provided at the earliest, but the patient succumbed to multiorgan failure.

**Key words:** Brain abscess, Cirrhosis, Hepatic encephalopathy, Mimic

Cirrhosis of the liver is an immunocompromised state due to reticuloendothelial dysfunction and portacaval shunting [1]. Malnutrition and alcohol abuse are considered as contributory factors to immunodeficiency in cirrhosis of the liver. Bacterial infections in cirrhosis are frequent, particularly in decompensated patients. They account for significant mortality in this group of patients. Pneumonia, urinary tract infection, peritonitis, bacteremia, and meningitis are commonly encountered bacterial infections in decompensated cirrhosis [2]. Although brain abscess in cirrhosis has been infrequently reported in the literature, it is indeed a life-threatening situation in cirrhotic patients. The treating physician often faces not only a diagnostic dilemma but also therapeutic challenge in such cases. Brain abscess develops either by spread from a contiguous focus or by hematogenous spread from a distant focus, such as an intra-abdominal infection, endocarditis, urinary tract infection, or pulmonary infection. We present here, a case of multiple brain abscesses in decompensated hepatic cirrhosis, with a clinical presentation mimicking hepatic encephalopathy.

### CASE REPORT

A 65-year-old overweight (body mass index - 25.5) female patient, diagnosed case of cirrhosis of the liver with portal hypertension, presented to our emergency department with low-grade fever, and altered sensorium for 3 days. She was diagnosed with diabetes mellitus (DM) 5-year back and hypertension 1-year back and was on regular medication for both the disorders. 1-year back, she was

admitted to our hospital with hematemesis, melena, and altered sensorium, for which she was evaluated thoroughly and was diagnosed to have cirrhosis of the liver with portal hypertension on the basis of biochemical tests, ultrasound with Doppler and upper gastrointestinal endoscopy. The cause of hepatocellular failure was not obvious. She was non-alcoholic and her viral markers were negative. She denied undergoing liver biopsy. Hence, a presumptive diagnosis of non-alcoholic was made based on the presence of overweight, DM, and steatohepatitis dyslipidemia (raised low-density lipoproteins cholesterol and very low-density lipoproteins cholesterol) at that time.

On physical examination, she had sacral edema as well as mild pedal edema, mild pallor, and icteric tinge in the conjunctiva. Abdominal examination revealed Grade-2 ascites, a palpable left lobe of the liver and splenomegaly (4 cm below costal margin in splenic axis). Glasgow coma score was 9/15, with preserved oculocephalic reflex and light reaction (both direct and consensual) of both pupils. Direct ophthalmoscopy revealed blurred disc margins suggestive of papilledema in both eyes. There was hypotonia in both lower limbs. Her reflexes were hypoactive in all the four limbs with bilateral extensor plantar responses. There were no meningeal signs and no focal neurologic deficits.

As the deterioration of sensorium started after the onset of fever, in this case, the possibility of systemic infection leading to hepatic encephalopathy was high. Hence, although detailed clinical examination did not reveal any obvious source of infection, she was started on broad-spectrum antibiotics besides routine management of hepatic encephalopathy.

Complete blood count revealed anemia (hemoglobin 8.5 g%), mild leukocytosis (12,000/cu mm), and thrombocytopenia (70,000/cu mm). In the liver function test, hypoalbuminemia (2 g/dl) and slightly raised serum bilirubin (3.5 mg/dl) were detected. Prothrombin time was deranged (P-Time - 14 s; international normalized ratio - 1.2). Her renal profile was abnormal with urea of 55 mg/dl and creatinine 1.9 mg/dl. Serum sodium level was 132 meq/L and potassium was found to be 4.2 meq/L. The Child-Pugh score was 8/15. Serum ammonia level was 72 µg/dl (reference range - 35–65 µg/dl). Urine microscopy was normal and culture-negative. Chest X-ray revealed bilateral mild pleural effusion without any suggestion of pneumonia. The ascitic fluid study revealed high serum ascitic albumin gradient (1.4) and cell count 120/mm<sup>3</sup> with a predominance of mononuclear cells (80%). The ascitic fluid culture showed no growth. Blood culture was sent and the result was being awaited. Blood culture after 72 h came to be negative.

A cerebrospinal fluid analysis was planned, keeping in mind the possibility of central nervous system (CNS) infection. Routine non-contrast computed tomography was performed, before lumbar puncture, to rule out any intracranial space-occupying lesion. It revealed remarkable cerebral edema in the frontoparietal regions of both hemispheres (Fig. 1). Such magnitude of edema was, to some extent, unusual for hepatic encephalopathy. Underlying mass lesion seemed to be a possibility. Magnetic resonance imaging (Fig. 2) was done which revealed the presence of multiple moderately large smooth margin ring-enhancing lesions with diffuse perilesional edema in both frontal lobes with a few small satellite nodules. Magnetic resonance spectroscopy (MRS) revealed decreased N-acetyl aspartate (NAA), creatine (Cr), and choline (Cho), and a prominent lipid peak at the lesion. A radiological diagnosis of multiple cerebral abscesses was made, the basis on which she was put on intravenous broad-spectrum antibiotic therapy (meropenem and vancomycin). Unfortunately, her physical condition kept on deteriorating until the patient died 14 days after admission from multiple organ failure.

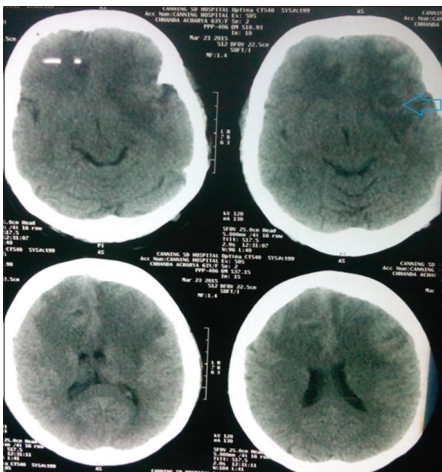


Figure 1: Computed tomography scan brain shows large hypodense areas in both frontal lobes, suggestive of extensive edema

## DISCUSSION

Brain abscess is a serious form of infection which requires urgent initiation of antibiotic therapy. Although it can occur in both immunocompetent and immunocompromised host, an impaired host-defense mechanism is considered a risk factor for brain abscess [3]. Brain abscess develops either by spread from a contiguous focus or by hematogenous spread from a distant focus, such as intra-abdominal infection, endocarditis, urinary tract infection, or pulmonary infection [4]. However, even after a thorough search, the source of inoculation to the CNS may remain unknown in up to one-third of cases. Immunosuppressed patients comprise a “population at risk” for brain abscess. This group includes transplant patients, advanced cancer patients, and patients undergoing chemotherapy, diabetic patients as well as patients with liver cirrhosis [5]. Additional risk factors are the implantation of a foreign body (shunt), high-grade glioma, and irradiation.

Brain abscess has been uncommonly reported in cirrhotic patients. However, Kao *et al.* reported in their case series that 6 of 53 patients with brain abscess had underlying cirrhosis. Patients with liver cirrhosis presented with non-specific clinical features and all of them died soon [3]. In yet another recent population-based prospective study, it was found that cirrhotic patients, particularly those with complicated cirrhosis, have a higher risk of the occurrence of brain abscesses than non-cirrhotic patients [6]. This high mortality rate in cirrhotic patients is multifactorial. First, it is difficult to differentiate brain abscess from hepatic encephalopathy; second, only 34% of patients have the triad of a headache, fever, and focal neurologic deficits. Third, cirrhotic patients can often have episodes of fever, caused by endotoxemia or spontaneous bacterial peritonitis [3].

Hence brain abscess in cirrhotics may be missed unless there is a high index of clinical suspicion. Our patient had altered sensorium with a bilateral plantar extensor plantar response and papilledema without any focal neurologic deficits; playing the mimic of hepatic encephalopathy as close as one would imagine. Her serum ammonia level was slightly above the normal range reflecting the fact that she had encephalopathy precipitated by CNS infection in the form of multiple cerebral abscesses. In the case series of brain abscess in cirrhotics by Chung *et al.* [7], both the patients had type 2 DM, similar to the case, we are reporting. DM may have acted as an additional factor for immune dysregulation in these cirrhotic patients.

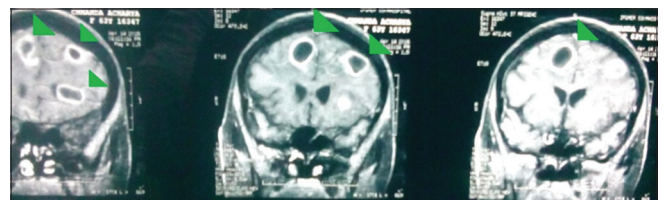


Figure 2: Magnetic resonance imaging brain with contrast (coronal section) shows multiple ring-enhancing smooth margin cystic lesions surrounded by edema in both frontal lobes, suggestive of cerebral abscess

Liver dysfunction paves the way for several abnormalities of defense mechanisms from depressed humoral and cell-mediated immunity. Bacterial translocation from the intestine induces bacteremia, while impaired hepatic bacterial clearance leads to a failure to control the infection, culminating in brain abscess [1]. In fact, some cases of brain abscess have been reported after endoscopic procedures, which induce bacteremia [8-10]. Furthermore, *Klebsiella pneumoniae*, which can colonize the gastrointestinal tract, is a frequently reported pathogen of brain abscess in cirrhotic patients [7,11].

Hepatic failure patients are prone to developing encephalopathy in the face of any infection. Brain abscess in such a situation poses a diagnostic challenge. The clinical features may well be confusing. Moreover, cirrhotic patients, due to their poor immune status, may not be able to mount an adequate immune response to brain abscess. Hence, the usual picture of high fever and neutrophilic leukocytosis is not seen. The focal neurologic deficit may be a good clue in these circumstances but may not always be seen as in our index case.

MRS can give some clues about the nature of an intracranial mass lesion. It becomes particularly handy in the presumptive diagnosis of brain abscess where urgent antibiotic therapy is crucial. In MRS, non-neoplastic lesions such as cerebral infarction and brain abscess show decrease in NAA, Cr, and Cho, while brain tumors generally have decreased NAA and Cr, with elevated Cho [12]. A prominent lipid peak is generally present in brain abscess, metastatic brain tumor, or glioblastoma. In the present case, MRS findings were clearly corroborating abscess.

The causative organisms of brain abscess may be aerobic/anaerobic, Gram-positive/negative bacterial, and fungal infections [8]. The overall incidence of staphylococcal-induced abscesses has dropped over the past three decades, while the proportion of streptococcal-induced abscesses has remained relatively static. This may be related to more effective treatment of staphylococcal infection. In a study from Taiwan with 33 patients suffering from brain abscess, only two incidences of *K. pneumoniae* and none of *Staphylococcus aureus* were found, and the most common pathogen was  $\alpha$ -hemolytic *Streptococcus* species [3]. Treatment of brain abscess requires a combination of antimicrobials, surgical intervention, and eradication of primary foci. Surgical intervention is the only procedure for definite microbiologic proof and should be done as early as possible. However, the surgical risk is very high in cirrhotic patients. Antibiotic therapy would be inadequate if the chosen antibiotics are given in insufficient dose and duration; the antibiotics have poor CNS penetration or are directed against resistant organisms.

## CONCLUSION

Brain abscess in cirrhosis of the liver has a poor prognosis with high mortality. It can be a close mimicker of hepatic encephalopathy and hence should be considered in the differential diagnosis of cirrhotic patients presenting with fever and altered sensorium. A careful assessment and high clinical suspicion for the presence of structural brain lesion can lead to a proper diagnosis.

## REFERENCES

- Ashare A, Monick MM, Powers LS, Yarovinsky T, Hunninghake GW. Severe bacteremia results in a loss of hepatic bacterial clearance. *Am J Respir Crit Care Med* 2006;173:644-52.
- Merli M, Lucidi C, Giannelli V, Giusto M, Riggio O, Falcone M, *et al.* Cirrhotic patients are at risk for health care-associated bacterial infections. *Clin Gastroenterol Hepatol* 2010;8:979-85.
- Kao PT, Tseng HK, Liu CP, Su SC, Lee CM. Brain abscess: Clinical analysis of 53 cases. *J Microbiol Immunol Infect* 2003;36:129-36.
- Lu CH, Chang WN, Lui CC. Strategies for the management of bacterial brain abscess. *J Clin Neurosci* 2006;13:979-85.
- Lu CH, Chang WN, Wu HS. *Klebsiella pneumoniae* meningitis: Analysis on clinical features of thirty-two adult patients. *Zhonghua Yi Xue ZaZhi (Taipei)* 1997;60:296-302.
- Chen YC, Hung TH, Tseng KC, Tseng CW, Hsieh YH, Tsai CC, *et al.* Increased occurrence of brain abscesses in cirrhotic patients: A population-based 3-year follow-up study. *Turk J Gastroenterol* 2017;28:342-6.
- Chung CL, Lieu AS, Chen IY, Kwan AL, Howng SL. Brain abscess in adult cirrhotic patients: Two case reports. *Kaohsiung J Med Sci* 2007;23:34-9.
- Shih HI, Lee HC, Chuang CH, Ko WC. Fatal *Klebsiella pneumoniae* meningitis and emphysematous brain abscess after endoscopic variceal ligation in a patient with liver cirrhosis and diabetes mellitus. *J Formos Med Assoc* 2006;105:857-60.
- Laviv Y, Ben-Daviv U, Vated M, Rappaport ZH. Brain abscess following endoscopic ligation of esophageal varicose veins. *Acta Neurochir (Wien)* 2010;152:733-4.
- ASGE STANDARDS OF PRACTICE COMMITTEE, Banerjee S, Shen B, Baron TH, Nelson DB, Anderson MA, *et al.* Antibiotic prophylaxis for GI endoscopy. *Gastrointest Endosc* 2008;67:791-8.
- Cho KT, Park BJ. Gas-forming brain abscess caused by *Klebsiella pneumoniae*. *J Korean Neurosurg Soc* 2008;44:382-4.
- Möller-Hartmann W, Herminghaus S, Krings T, Marquardt G, Lanfermann H, Pilatus U, *et al.* Clinical application of proton magnetic resonance spectroscopy in the diagnosis of intracranial mass lesions. *Neuroradiology* 2002;44:371-81.

*Funding: None; Conflict of Interest: None Stated.*

**How to cite this article:** Sawale VM, Lahiri D, Dubey S, Sarkar N. Multiple cerebral abscesses in decompensated cirrhosis of liver as a mimicker of hepatic encephalopathy: A case report. *Indian J Case Reports*. 2018;4(4):304-306.

Doi: 10.32677/IJCR.2018.v04.i04.017