

Case report of multiple hepatic microabscesses in a term neonate

Sanjay Bafna, S B Kirthana, Vibha Bafna, Sagar Lad, Mergu Ravikanth

From Department of Pediatrics, Jehangir Hospital, Pune, Maharashtra, India

Correspondence to: S B Kirthana, Department of Pediatrics, Jehangir Hospital, Pune, Maharashtra, India. Phone: +91-9591329885.

E-mail: kirthanasb92@gmail.com

Received – 20 January 2018

Initial Review – 26 February 2018

Published Online – 14 April 2018

ABSTRACT

Neonatal liver abscess is a rare entity, which usually occurs in preterm infants with sepsis and certain risk factors like umbilical vein catheterization. Neonatal hepatic abscess has a non-specific clinical presentation, and a high index of suspicion for this condition is warranted in case of unresolving sepsis especially in the presence of risk factors. Ultrasonography of abdomen is an important investigation in a febrile neonate with sepsis. Here, we report a case of hepatic microabscesses in a term neonate without any significant risk factors. We want to report this case because of its rare occurrence particularly in a term neonate without significant risk factors. This case also emphasizes the utility of abdominal ultrasonography in a febrile neonate with unresolving sepsis.

Key words: *Hepatic abscess, Neonate, Sepsis, Staphylococcus aureus*

Neonatal liver abscess is a rare entity, and till date, 120 cases have been reported in literature [1]. In many babies dying of neonatal sepsis liver, microabscesses go undetected and are detected on postmortem examination [2]. In general, they occur in preterm infants with certain risk factors such as umbilical vein catheterization, systemic sepsis, necrotizing enterocolitis, and total parenteral nutrition catheters [2-4]. Thus, a strong index of suspicion is needed for this condition in neonates suffering with unresolving sepsis with above risk factors. Here, we report a case of hepatic microabscesses in a term neonate. This baby did not have any of the known risk factors for hepatic microabscesses. Although this baby had low birth weight; it is not a risk factor mentioned in literature for hepatic microabscesses and it was a full term baby. Neonates with this condition present with non-specific features similar to sepsis and diagnosis may be established only after ultrasonography.

CASE REPORT

A male neonate with birth weight of 1.9 kg was born of emergency lower segment cesarean section in view of per vaginam leak for 6–8 h at 37 weeks of gestation. Mother was primigravida aged 34 years with no other significant antenatal risk factors. Baby presented, on 12th day of life, with high fever, decreased activity, and feeding since 1 day. On examination, the baby was febrile, lethargic and had signs of poor perfusion. On abdominal examination, the baby did not have organomegaly or abdominal distension. Rest of the systemic examination was normal.

The baby was admitted to neonatal intensive care unit and was given fluid bolus and started on intravenous fluids. Investigations showed polymorphonuclear leukocytosis, high C-reactive

proteins (91 mg/dl) with normal urine and cerebrospinal fluid examination. He was started on intravenous cefotaxime and amikacin after sending cultures. Dopamine was started as he continued to have poor perfusion. At 48 h there was a partial clinical improvement, however, in view of rising C-reactive proteins (118 mg/dl) and tentative growth in cultures of blood and urine; antibiotics were stepped up to intravenous meropenem and linezolid. Liver function tests were normal (total bilirubin -1.64, direct bilirubin - 0.1, indirect bilirubin - 1.54, and alanine aminotransferase - 25.9IU).

Ultrasonography of abdomen done in view of suspected urinary tract infection showed a normal urinary system with an incidental finding of multiple microabscesses in the liver largest measuring 1.5 cm (Fig. 1). Blood culture grew *Staphylococcus aureus* resistant to ampicillin, penicillin, amoxiclav and sensitive to cephalosporins, linezolid, clindamycin and amikacin. Serial ultrasonography of abdomen showed partial regression of hepatic microabscesses. Intravenous antibiotics meropenem and linezolid were given for 14 days; the baby was discharged with oral linezolid for 14 days. Ultrasonography of abdomen on follow-up after 1 week showed complete resolution of all microabscesses. Baby is well with good weight gain.

DISCUSSION

Neonatal liver abscess is a rare entity, and till date, 120 cases have been reported in literature [1]. Reported number of this rare condition amounts to 27 in past 6 years [2]. Among 7500 autopsies from 1917 to 1967, only 3 neonates had multiple liver microabscesses [5]. In general, they occur in preterm infants with certain risk factors like umbilical vein catheterization [2].

Systemic sepsis, necrotizing enterocolitis, and central parenteral nutrition catheters are the other risk factors [3,4]. Our neonate was a term neonate with low birth weight, with no other risk factors. Gram-negative enteric bacteria and *S. aureus* were the most common organisms isolated [6] (Table 1). Simeunovic *et al.* did a retrospective chart review of six neonates diagnosed with hepatic abscesses from 2000 to 2006. Five of them were preterm and common organisms implicated were *Klebsiella* (3), *Staphylococcus* (3), *Gonococcus* (1), and *Enterobacter* (1) [7] (Table 1). In our case blood, the culture grew *S. aureus*.

The classical presentation of liver abscess with fever, hepatomegaly, and right upper abdominal pain is generally not present in neonates. The signs and symptoms are nonspecific and are essentially those of sepsis or secondary metastatic complications such as meningitis, pneumonia, or peritonitis [8]. Our neonate had features of sepsis, with poor perfusion presenting

on day 12 of life with no hepatomegaly. Baby showed partial improvement by day 3 of antibiotic therapy. Ultrasonography of abdomen done in view of suspected urinary tract infection led to the incidental detection of multiple hepatic microabscesses. We upgraded the antibiotics to intravenous meropenem and linezolid with clinical improvement and gradual resolution of microabscesses.

Tan *et al.* reported 6 preterm neonates with hepatic abscess who had clinical features of unresolving sepsis with persistent positive blood culture even after appropriate antibiotic therapy. This led them to investigate these babies with ultrasonography of hepatobiliary system [6]. Similarly, De Franco *et al.* reported a case of term neonate with hepatic abscess. This baby was ventilated for meconium aspiration syndrome and had an umbilical vein catheter line inserted. The baby developed unresolving sepsis in 2nd week of life with glomerulonephritis and persistent growth in

Table 1: Details of previous studies

Study and year of publication	No. of term/preterm	Clinical features	Risk factor	Type of liver abscess	Treatment	Organism	Outcome
Semerci <i>et al.</i> , 2016 [1]	3 preterms	Severe sepsis not responding to IV antibiotics	Prematurity, late-sepsis, umbilical catheterization, necrotizing enterocolitis, previous antibiotic therapy	Solitary hepatic abscess	IV antibiotics	<i>Staphylococcus</i> spp. in two cases and <i>Pseudomonas</i> spp. in one case	Responded well to antibiotic therapy alone
Singh <i>et al.</i> , 2015 [13]	1 term at day of life 12	Persistent positive blood culture despite antibiotics	IV fluids for respiratory distress initial 2 days of life	Multiple microabscesses	vancomycin and cloxacillin	<i>Staphylococcus aureus</i>	Recovered baby had associated portal vein thrombosis which resolved with treatment of hepatic abscess
Simeunovic <i>et al.</i> , 2009 [7]	6 5 preterm 1 post mature	Sepsis signs Tender hepatomegaly Ileus	Preterm, 2 had malpositioned UVC		3 - medical 2 - needle asp 1 -open drainage	3 - <i>Klebsiella</i> 3 - <i>Staphylococcus aureus</i>	Recovered
Lam <i>et al.</i> , 2005 [3]	1 preterm	Abdominal distension? Perforation	Preterm, Malposition of UVC				
Moens <i>et al.</i> , 2003 [14]	2 preterms	Persistent sepsis	Preterm, UVC	Solitary abscess	Percutaneous drainage with iv antibiotic	One child pus has staph epidermidis Another one was sterile	Recovered
De Franco <i>et al.</i> , 2000 [9]	1 term	Persistent sepsis and presence of glomerulonephritis	Baby had MAS on ventilator, had UVC	Solitary abscess	Surgical drainage with iv antibiotics	Coagulase-negative staph	Recovered
Tan <i>et al.</i> , 2005 [6]	6 preterms	Persistent positive blood culture despite antibiotics	Preterm, UVC	2 babies had solitary	2 needed surgical drainage	<i>Chryseobacterium gleum</i> , MRSA, <i>Candida albicans</i> , <i>Acinetobacter</i> , <i>Klebsiella</i>	3 died
Kandall <i>et al.</i> , 1974 [15]	1 neonate	Sepsis died at day 25	-	Solitary abscess - at postmortem examination	-	-	-

MRSA: Methicillin-resistant *Staphylococcus aureus*

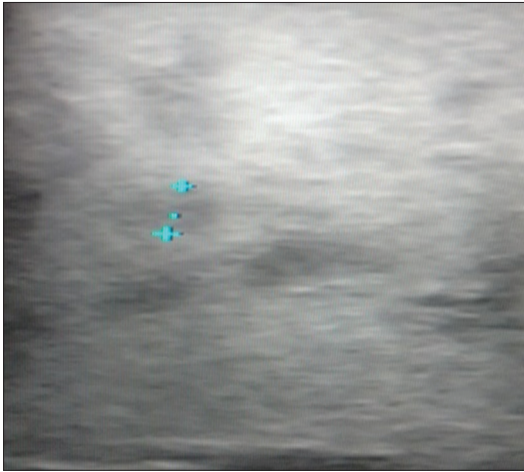


Figure 1: Ultrasonography of liver showing multiple microabscesses largest measuring 1.5 cm.

blood culture even after 1 week of antibiotics [9] (Table 1).

Thus, undetected hepatic microabscesses could be a cause for unresolving sepsis, and high index of suspicion for this condition is warranted in such a scenario. The hepatic abscess can be either multiple or solitary. Multiple liver abscesses are multiple, small in size, not drainable, usually not due to umbilical infection and have a fulminant course. Whereas solitary liver abscess is larger, well localized, can be drained by surgical methods and has a sub-acute course [10]. Ultrasonography of abdomen is the reliable initial imaging study in the newborns with clinical suspicion of hepatic abscess. Computerized tomography (CT)/magnetic resonance imaging with contrast is another modality which is rarely needed. Open surgical drainage with intravenous antibiotics is the traditional treatment-employed for a solitary hepatic abscess. Presently, CT guided percutaneous drainage with intravenous antibiotics is preferred with ultrasonography monitoring for resolution. Microabscesses usually resolve with conservative management [11]. In a case series reported by Tan *et al.*, out of 6 neonates, 2 were required surgical drainage, and 4 were managed conservatively. Three of these neonates died of fulminant hepatic failure [6].

Duration of treatment is based on clinical response with parenteral treatment recommended for at least 2 weeks [5]. Duration of antibiotics should be for a minimum period of 3 weeks [12]. Our neonate was given meropenem and linezolid for 14 days followed by oral linezolid for 14 days. There was complete resolution of all abscesses and baby is doing well with good weight gain on follow-up.

CONCLUSIONS

Neonatal hepatic abscess has non-specific clinical presentation similar to sepsis and a high index of suspicion for this condition is

warranted in case of unresolving sepsis especially in the presence of risk factors. Ultrasonography abdomen is an important investigation in a febrile neonate with sepsis; especially with organisms like staphylococcus which has propensity to cause seeding in multiple organs. Early recognition and treatment of hepatic abscess with intravenous antibiotics may prevent the need for surgical intervention and will also reduce the mortality and morbidity associated with the untreated and partially treated cases.

REFERENCES

1. Semerci SY, Babayigit A, Cebeci B, Buyukkale G, Cetinkaya M. Hepatic abscesses in preterm infants: Report of three cases and review of the literature. *J Trop Pediatr* 2016;62:255-60.
2. Oktav B, Moralioglu S, Celayir AC, Pektas O. Liver abscess: Increasing occurrence in premature newborns. *J Neonat Surg* 2013;2:23.
3. Lam HS, Li AM, Chu WC, Yeung CK, Fok TF, Ng PC, *et al.* Mal-positioned umbilical venous catheter causing liver abscess in a preterm infant. *Biol Neonate* 2005;88:54-6.
4. Tariq AA, Rudolph N, Levin EJ. Solitary hepatic abscess in a newborn infant: A sequele of umbilical vein catheterization and infusion of hypertonic glucose solutions. *Clin Pediatr* 1974;13:1081-2.
5. Overturf GD. Infections of liver chap 10. In: Remington J, Klein J, Baker W, editors. *Infectious Diseases of Fetus and Newborn*, 8th ed. Philadelphia: Elsevier Saunders; 2015. p. 1092-100.
6. Tan NW, Sriram B, Tan-Kendrick AP, Rajadurai VS. Neonatal hepatic abscess in preterm infants: A rare entity? *Ann Acad Med Singapore* 2005;34:558-64.
7. Simeunovic E, Arnold M, Sidler D, Moore SW. Liver abscess in neonates. *Pediatr Surg Int* 2009;25:153-6.
8. Moss TJ, Pysher TJ. Hepatic abscess in neonates. *Am J Dis Child* 1981;135:726-8.
9. De Franco PE, Shook LA, Goebel J, Lee B. Solitary hepatic abscess with associated glomerulonephritis in a neonate. *J Perinatol* 2000;20:384-6.
10. Sharma S, Mohta A, Sharma P. Hepatic abscess in a preterm neonate. *Indian Pediatr* 2007;44:226-8.
11. Diamet MJ, Stanle YP, Kangarlo OH. Percutaneous aspiration and catheter drainage of abscesses. *J Pediatr* 1986;108:204.
12. Novak DA, Dolson DJ. Bacterial, parasitic and fungal infections of the liver. In: Suchy FJ, editor. *Liver Disease in Children*. St.Louis: Mosby; 1994. p. 550-68.
13. Singh D, Venkateshwar V, Bhatia M. Neonatal hepatic abscess with resolving portal vein thrombosis. *Med J Armed Forces India* 2015;71:82-4.
14. Moens E, Dooy JD, Jansens H, Lammens C, Op de Beeck B, Mahieu L, *et al.* Hepatic abscesses associated with umbilical catheterisation in two neonates. *Eur J Pediatr* 2003;162:406-9.
15. Kandall SR, Johnson AB, Gartner LM. Solitary neonatal hepatic abscess. *J Pediatr* 1974;85:567-9.

Funding: None; Conflict of Interest: None Stated.

How to cite this article: Bafna S, Kirthana SB, Bafna V, Lad S, Ravikanth M. Case report of multiple hepatic microabscesses in a term neonate. *Indian J Child Health*. 2018; 5(3):228-230.

Doi: 10.32677/IJCH.2018.v05.i03.021