

Gluteal rhabdomyosarcoma in a newborn – A case report

Prakash Agarwal, R K Bagdi, V Raghupathi*

*From Department of Pediatric Surgery and *Pediatrics, Apollo Children's Hospital, Chennai, India*

Correspondence to: Dr Prakash Agarwal, F-31 H block, Jains Avantika Apartments, Manapakkam, Chennai-600116, India. E-mail: agarwal_prakash@hotmail.com

Received – 02 April 2014

Initial Review – 19 April 2014

Published Online – 06 May 2014

ABSTRACT

Rhabdomyosarcoma is the most common soft tissue malignancy of childhood; however, can be seen very rarely in the neonatal period also. It may arise anywhere in the body; head and neck, and genitourinary regions being the most frequent sites. Truncal and gluteal rhabdomyosarcoma is relatively rare occurrence. We report a neonate with embryonal rhabdomyosarcoma arising from the gluteal muscles at birth. Ultrasonography and Magnetic resonance imaging raised the possibility of hemangioma lymphangioma. Total excision was done and chemotherapy given. The child had a recurrence after 6 months where the nodule along with the scar was excised. A chemoport was introduced and the child underwent further 4 cycles of chemotherapy after recurrence. He is well on 2 years follow up without any disability.

Key words: *Embryonal rhabdomyosarcoma, Newborn, Gluteal region*

Rhabdomyosarcoma (RMS) is a soft tissue tumor originating from immature mesenchymal cells, and account for about one-half of soft tissue sarcomas in children, but is very rare in neonates and little is known about it in this age group [1-6]. Embryonal RMS belongs to the class of small round blue cell tumors. The Embryonal RMS make up about 60-70% of RMS cases [6,7]. RMS may be present at birth, 1-2% of all cases are congenital with intrauterine origin [8]; neonatal tumors can be diagnosed at birth or in the first 28 days. There is no racial predilection; the tumor is slightly more common in boys.

Although, it may arise anywhere in the body; it has a predilection for the head and neck area, genitourinary tract and the extremities [7]. Approximately, one half and three-fourths of the sarcomas of the extremities are alveolar [6,8] and occur more commonly in the leg. Gluteal region is a rare site for RMS. We report a neonate with embryonal RMS in the gluteal region at birth.

CASE REPORT

A newborn male baby was born to gravida II, 25-year-old healthy mother at 40 weeks gestation by

Lower Segment Caesarean Section. The baby was found to have a 3X3cms mass in the left gluteal region at birth. The mass was firm, spherical, fixed to the underlying muscles and non tender, measuring 3x3 centimeters. Overlying skin was adherent to the mass. At birth, after all preliminary investigations it was decided to wait and watch as the ultrasonography and Magnetic resonance imaging (MRI) had reported it to be a hemangioma lymphangioma complex involving subcutaneous muscular plane of the gluteal region [Fig.1]. Due to jaundice and intercurrent problems the baby was closely followed.

After three weeks of observation, the mass suddenly started increasing in size [Fig.2] and a suspicion of malignant teratoma was thought off and tumor markers e.g. AFP and Beta-HCG were sent, which were within normal limits. The mass appeared very vascular with a high flow on Doppler. With all preparedness, child was taken up for excision of the mass. At 28 days of life, total excision of the well encapsulated mass measuring 6X6X5cms was performed [Fig.3]; though, it was adherent posteriorly to the gluteus major. Frozen section analysis showed malignant small round cell tumor. Wound was closed primarily. Specimen was

sent for HPE and Immuno-histochemical studies which came out to be positive for vimentin, desmin and myogenin and a diagnosis of Embryonal Rhabdomyosarcoma was made [Fig.4].

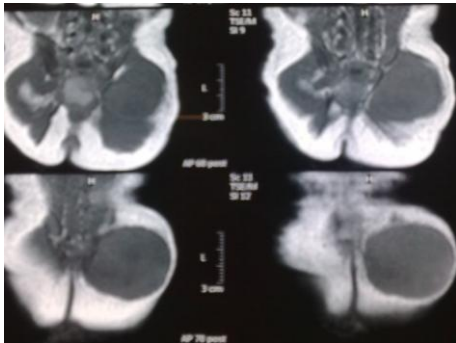


Figure 1 - MRI showing mass involving subcutaneous and muscular plane of left gluteal region

childhood malignancies [7]. The median age at the time of diagnosis is five years and almost two third of the patients are diagnosed before the age of 10 years [9].

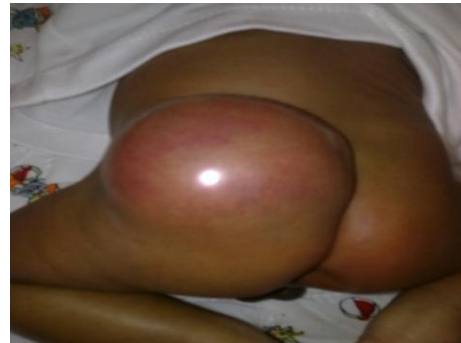

Figure 2 - Left gluteal mass 6 X 6 X 5 cm just before surgery

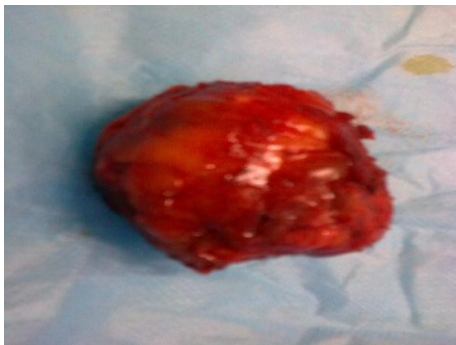

Figure 3 - Excised specimen

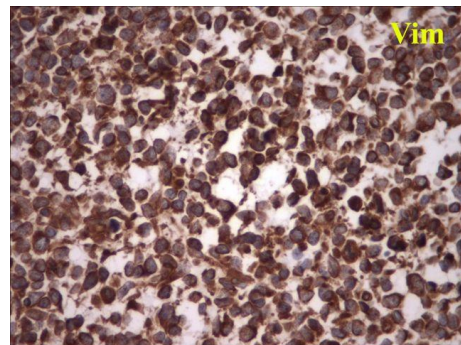


Figure 4 - Immunohistochemistry showing positive vimentin

The wound healed primarily, without any complications. Patient was seen by pediatric oncologist and 3 cycles of Vincristine, cyclophosphamide and 1 dose of actinomycin-D were given at monthly intervals. At 3 months post-operative period child was well with no recurrence clinically and imaging wise. After 6 months a nodule was found at the wound scar and a further wide local excision was done. Biopsy reconfirmed the lesion to be a recurrent rhabdomyosarcoma. A chemoport was inserted and further 4 cycles of chemotherapy was given. Now the child is recurrence free for the last 2 years.

DISCUSSION

Rhabdomyosarcoma (RMS), a malignant tumor of immature mesenchymal cell origin, is the most common soft tissue sarcoma in the pediatric age group, accounting for approximately 3-5% of all

RMS is traditionally subdivided into embryonal, alveolar and pleomorphic. Pleomorphic RMS, in contrast to embryonal and alveolar RMS, almost exclusively occurs in adults (median age sixth decade). Alveolar RMS represents about 20% of all RMS [10]. Embryonal RMS is the most common type (60-70% of all RMS) [11], and is the most predominant in neonates, infants and young children [12].

However, occurrence of RMS in the neonatal period is extremely rare and only 1-2% of all cases are congenital [9,13]. There are only a few reports about neonatal RMS in the literature [4,11]. Of 3,217 patients registered in the Intergroup Rhabdomyosarcoma Study (IRS) I-IV, only 14 were in the neonatal period at the time of diagnosis [14]. In a report from the Italian Cooperative Group, among 50 infants with RMS over 20 years, 15 were considered as having congenital RMS [13].

Rodriguez et al reported only four patients with neonatal RMS treated during 37 years (1962-1999) of study period [3]. Thus, knowledge about RMS in this age group is sparse [4].

In congenital RMS, the disease may be metastatic at the time of birth with metastases in a number of organs and in the placenta too [15]. Age of the patient, location of the tumor, histopathologic features and metastatic status are the important prognostic factors for RMS [16]. Treatment of neonatal RMS requires a multidisciplinary approach involving paediatric oncologists, radiologists, paediatric surgeons and pathologists [12]. Surgery and chemotherapy is the mainstay of the management of these cases and both have their own specific role. Complete resection of rhabdomyosarcoma is recommended. Embryonal RMS generally responds very well to chemotherapy. However, a prolonged follow-up is necessary to evaluate the outcome of treatment. Good response to chemotherapy allows surgery to be done less aggressively if needed. The use of radiotherapy is restricted by very high risk of side effects and it should be avoided in newborns [7].

CONCLUSION

In a newborn presenting with a gluteal mass, RMS should be considered as one of the differential diagnosis as by early and appropriate institution of chemotherapy and surgery, these respond well.

ACKNOWLEDGEMENT

We thank Dr K Sridhar, Plastic Surgeon; Dr N Sekar, Vascular Surgeon; Dr K Raghavendran, Anaesthesiologist; Dr Asok Parameswaran, Pathologist; and Dr T Raja, Oncologist in managing this baby.

REFERENCES

- Loh M, Matthay K. Neoplasia. In: Tausch GW, Ballard RA, Gleason CA (eds). Avery's Disease of the Newborn. 8th ed. Philadelphia; Elsevier Saunders. 2005: p. 1460-61.
- Luchtman L, Jones A, Schwartz A, et al. The blood and haematopoietic system (2002) In: Fonaroff AA, Martin RJ (eds). Diseases of the Fetus and Infant. 7th ed. Philadelphia; Mosby. 2002: p. 236-37.
- Rodriguez-Gallindo C, Hill DA, Onyekwere O, Pin N, Rao BN, Hoffer FA, et al. Neonatal alveolar rhabdomyosarcoma with skin and brain metastases. Cancer. 2001;92(6):1613-20.
- Buyukpamukcu M, Varan A, Tanyel C, Senocak ME, Gogus S, Akyuz C, et al. Solid tumors in neonatal period. Clin Pediatr (Phila). 2003;42(1):29-34.
- Chigurupati R, Alfatooni A, Myall RW, Hawkins D, Oda D. Rhabdomyosarcoma in neonates and young children. Oral Oncol. 2002;38(5):508-15.
- Wexler L, Crist W, Helman L. Rhabdomyosarcoma and the undifferentiated sarcomas. In: Pizzo PA, Poplack DG (eds). Principles and Practice of Pediatric Oncology. 4th ed. Philadelphia; Lippincot Williams & Wilkins. 2002: p. 939-63.
- Singh O, Gupta SS, Upadhyaya V, Sharma SS, Lahoti BK, Mathur KR. Rhabdomyosarcoma of the posterior chest wall in a newborn: a case report. Cases J. 2009;2:6818
- Barksdale E, Wiener E. Rhabdomyosarcoma. In: Ashcraft KW, Murphy JP, Sharp RJ, et al. Paediatric Surgery. 3rd ed. Philadelphia; Saunders. 2000; p. 942-53.
- Perin C, Lacour JP, Thyss A, Michiels JF, Rostain G, Valla J, et al. Subcutaneous rhabdomyosarcoma in children; Clinical, Immunologic and ultrastructural aspects. Ann Dermatol Venereol. 1988;115:919-25.
- Van Rijn R, Wilde J, Bras J, Merks J. Imaging findings in non-craniofacial childhood rhabdomyosarcoma. Pediatr Radiol. 2008;38:617-34.
- Isaacs H Jr: Congenital and neonatal malignant tumors. A 28-year experience at Children's Hospital of Los Angeles. Am J Pediatr Hematol Oncol. 1987;9:121-9.
- Parkes SE, Muir KR, Southern L, Cameron AH, Darbyshire PJ, Stevens MC. Neonatal tumours: a thirty year population-based study. Med Pediatr Oncol. 1994;22:309-17.
- Ferrari A, Casanova M, Bisogno G, Zanetti I, Cecchetto G, De Bernardi B, et al. Rhabdomyosarcoma in infants younger than one year old; a report from the Italian Cooperative Group. Cancer. 2003;97(10):2597-2604.
- Lobe TE, Wiener ES, Hays DM, Lawrence WH, Andrassy RJ, Johnston J, et al. Neonatal rhabdomyosarcoma: the IRS experience. J Pediatr Surg. 1994;29(8):1167-70.
- White FV, Dehner LP, Belchis DA, Conard K, Davis MM, Stocker T, et al. Congenital disseminated malignant rhabdoid tumor: a distinct clinicopathologic entity demonstrating abnormalities of chromosome 22q11. Am J Surg Pathol. 1999;23(3):249-56.
- Güra A, Tezcan G, Karagüzel G, Çevikol C, Oygür N. An unusual localization of embryonal rhabdomyosarcoma in a neonate. Turk J Pediatr. 2007;49(1):82-84.

Funding: None; Conflict of Interest: None Stated

How to cite this article: Agarwal P, Bagdi RK, Raghupathi V. Gluteal rhabdomyosarcoma in a newborn – A case report. Indian J Child Health. 2014;1(1):12-14.

Doi: [10.32677/IJCH.2014.v01.i01.003](https://doi.org/10.32677/IJCH.2014.v01.i01.003)