

Case Report

Incidental finding of cleidocranial dysplasia in an adolescent with head trauma

Gurpreet Singh Sandhu, B N Lakhkar, H R Nagrale

From Department of Radio Diagnosis, AVBRH, Jawaharlal Nehru Medical College, Sawangi, Wardha, Maharashtra, India

Correspondence to: Dr. Gurpreet Singh Sandhu, Department of Radio Diagnosis, AVBRH, Jawaharlal Nehru Medical College, Sawangi, Wardha, Maharashtra, India. E-mail: gurpreetsandhu1529@gmail.com

Received – 14 July 2014

Initial Review – 5 August 2014

Published Online – 15 September 2014

Abstract

Cleidocranial dysplasia (CCD) is a rare autosomal dominant skeletal disease. It is characterized by partial or complete absence of clavicles, late closure of fontanel, presence of open skull sutures and multiple wormian bones and various craniofacial and dental abnormalities. The majority of craniofacial abnormalities become obvious during adolescence. Early diagnosis with preventive measures for various associated complications helps improve the quality-of-life of the patient. We hereby report an incidental finding of CCD in a 16-year-old young adolescent male with blunt head trauma and review the clinical and radiological features and associated orthopedic, dental and ENT complications of this rare disorder.

Key words: *Hypoplastic clavicles, Supernumerary teeth, Trauma, Wormian bones*

Martin in 1765, described a patient with congenital absence of clavicles [1]. Pierre Marie and Paul Sinton in 1898 described cleidocranial dysplasia (CCD). Since then, over 1000 cases of CCD have been documented in the medical literature [2,3]. CCD, also known as Marie and Sinton Disease, Scheuthauer Marie–Sinton syndrome and mutational dysostosis, is a rare disease, which can occur either spontaneously or as autosomal dominant inheritance [4]. There is no predilection of gender or ethnic group. It is characterized by generalized dysplasia of osseous and dental tissue resulting in defects in the skull, clavicle and teeth. CCD occurs in approximately 1 per million individuals worldwide [5].

CASE REPORT

A 16-year-old adolescent male with headache was referred to the department of radio diagnosis for computerized tomography (CT) scan of the head for evaluation of blunt head trauma that had occurred 4 days prior. On CT scan, there was no intraparenchymal brain abnormality, however, the bone window revealed incidental findings

in the form of wormian bones along the lambdoid suture, high parietal and occipital region (Figs. 1 and 2). There were bilateral hypoplastic maxillae and hypoplastic zygomatic arch. The cranial base revealed a steep clivus (Fig. 2). The oral cavity revealed multiple unerupted permanent teeth and impacted supernumerary teeth in both the upper and lower jaws (Fig. 3). There was spina bifida noted in the cervical vertebrae.

Thus, the possibility of CCD was considered, and X-ray chest posterioranterior view was taken. It showed hypoplastic terminal ends of bilateral clavicle, narrow thorax and ribs prominent downwards. The upper thoracic spine showed the scoliosis (Fig. 4). X-rays of hands and pelvis were done that showed cone shaped distal phalanx (Fig. 5) and diastasis of the pubic symphysis.

The family history was negative. The physical examination revealed short stature with a large brachycephalic head, small and angular face, prominent frontal and parietal bones, hypertelorism and the drooping shoulders (Fig. 6) with excessive

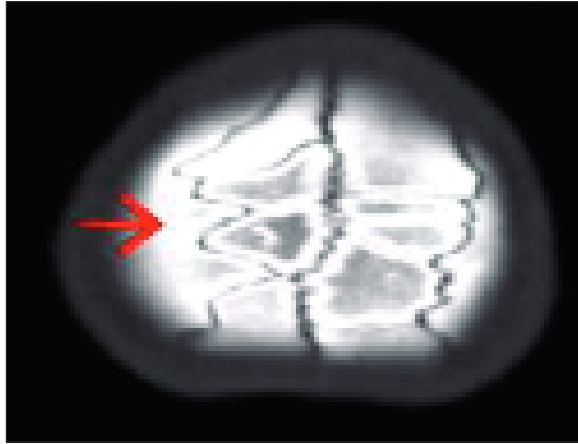


Figure 1: Computerized tomography head (bone window) axial view-showing multiple wormian bones (arrow) in bilateral high parietal region

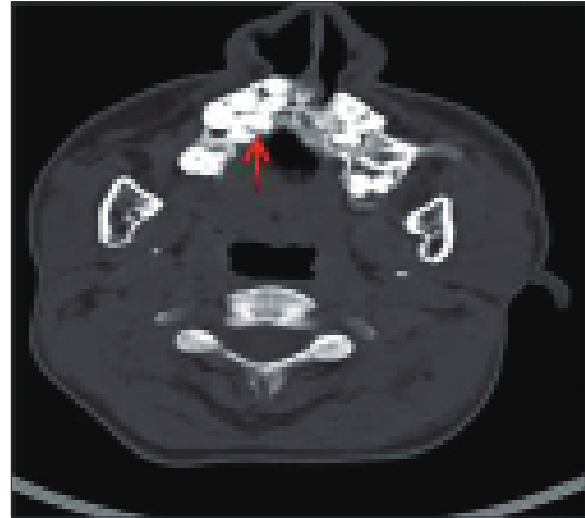


Figure 3: Computerized tomography head (bone window) axial view: Showing numerous supernumerary teeth (arrow) upper jaw

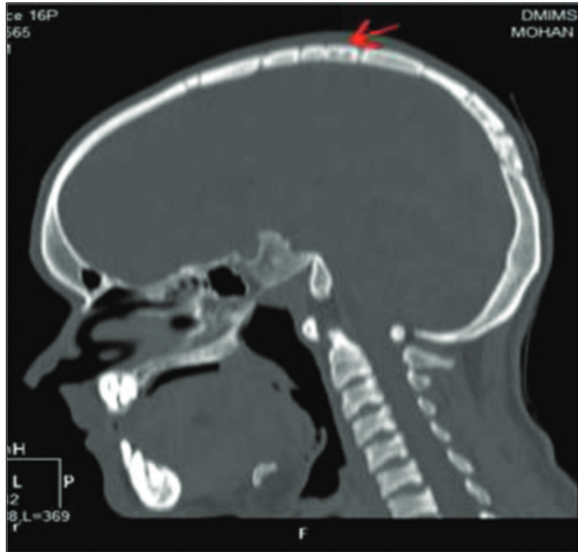


Figure 2: Computerized tomography head (bone window) saggital view-showing multiple wormian bones (arrow) in parietal and occipital region with steep clivus

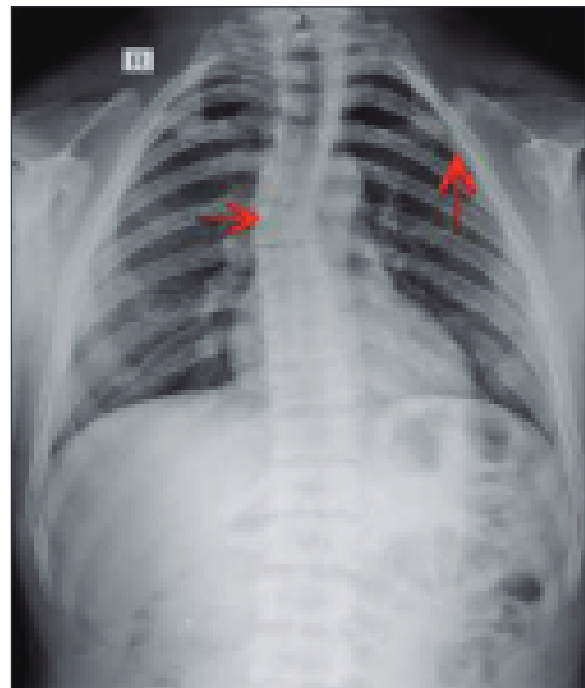


Figure 4: Chest X-ray posterioranterior view: Hypoplastic bilateral clavicles, narrow thorax with scoliosis of thoracic spine toward right side (arrows)

mobility reaching up until midline. His biochemistry revealed normal serum calcium of 9.1 mg/dL, normal serum phosphorus (3.8 mg/dL) and normal serum alkaline phosphatase (98 IU). We could not measure the vitamin D levels. Patient was advised dental and ENT checkups, but did not follow-up.

DISCUSSION

CCD is a rare congenital autosomal dominant disorder associated with a spontaneous mutation in the gene coding for osteoblast transcription factor for

RUNX2, which is essential for osteoblast and dental cell differentiation as well as for bone and tooth formation [6]. However, we could not confirm this in our patient as genetic study was not carried out due to unavailability in our institution and financial constraints.

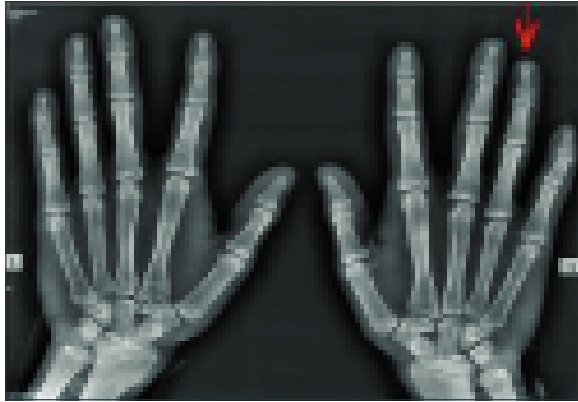


Figure 5: X-ray hand posterioranterior view: Conical shaped distal phalanx (arrow)

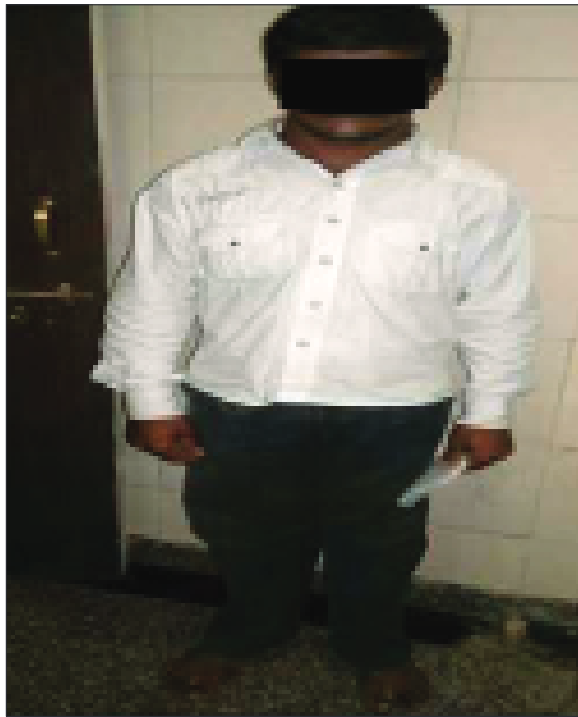

Figure 6: Patient standing with drooping shoulders

CCD may be identified by family history, excessive mobility of shoulders and radiographic pathognomonic findings of the chest, skull and jaws. As highlighted in our patient, the radiographic evaluation is the most important and reliable means to confirm the diagnosis. Pathognomonic radiological findings of CCD include the broad sutures, large fontanelles persisting into adulthood, numerous wormian bones, numerous unerupted supernumerary teeth and a partial or complete absence of clavicles [3,7,8]. The cranial base in our patient showed steep clivus, a rare

finding. We did not encounter any report of steep clivus in association with cleidocranial dysplasia.

In general, the clavicles are underdeveloped to varying degrees and are completely absent in approximately 10% of cases. This allows excessive mobility of the shoulder girdle. Thoracic cage is small, and bell-shaped with short ribs [9]. Other bones may also be affected including long bones, the vertebral column, the pelvis and the bones of hands and feet. Roentgenograms of the hands show multiple deformities which are characteristic of this condition. These include: Distal phalanges without unguis expansions and short and conical in shape; the middle phalanges much shorter than normal with concave lateral borders [6,10]. Several abnormalities in the development of the spine have been reported including kyphosis, lordosis, scoliosis, spina bifida and cervical rib. The pelvic bone abnormalities are frequent. These include narrowed pelvic canal with considerably widened joint spaces before puberty and broad pelvis with narrowed and irregular joint spaces after puberty [11].

Children under 5 years of age show mild motor delay with increased occurrence of orthopaedics related complications with age such as pes planus (flat feet) in 57%, genu valgum (knock knee deformity) in 28% with less commonly shoulder and elbow dislocation. Osteoporosis starts at early age in these patients resulting in recurrent fractures of bones and scoliosis [11]. In these patients if cranial vault defect is significant, head should be protected from blunt trauma using helmets and protective devices, especially in children and adolescents with high-risk sport activities. Evaluation by craniofacial surgeon and rehabilitation may also be required. Dental complications are common such as numerous supernumerary teeth resulting in failure of eruption of primary dentition resulting in difficulty in mastication. ENT complications of upper airways, sinusitis, ear infections and conductive hearing loss are also common [12].

Bone mineral density should be assessed using dual energy X-ray absorptiometry scan to detect osteoporosis and preventive measures such as calcium and vitamin D can be given. Surgical and orthodontic measures may also be required to treat ENT and dental complications respectively [13]. The differential diagnosis of this condition includes Mandibuloacral dysplasia, Crane-Heise syndrome, pycnodysostosis,

yunis varon syndrome, CDAGS syndrome and hypophosphatasia. These disorders may share some of the clinical features with CCD; however, all of these are autosomal recessive disorders and have their specific clinical features [12,14,15].

CONCLUSION

The clinical findings of CCD, although present at birth, are often either missed or diagnosed at a much later age. As shown in this case, some cases are diagnosed incidentally. Positive family history, excessive mobility of shoulders and the pathognomonic radiological findings are useful in confirming the diagnosis of this rare disorder.

REFERENCES

1. Martin S. Sur underpacement naturel de la clavicle. *J Med Chir Pharmacol.* 1765;23:456-60.
2. Martin S, Sainton P. Sur la dysostose cleidocranienne hereditaire. *Rev Neurol.* 1898;6:835.
3. Golan I, Baumert U, Hrala BP, Müssig D. Dentomaxillofacial variability of cleidocranial dysplasia: Clinicoradiological presentation and systematic review. *Dentomaxillofac Radiol.* 2003;32(6):347-54.
4. Alves N, Oliveira R. Cleidocranial dysplasia - A case report. *Int J Morphol.* 2008;26:1065-8.
5. Garg RK, Agrawal P. Clinical spectrum of cleidocranial dysplasia: A case report. *Cases J.* 2008;1(1):377.
6. Mundlos S. Cleidocranial dysplasia: Clinical and molecular genetics. *J Med Genet.* 1999;36(3):177-82.
7. Gombhra V, Jayachander S. Cleidocranial dysplasia: Report of 4 cases and review. *J Indian Acad Oral Med*

Radiol. 2008;20:23-7.

8. Mohan RP, Suma GN, Vashishth S, Goel S. Cleidocranial dysplasia: Clinico-radiological illustration of a rare case. *J Oral Sci.* 2010;52(1):161-6.
9. Feldman VB. Cleidocranial dysplasia: A case report. *J Can Chiropr Assoc.* 2002;46:185-91.
10. Gonzalez GE, Caruso PA, Small JE, Jyung RW, Troulis MJ, Curtin HD. Craniofacial and temporal bone CT findings in cleidocranial dysplasia. *Pediatr Radiol.* 2008;38(8):892-7.
11. Gulati S, Kabra M. Cleidocranial dysplasia. *J Postgrad Med.* 2001;47(3):204-5.
12. Mendoza-Londono R, Lee B. Cleidocranial dysplasia. *Gene Rev.* 2006. Available from: <http://www.ncbi.nlm.nih.gov/books/NBK1513/>. [Last updated on 2013 Aug 29].
13. Cooper SC, Flaitz CM, Johnston DA, Lee B, Hecht JT. A natural history of cleidocranial dysplasia. *Am J Med Genet.* 2001;104(1):1-6.
14. El-Gharbawy AH, Peeden JN Jr, Lachman RS, Graham JM Jr, Moore SR, Rimoin DL. Severe cleidocranial dysplasia and hypophosphatasia in a child with microdeletion of the C-terminal region of RUNX2. *Am J Med Genet A.* 2010;152A(1):169-74.
15. Bhargava P, Khan S, Sharma R, Bhargava S. Cleidocranial dysplasia with autosomal dominant inheritance pattern. *Ann Med Health Sci Res.* 2014;4 (Suppl S2):152-4.

Funding: None; Conflict of Interest: None Stated

How to cite this article: Sandhu GS, Lakhkar BN, Nagrale HR. Incidental finding of cleidocranial dysplasia in an adolescent with head trauma. *Indian J Child Health.* 2014;1(2):91-4.

Dol: 10.32677/IJCH.2014.v01.i02.014