

## An unusual case of pancytopenia in an adolescent girl

N R Mishra, P C Panda, S Das, M Arun

From Department of Pediatrics, VSS Medical College & Hospital, Burla, Sambalpur, Odisha, India

**Correspondence to:** Nihar Ranjan Mishra, Department of Pediatrics, VSS Medical College & Hospital, Burla, Sambalpur, Odisha, India. Phone: +91-9337797072, E-mail: drnihar.mishra@gmail.com

Received – 29 October 2014

Initial Review – 19 November 2014

Published Online – 02 February 2015

### Abstract

Patients with disseminated tuberculosis (TB) have varied presentations like pyrexia of unknown origin, hepatosplenomegaly, lymphadenopathy and meningitis, but pancytopenia is rare. Sometimes the cause of pancytopenia is not discernible after initial investigations. Such cases need further evaluation to know the etiology of pancytopenia for appropriate management of the patient. The present case was misdiagnosed as nutritional anaemia, which after thorough workup was diagnosed as disseminated TB. We are reporting this case in view of extreme rarity of TB presenting with pancytopenia.

**Key words:** *Anti-tubercular drugs, Acid fast bacillus, Disseminated tuberculosis, Montoux test, Pancytopenia, Tuberculosis-polymerase chain reaction*

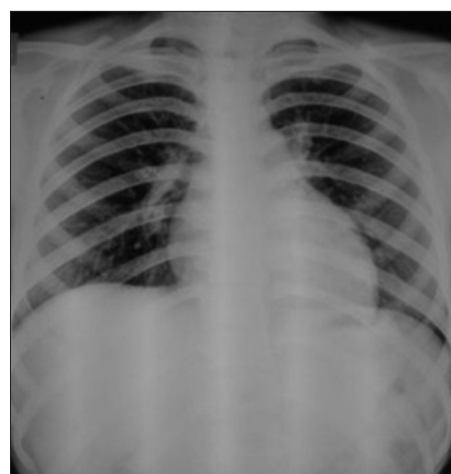
Wide varieties of hematological abnormalities have been described in association with pulmonary tuberculosis (TB) such as anemia, monocytosis, leukopenia and leukocytosis [1]. These are more commonly seen in patients of disseminated TB [2-4]; however major hematologic changes like the pancytopenia are rare. It has been more consistently documented in patients with miliary TB [5] and suggests the possibility of granulomatous infiltration of bone marrow, hypersplenism, proliferative disorder of reticulo-endothelial system, or some unrelated disease process.

### CASE REPORT

A 14-year-old girl presented in Outpatient Department with the complaints of low grade continuous fever of 3 weeks associated with non-productive cough and gradual onset of pallor for 1 week. There was no significant past history including bleeding from any site, rash and exposure to toxins or chemicals, but history of contact with TB in the family was present. Patient was not immunized except oral poilo and bacillus Calmette-Guérin scar mark was absent.

On examination, she was conscious, malnourished and pale. She was febrile (temperature 99.5°F), and had tachycardia. She was underweight (weight and body mass index <3rd percentile, WHO). There were three lymph nodes measuring 1-2 cm, non-tender and non-matted, palpable in the left inguinal region. There were no petechiae or ecchymosis. Both liver and spleen were 3 cm enlarged below right and left costal margins respectively. Rest of the systemic examination was within the normal limits.

Investigations revealed hemoglobin (Hb) of 4.4 g/dl, total leukocyte count (TLC) of 2350/cu mm, differential count of 12% polymorphs and 88% lymphocytes, platelet count of 36,000/cu mm and reticulocyte count of 1%. Peripheral smear examination showed pancytopenia and no abnormal cells. X-ray chest showed bilateral perihilar lymphadenopathy (Figure 1) and the Montoux test revealed an induration of 18 mm after 48 h. Thorough laboratory investigations were planned to detect the cause of thrombocytopenia. The bleeding time, clotting time, prothrombin time and partial thromboplastin time were normal, and fibrin degradation products were absent. The urine and stool examination did not show any abnormality. Urine and blood cultures did not grow any organisms. Blood Widal and venereal disease research laboratory were non-reactive, and



**Figure 1:** X-ray chest PA view showing bilateral perihilar lymphadenopathy

serum G6PD level was normal (20.21 U/g Hb, kinetic method). The direct and indirect Coomb's tests were negative, and Hb electrophoresis was normal. Serological test for hepatitis B virus/hepatitis C virus/HIV, brucellosis and dengue were negative. ANA also found negative. Ultrasound examination of the abdomen did not show any abnormality except for hepatosplenomegaly. Bone marrow aspiration yielded hypocellular marrow with myeloid to erythroid ratio of 2:1 and no atypical cells. Sputum smear examination for acid fast bacilli by ZN staining was positive for *Mycobacterium* TB. Polymerase chain reaction (PCR) (Mycosure, real time PCR) for *Mycobacterium* TB complex was detected in the blood sample.

After ruling out the other causes of thrombocytopenia, diagnosis of disseminated TB was made and antitubercular treatment was started according to category I extrapulmonary TB regimen (isoniazid, rifampicin, pyrazinamide and ethambutol for 2-months, followed by isoniazid and rifampicin for another 10 months). She had received two units of packed cell with in first 2 days of hospitalisation. Peripheral blood examinations revealed pancytopenia for next 3 weeks. After 3 weeks of therapy, Hb, TLC and platelets increased to 9.3 g/dl, 8600/mm<sup>3</sup> and 212,000/mm<sup>3</sup> respectively and reticulocyte count to 4.2%. Size of the liver and spleen was reduced almost by 50% after completion of initial 2 months of therapy. The child was doing well after 3 months of treatment but lost to follow up there after.

## DISCUSSION

Pancytopenia with hypocellular bone marrow has been described occasionally in cases of TB. The hematologic alterations described in patients with miliary or disseminated TB include anemia, granulocytosis, leukopenia, leukocytosis, thrombocytosis and monocytosis [2-6]. Pancytopenia as the presenting feature of disseminated TB is extremely rare both in children [7,8] and adults [2]. The occurrence of pancytopenia in disseminated TB is attributed to hypersplenism [9], histiocytic hyperplasia and indiscriminate phagocytosis of blood cells by histiocytes in bone marrow [10], maturational arrest [7,8] or infiltration of the bone marrow by caseating or non-caseating tubercular granulomas [4,6,11-14]. Tubercular granulomas may cause pancytopenia by replacement of marrow cells or suppression through release of interferon and lymphotoxin [14,15].

In our case, the diagnosis of disseminated TB was established on the basis of contact history, clinical features (hepatosplenomegaly), positive Mantoux test and sputum smear examinations, hilar adenopathy and positive PCR. The other causes of pancytopenia including leukemia, exposure to drugs, chemicals, radiation, aplastic anemia, and immune cytopenias were excluded on clinical and laboratory evaluation. In addition, the peripheral blood picture became normal following anti-tubercular therapy supporting the diagnosis of TB induced

reversible pancytopenia. Most of the patients with caseating granulomas in the bone marrow died [12-14], whereas those with non-caseating granulomas survived [11,14]. But, in our case no granulomas were detected in bone marrow. The precise reason for the variable outcome is not clear but may be attributed to the virulence of the bacteria, immunity of the host and delay in initiation of appropriate treatment.

## CONCLUSION

This case was presented due to the relative rarity of presentation and physicians should be aware of atypical presentation of TB as thrombocytopenia.

## CONTRIBUTORS

NRM (guarantor) and PCP were responsible for case diagnosis, preparation of case report, manuscript review and approval.

## REFERENCES

1. Glasser RM, Walker RI, Herion JC. The significance of hematologic abnormalities in patients with tuberculosis. *Arch Intern Med.* 1970;125(4):691-5.
2. Maartens G, Willcox PA, Benatar SR. Miliary tuberculosis: rapid diagnosis, hematologic abnormalities, and outcome in 109 treated adults. *Am J Med.* 1990;89(3):291-6.
3. Schuit KE. Miliary tuberculosis in children. Clinical and laboratory manifestation in 19 patients. *Am J Dis Child.* 1979;133(6):583-5.
4. Prout S, Benatar SR. Disseminated tuberculosis. A study of 62 cases. *S Afr Med J.* 1980;58(21):835-42.
5. Cooper W. Pancytopenia associated with disseminated tuberculosis. *Ann Intern Med.* 1959;50(6):1497-501.
6. Hussey G, Chisholm T, Kibel M. Miliary tuberculosis in children: a review of 94 cases. *Pediatr Infect Dis J.* 1991;10(21):832-6.
7. Chandra J, Marwaha RK, Marwaha N, Kumar A, Mothanty D. Pancytopenia and leukemoid reactions in tuberculosis. *Indian J Pediatr.* 1986;53(5):665-7.
8. Kashyap S, Puri DS, Bansal SK, Dhawan A, Prasher N, Grover PS. *Mycobacterium tuberculosis* infection presenting as pancytopenia with hypocellular bone marrow. *J Assoc Physicians India.* 1991;39(6):497-8.
9. Meredith HC Jr, Early JQ, Becker W. Tuberculous splenomegaly with the hypersplenism syndrome; a case report. *Blood.* 1949;4(11):1367-73.
10. Weintraub M, Siegman-Igra Y, Josiphov J, Rahmani R, Liron M. Histiocytic hemophagocytosis in miliary tuberculosis. *Arch Intern Med.* 1984;144(10):2055-6.
11. Rosenberg MJ, Rumans LW. Survival of a patient with pancytopenia and disseminated coagulation associated with miliary tuberculosis. *Chest.* 1978;73(4):536-9.
12. Knobel B, Sommer I, Saidel L, Robson M. Pancytopenia – a rare complication of miliary tuberculosis. *Isr J Med Sci.* 1983;19(6):555-8.
13. Rutovitz JJ. Miliary tuberculosis causing pancytopenia. A report of 2 cases. *S Afr Med J.* 1986;69(7):451-2.
14. Bagby GC Jr, Gilbert DN. Suppression of granulopoiesis by

T-lymphocytes in two patients with disseminated mycobacterial infection. *Ann Intern Med.* 1981;94:478-81.

15. Murphy M, Loudon R, Kobayashi M, Trinchieri G. Gamma interferon and lymphotoxin, released by activated T cells, synergize to inhibit granulocyte/monocyte colony formation. *J Exp Med.* 1986;164(1):263-79.

*Funding: None; Conflict of Interest: None Stated*

**How to cite this article:** Mishra NR, Panda PC, Das S, Arun M. An unusual case of pancytopenia in an adolescent girl. *Indian J Child Health.* 2015;2(1):34-6.