

Cysticercal encephalitis with disseminated cutaneous cysticercosis: A case report

Parul Verma, Nishant Verma

From ¹Department of Dermatology, Vivekanand Polyclinic and Institute of Medical Sciences, ²Department of Pediatrics, King George's Medical University, Lucknow, Uttar Pradesh, India

Correspondence to: Nishant Verma, Department of Pediatrics, King George's Medical University, Shahmina Road, Lucknow - 226 003, Uttar Pradesh, India. Phone: +91-8765806252, E-mail: drnishantaiims@gmail.com

Received – 16 January 2015

Initial Review – 16 February 2015

Published Online – 06 March 2015

Abstract

Cysticercal encephalitis is a severe and frequently fatal neurological disorder seen in endemic regions. We report a young male who presented with refractory status epilepticus along with numerous subcutaneous swellings over the body. His neuroimaging revealed the classic “starry sky” appearance, suggesting a diagnosis of cysticercal encephalitis along with disseminated cutaneous cysticercosis. He was managed with supportive care, antiepileptics and steroids. In endemic regions, neurocysticercosis should be considered as a differential diagnosis in children presenting as acute encephalitis syndrome. A careful physical examination along with early neuroimaging will help in establishing the diagnosis promptly.

Key words: *Cutaneous, Disseminated, Encephalitis, Neurocysticercosis*

Cysticercosis is a parasitic disease caused by infestation with the larval stage of the pork tapeworm, *Taenia solium*. Neurocysticercosis (NCC), i.e. cysticercal infection of the central nervous system (CNS) is among the commonest cause of seizures in the developing world. Disseminated cysticercosis is an exceptional expression of this disease characterized by high morbidity due to massive symptomatic parasite burden in the CNS, subcutaneous tissues, and other organs. We report an extremely rare presentation of cysticercosis, i.e., cysticercal encephalitis along with disseminated cutaneous cysticerci in a young Indian boy.

CASE REPORT

An 8-year-old boy presented to the pediatric emergency room with the history of multiple episodes of generalized tonic-clonic seizures for 1 day. At the time of admission, the child was in status epilepticus. Oxygen was administered, and an intravenous line was secured, intravenous diazepam was administered immediately, followed by a loading dose of phenytoin (20 mg/kg). As the seizures continued to persist, blood samples for serum electrolytes and sugar were sent, which were reported as normal. In view of the refractory status epilepticus, intravenous valproate (20 mg/kg), followed by levetiracetam (20 mg/kg) were used, and the seizures were terminated.

On enquiring from the mother, the child was developing normally and is in class III in school, with no past or family history of seizures. He was asymptomatic till 7 days back,

when his mother noticed multiple pea-sized swellings over his abdomen. The swellings continued to increase in number over the past 7 days, and at the time of presentation, numerous pea-sized, non-tender, mobile, non-fluctuant and soft swellings were noted over the abdomen, chest and neck (Fig. 1).

Even after the control of status epilepticus, the child continued to show altered sensorium with Glasgow coma scale of 5 (E1V1M3). A contrast enhanced computerized tomography (CT) scan of the head was obtained. CT revealed multiple small, contrast enhancing lesions involving entire brain parenchyma forming the characteristic ‘starry-sky’ appearance seen in NCC (Fig. 2). A fundus examination was also done, which revealed papilledema in both the eyes, no cysts were visualized. In view of the classical neuroimaging and clinical findings, a diagnosis of cysticercal encephalitis with disseminated cutaneous cysticercosis was made.

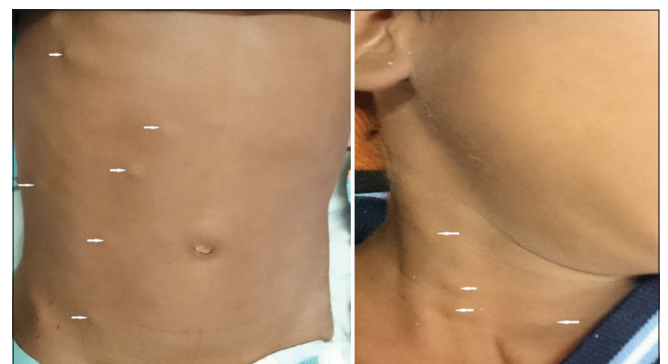

Figure 1: Multiple cutaneous nodules over abdomen and neck of cutaneous cysticercosis (white arrows)

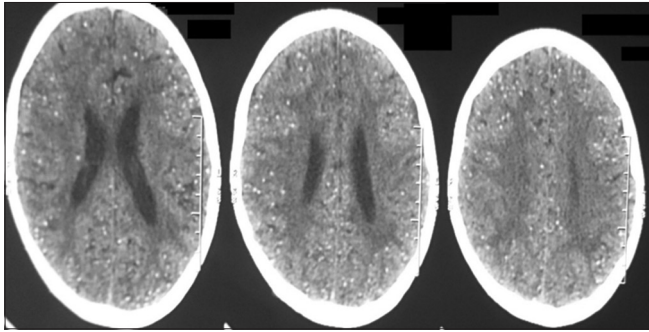


Figure 2: Computerized tomography brain showing “starry sky” appearance due to multiple calcified neurocysticerci involving the entire brain parenchyma

The child was continued on maintenance doses of antiepileptics and intravenous dexamethasone and 20% mannitol were added. Over the next 5 days, the child’s sensorium gradually improved to a Glasgow coma score (GCS) of 11 (E4V2M5). He had 2-3 episodes of focal seizures per day, for which anti-epileptic medications were optimized. Nasogastric feeding, physiotherapy, and stimulation therapy were commenced. The child was discharged on day 10 of hospitalization; he was seizure free at the time of discharge with GCS of 13 (E4V3M6). He was on full nasogastric feeds and was receiving oral prednisolone 2 mg/kg/day (planned to be tapered in follow-up).

DISCUSSION

NCC is the most common cause of acquired epilepsy in developing countries [1]. The spectrum of NCC ranges from an asymptomatic solitary parenchymal lesion to the most severe form i.e., cysticercal encephalitis. This variation in presentation depends on the location, number and stage of cysts in the nervous system, and the host immune response [1]. Children with immune deficiencies tend to have an atypical presentation of NCC and may have a more virulent disease course [2]. Cysticercal encephalitis is an extremely rare form of NCC where hundreds of small intra-parenchymal cysts are inflamed causing severe intracranial hypertension [3]. The index case also presented with features of intracranial hypertension in the form of altered sensorium and bilateral papilledema.

The management of children with cysticercal encephalitis is largely supportive. Corticosteroids are the cornerstone in the management of this condition. Dexamethasone is the preferred preparation, and it acts by reducing the cerebral edema caused due to death of the parasite in the brain parenchyma [4]. Mannitol, at doses of 1-2 g/kg/day, may also be used for acute intracranial hypertension secondary to NCC [4]. Although antiparasitic agents, either albendazole (15 mg/kg/d orally for 8-15 days) or praziquantel (50 to 75 mg/kg/d orally for 15 days) are effective in killing live cysticerci their role in management of cysticercal encephalitis is controversial. The destruction of numerous live parasites exposes antigens throughout the

brain parenchyma and triggers an intense local inflammatory reaction, which exacerbates symptoms and can be lethal because of a sudden increase in intracranial pressure [5]. Even the latest American Academy of Neurology evidence-based guidelines for the treatment of parenchymal NCC which advocates albendazole plus steroids to reduce the number of active cysticercal lesions and the long-term seizure frequency mentions that, all the studies on which this evidence is based excluded patients with massive cerebral edema or innumerable lesions [6]. In view of these potential risks, we decided not to administer antihelminthics in the index case.

In cases with disseminated cysticercosis, specially seen in endemic regions or in travelers visiting endemic regions [7], apart from the brain parenchyma, the cysticercal larva may get lodged in various other body sites like striated muscles, extraocular muscles, subcutaneous tissues, spinal cord, eyes, tongue, heart, lungs and liver [8-10]. Depending on the location of the cyst, cyst burden, and the host reaction, disseminated cysticercosis has the potential to cause severe clinical manifestations. Subcutaneous cysticercosis is usually asymptomatic, but may manifest as palpable nodules, as in our patient who had pea-sized nodules over the trunk and chest.

The present case highlights that, despite the progression in the health sector, extensive forms of cysticercosis are still prevalent in endemic regions. In children presenting with features of acute encephalitis syndrome in these regions, a possibility of cysticercal encephalitis should be considered. The importance of careful, complete physical examination also cannot be overemphasized as illustrated in the present case, wherein the subcutaneous cysticercosis provided a clue to the diagnosis.

REFERENCES

1. Singhi P. Neurocysticercosis. *Ther Adv Neurol Disord*. 2011;4(2):67-81.
2. Serpa JA, Moran A, Goodman JC, Giordano TP, White AC Jr. Neurocysticercosis in the HIV era: A case report and review of the literature. *Am J Trop Med Hyg*. 2007;77(1):113-7.
3. Rangel R, Torres B, Del Bruto O, Sotelo J. Cysticercotic encephalitis: A severe form in young females. *Am J Trop Med Hyg*. 1987;36(2):387-92.
4. García HH, Evans CA, Nash TE, Takayanagui OM, White AC Jr, Botero D, et al. Current consensus guidelines for treatment of neurocysticercosis. *Clin Microbiol Rev*. 2002;15(4):747-56.
5. Garcia HH, Gonzalez AE, Gilman RH. Cysticercosis of the central nervous system: How should it be managed? *Curr Opin Infect Dis*. 2011;24(5):423-7.
6. Baird RA, Wiebe S, Zunt JR, Halperin JJ, Gronseth G, Roos KL. Evidence-based guideline: Treatment of parenchymal neurocysticercosis: Report of the Guideline Development Subcommittee of the American Academy of Neurology. *Neurology*. 2013;80(15):1424-9.
7. Kobayashi K, Nakamura-Uchiyama F, Nishiguchi T, Isoda K,

- Kokubo Y, Ando K, et al. Rare case of disseminated cysticercosis and taeniasis in a Japanese traveler after returning from India. *Am J Trop Med Hyg.* 2013;89(1):58-62.
8. Verma R, Sharma P, Khurana N. Thousands of lesions in disseminated cysticercosis. *Am J Trop Med Hyg.* 2011;85(4):583.
 9. Kumar A, Goenka AH, Choudhary A, Sahu JK, Gulati S. Disseminated cysticercosis in a child: Whole-body MR diagnosis with the use of parallel imaging. *Pediatr Radiol.* 2010;40(2):223-7.
 10. Khandpur S, Kothiwala SK, Basnet B, Nangia R, Venkatesh HA,

Sharma R. Extensive disseminated cysticercosis. *Indian J Dermatol Venereol Leprol.* 2014;80(2):137-40.

Funding: None; Conflict of Interest: None Stated

How to cite this article: Verma P, Verma N. Cysticercal encephalitis with disseminated cutaneous cysticercosis: A case report. *Indian J Child Health.* 2015;2(1):21-3.