

A rare case of hemophilia with Ewing's sarcoma - A case report

Urmila KV, Sanad Saifu

From Department of Paediatrics, Kerala University of Health Sciences, Pariyaram, Kannur, Kerala, India

Correspondence to: Dr. Urmila KV, Department of Paediatrics, Pariyaram medical college, Pariyaram, Kannur, Kerala, India.

E-mail: drurmilakv@gmail.com

Received – 19 March 2017

Initial Review – 17 April 2017

Published Online – 02 August 2017

ABSTRACT

Malignancies are rare in children with inherited coagulation disorders like hemophilia except for non-Hodgkin's lymphoma and liver malignancies in hepatitis C positive hemophiliacs. Ewing sarcoma of bone is the second most common primary malignant bone cancer in children and adolescents; particularly, the extra skeletal variety. There is limited data available in the literature reporting hemophilia with Ewing's sarcoma. The authors report a case of 16-year-old boy with hemophilia A, who was diagnosed to have pelvic Ewing's sarcoma, which is a rare occurrence. This case could have been mistaken for hemophilic pseudotumor because of the non-specific clinical presentation. Magnetic resonance imaging and open biopsy helped to arrive at a diagnosis. The patient is now being treated with chemotherapy and radiotherapy.

Key words: Ewing's sarcoma, Hemophilia, Pseudotumor, Radiotherapy

Hemophilia A (factor VIII deficiency) and hemophilia B (factor IX deficiency) are the most common and serious congenital coagulation factor deficiencies. The clinical presentation ranges from spontaneous bleeding into the skin to serious complications like intracranial hemorrhages. Trauma precipitates bleeding in most of the cases, and once a target joint is formed, recurrent bleeding becomes very common with chance of pseudotumor formation, which occurs in 2% of the hemophiliacs [1]. These can cause compressive symptoms as well. Hemophilic pseudotumor is a progressive cystic swelling of the muscle or bone. They mostly develop in muscles of lower extremities or pelvis owing to the abundant blood supply or in the bone following intraosseous bleed.

The incidence of hemophilic pseudotumor does not significantly differ among patients with mild, moderate, or severe hemophilia [2]. The issue of malignancies in patients with hemophilia is particularly intriguing because of a presumed protective effect of this hereditary bleeding disorder against cancer spread and dissemination [3]. Because of the rarity of the malignancy and more likelihood of pseudotumors, malignancies especially soft tissue sarcomas may be misdiagnosed as pseudotumors. However, apart from anecdotal case reports of soft tissue sarcomas mistaken for pseudotumors [4], there is very little information available in literature on the epidemiology, clinical presentation and treatment options of this combination of conditions.

CASE REPORT

A 16-year-old adolescent boy from North Kerala with severe hemophilia A (F VIII <1%) presented with a 2-week history of

pain and paraesthesia over the left gluteal region. No history of trauma or recent fever. There was a history of similar complaints 2 months back for which he was hospitalized and treated with factor VIII transfusions and was symptomatically better. Child had urinary retention for the past 2 days which was not responding to conservative management.

On examination, child was conscious, oriented, but was in distress and pain. There was a vague mass 5 × 3 cm in the back near the sacrum which was tender on palpation and a distended bladder was also present. His higher mental functions, cranial nerves examination and motor system examination was within normal limits except for Grade 4 power in the knee flexors and mild limitation of movement of left lower limb which was attributed to pain. Sensory system examination revealed decreased sensation over saddle and perineal region (left side). Joint position and vibration senses were intact. Clinically findings were consistent with pseudotumor which behaved like a space occupying lesion and caused compressive myelopathy.

On laboratory investigation, total leukocyte count was $12.1 \times 10^3/\mu\text{L}$ neutrophils-67%, lymphocyte-26%, monocyte-3.9%, hemoglobin-13 g/dl, mean corpuscular volume-78.8, mean corpuscular hemoglobin-25.8, red cell distribution width 14.3, platelet $220 \times 10^3/\mu\text{L}$, and erythrocyte sedimentation rate were 7 mm/h. Peripheral smear showed normocytic normochromic red blood cells. Blood culture showed no growth. Ultrasound scan examination revealed a large heterogeneous mass of mixed echotexture with a central area of liquefaction in the sacral region and bony irregularities. Magnetic resonance imaging (MRI) lumbosacral spine showed abnormal marrow signal of sacrum, predominantly involving S2, with presacral soft tissue component lesion showing diffusion restriction with no T1 hyperintense

areas. These suggested the possibility of a fracture, eosinophilia granuloma or Ewing's sarcoma (Fig. 1).

Bone biopsy showed small round cell neoplasm and immunohistochemistry and immunofluorescence showed leukocyte common antigen focal positive in reactive cells, which were synaptophysin positive and desman, chromogranin negative (Fig. 2). These findings were consistent with Ewing's sarcoma/primitive neuroectodermal tumor (PNET). On bone marrow biopsy, no atypical cell infiltrates, or metastasis were seen. His positron emission tomography scan revealed a metabolic left lung nodule suggesting a possible metastasis and metastasis in the contralateral lymph node. The patient was referred to an oncology center and is being treated with chemotherapy with vincristine adriamycin, cyclophosphamide, ifosfamide and etoposide protocol (Fig. 3). It includes drugs such as vincristine, adriamycin, and cyclophosphamide following radiotherapy given to the pelvic lesion (3000 rads). The patient is showing clinical improvement with reduction in the size of the swelling.

DISCUSSION

Ewing sarcoma is the second most common primary sarcoma in children and young people [5]. This bone cancer commonly occurs in the long bones, ribs, pelvis, and spine (vertebral column) [6]. Extrasosseous Ewing sarcoma is a type of bone cancer, which can rarely affect the soft tissues. A type of Ewing sarcoma differentiated as PNET can be found in either the bone or soft tissue [7]. Microscopically, Ewing's sarcoma family of tumors demonstrates small round cells that predominate in densely packed sheets. Formation of pseudo rosettes may also be seen. Combination of chemotherapy, surgery, and radiotherapy is used for the treatment. Treatment depends on a number of factors, including the size and position of the tumor [8].

Radiologically, Ewing's sarcoma presents as a central lytic tumor of the diaphyseal-metaphyseal bone. It causes extensive destruction of cortical bone, and it breaks through under the periosteal, creating an "onion skin", multi laminated appearance. "Hair-on-end" appearance created by bone forming along the periosteal vessels that run perpendicularly between the cortex and the elevated periosteal layer can also be seen [9]. Other bone tumors such as osteosarcoma, soft tissue sarcoma, and benign lesions like langerhans histiocytosis can be considered in the differential diagnosis.

Hemophilic pseudotumors are a rare but serious condition in patients with hemophilia. They present as progressive cystic swellings encapsulating a hematoma and commonly involving muscles adjacent to the bones to muscles in the proximal skeleton [10]. They usually affect the soft tissues, long bones and the pelvis. They are usually the result of multiple episodes of bleeding into bone or soft tissue spaces. Pathological fractures can be associated with it owing to bone destruction due to chronic pressure. Periosteal reaction is also seen in some; their pathology is described in accordance to hematomas in various stages of resolution and occasionally, by new hemorrhage within the areas of fibrous organization. Features of both hemophilic

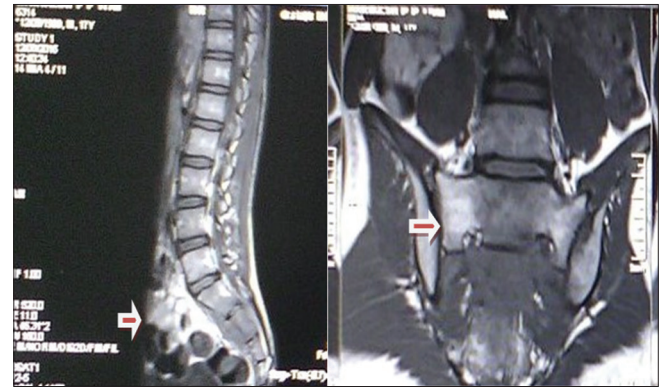

Figure 1: Abnormal marrow signal of sacrum, predominantly involving S2, with presacral soft tissue component lesion showing diffusion restriction (arrows)

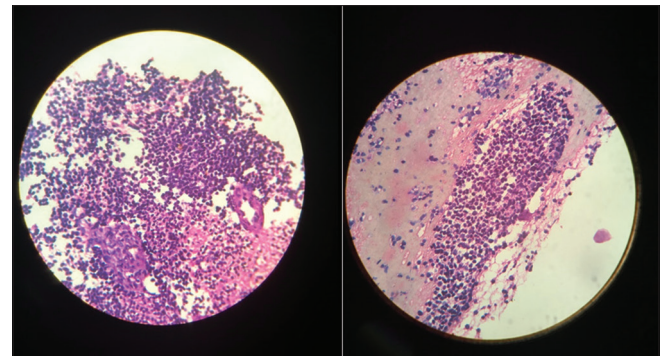


Figure 2: Bone biopsy showed small round cell neoplasm

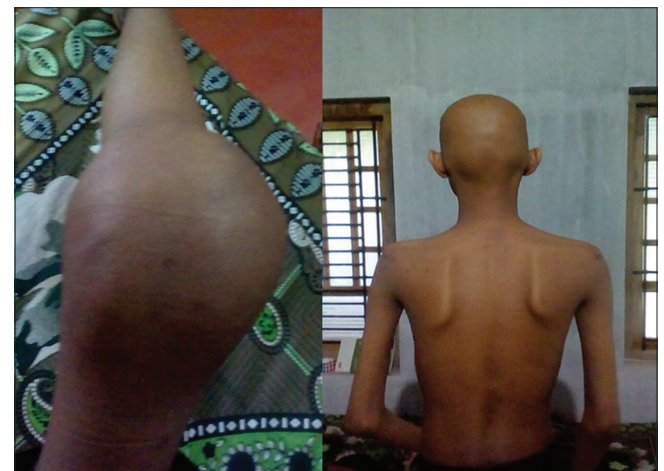

Figure 3: Clinical photograph, post chemotherapy and radiotherapy

pseudotumors and soft tissue sarcomas may be similar and difficult to differentiate. The MRI helps in coming to a final diagnosis.

Soft tissue sarcomas mimicking hematomas have been described previously. To the best of our knowledge, there are only very few reported cases of Ewing's sarcoma in hemophilia patients. There is a reported case of Ewing's sarcoma with severe hemophilia, 11 months after radioactive synovectomy. The tumor was treated successfully with surgery and chemotherapy. Radioactive synovectomy has been associated with malignancies, but in this case, it is not clear whether it is due the treatment or unrelated [11]. Diagnosis without open biopsy is extremely

difficult since techniques such as percutaneous aspiration have a low yield of tumor cells from the hematoma.

Factor VIII-von Willebrand factor (FVIII-vWF) complex, a molecule involved in coagulation, can be physically associated with osteoprotegerin (OPG). OPG, which has anti-osteoplastic activity, is a soluble receptor for the proapoptotic protein tumor necrosis factor-related apoptosis-inducing ligand. All these suggest a significant role of FVIII-vWF complex in bone and cancer biology. The effects of FVIII-vWF complex on osteoclast genesis and cell survival are complex. The direct activity of FVIII-vWF complex on osteoclasts and on induced cell apoptosis pointed out its important involvement in physiological bone remodeling or in bone damages associated with severe hemophilia and cancer development [12].

Our case was referred to an oncology center and is being treated with radiotherapy and chemotherapy, being a central location and not amenable for surgical resection, along with supportive therapy with factor VIII infusions. As a whole, the prognosis is grim because of the location, age, stage of disease, and comorbid conditions.

CONCLUSION

Even though hemophilic pseudotumor is a commonly encountered complication in patients with hemophilia, rare possibilities of malignancies also should be entertained if symptoms are out of proportion to signs. However, the absence of trauma should alert the clinician to the possibility that the abnormality may represent hemorrhage into a tumor and not a just hematoma, even in a hemophiliac.

REFERENCES

1. Sundaram M, Wolverson MK, Joist JH, Riaz MA, Rao BJ. Case report 133. Hemophilic pseudotumor of ilium and soft tissues. *Skeletal Radiol.* 1981;6(1):54-7.

2. Magallón M, Monteagudo J, Altisent C, Ibáñez A, Rodríguez-Pérez A, Riba J, et al. Hemophilic pseudotumor: Multicenter experience over a 25-year period. *Am J Hematol.* 1994;45(2):103-8.
3. Mauser-Bunschoten EP, Franssen Van De Putte DE, Schutgens RE. Co-morbidity in the ageing haemophilia patient: The down side of increased life expectancy. *Haemophilia.* 2009;15(4):853-63.
4. Okada K, Sugiyama T, Kato H, Tani T. Chronic expanding hematoma mimicking soft tissue neoplasm. *J Clin Oncol.* 2001;19(11):2971-2.
5. Craft AW, Cotterill SJ, Bullimore JA, Pearson D. Long-term results from the first UKCCSG Ewing's tumour study (ET-1). United kingdom children's cancer study group (UKCCSG) and the medical research council bone sarcoma working party. *Eur J Cancer.* 1997;33(7):1061-9.
6. Dunst J, Sauer R, Burgers JM, Hawliczek R, Kürten R, Winkelmann W, et al. Radiation therapy as local treatment in Ewing's sarcoma. Results of the cooperative Ewing's sarcoma studies CESS 81 and CESS 86. *Cancer.* 1991;67(11):2818-25.
7. Göbel V, Jürgens H, Etspüler G, Kemperdick H, Jungblut RM, Stienen U, et al. Prognostic significance of tumor volume in localized Ewing's sarcoma of bone in children and adolescents. *J Cancer Res Clin Oncol.* 1987;113(2):187-91.
8. Iwamoto Y. Diagnosis and treatment of Ewing's sarcoma. *Jpn J Clin Oncol.* 2007;37(2):79-89.
9. Ogose A, Hotta T, Yamamura S, Shioya Y, Yazawa T. Extraskelletal Ewing's sarcoma mimicking traumatic hematoma. *Arch Orthop Trauma Surg.* 1998;118(3):172-3.
10. Imaizumi S, Morita T, Ogose A, Hotta T, Kobayashi H, Ito T, et al. Soft tissue sarcoma mimicking chronic hematoma: Value of magnetic resonance imaging in differential diagnosis. *J Orthop Sci.* 2002;7(1):33-7.
11. Thomas S, Mendes JD, Souza SA, Lorenzato CS, Assi PE, Pacheco LR, et al. Radioactive synovectomy with (90) yttrium and (153) samarium hydroxyapatite in haemophilic joints: Preliminary study on radiation safety. *Haemophilia.* 2013;19(4):632-6.
12. Baud'huin M, Duplomb L, Téletchéa S, Charrier C, Maillason M, Fouassier M, et al. Factor VIII-von Willebrand factor complex inhibits osteoclast genesis and controls cell survival. *J Biol Chem.* 2009;284(46):31704-13.

Funding: None; Conflict of Interest: None Stated.

How to cite this article: Urmila KV, Saifu S. A rare case of hemophilia with Ewing's sarcoma – A case report. *Indian J Child Health.* 2017; 4(4):623-625.