

## Blue rubber bleb nevus syndrome: A rare cause of chronic gastro intestinal bleed in children

Sufla Saxena, Himanshu Batra, Vikas Taneja

Department of Paediatric Gastroenterology and Hepatology, Manipal Hospital, New Delhi, India

### ABSTRACT

Blue rubber bleb nevus syndrome (BRBNS) is a rare congenital disorder presenting with multifocal venous malformations of the skin, soft tissues, and gastrointestinal (GI) tract. Here, we report a case of a 10-year-old girl who presented with recurrent lower GI bleeding and abdominal pain requiring repeated blood transfusion for 2 years. A contrast computed tomography showed multiple cavernous haemangiomas in the liver, oesophagogastroduodenoscopy and colonoscopy showed multiple hemangiomas from esophagus to large bowel. Her molecular pathology confirmed BRBNS. She underwent endoscopic argon plasma coagulation with uneventful recovery. In spite of a wide range of therapeutic options for the management of BRBNS described in the literature, the efficacy of those available therapies, including surgical excision, is not well established.


**Key words:** Argon plasma coagulation, Autosomal dominant, Blue rubber bleb nevus syndrome, Chronic gastrointestinal bleeding

First described by William Bean in 1958, blue rubber bleb nevus syndrome (BRBNS) is a rare condition characterized by venous malformations in the skin, gastrointestinal (GI) tract and other parts of the body [1]. Its presentation is usually sporadic, but cases of autosomal dominant inheritance have also been reported [2]. Here, we report a case of a 10-year-old girl who presented with recurrent lower GI bleeding and abdominal pain caused by hemangiomas located in the small and large bowel. She underwent endoscopic argon plasma coagulation for her extensive lesions with uneventful recovery. A wide range of therapeutic options for the management of BRBNS was being described in the literature, however, the efficacy of those available therapies, including argon plasma coagulation, is poorly explored till date.

### CASE PRESENTATION

A 10-year-old girl presented to the emergency department with bleeding per rectum, Malena and abdominal pain. She had a past history of similar episodes for which she received multiple blood transfusions. She appeared pale at presentation, but was haemodynamically stable, with a haemoglobin level of 6.1 g/dL. Her coagulation profile was normal. Physical examination showed soft, diffuse, compressible, bluish nodules on her feet,

back and tongue (Fig. 1). Rest of her blood screening including inflammatory markers, liver function test, renal function test, hepatitis screening, human immunodeficiency virus screening, immunoglobulins, antinuclear antibody was within normal limits. A contrast computed tomography (CT) scan of the abdomen was done which showed multiple cavernous hemangiomas in her liver, small bowel and large bowel (Fig. 2). After stabilisation, she underwent oesophagogastroduodenoscopy and colonoscopy which showed multiple hemangiomas from oesophagus to large bowel (Fig. 3). A clinical exome was sent which showed heterozygous pathogenic variation c.2231G>A p.G744E in TEK gene located on chromosome 9p consistent with autosomal dominant inheritance. This spectrum of clinical, endoscopic and genetic findings is consistent with BRBNS. A clinical diagnosis of BRBNS was made based on these findings and in view of the extensive lesions, a surgical excision was proposed initially but the patient refused to undergo for the same. Hence, she underwent endoscopic argon plasma coagulation for her extensive lesions with uneventful recovery along with palliative care with oral propranolol, IV and oral iron. A variety of therapeutic strategies have been proposed for the management of GI bleeding in BRBNS. These include non-interventional (iron supplementation, blood transfusion, antiangiogenic agents, hormonal therapy) and interventional (endoscopic as well as surgical) measures. However, no particular method has been demonstrated to be reliably effective

Access this article online	
Received - 09 July 2021 Initial Review - 31 July 2021 Accepted - 05 October 2021	Quick Response code 
DOI: 10.32677/IJCH.2021.v08.i10.3088	

**Correspondence to:** Dr. Sufla Saxena Department of Paediatric Gastroenterology and Hepatology, Manipal Hospital, New Delhi, India. E-mail: suflagupta@hotmail.com

© 2021 Creative Commons Attribution-NonCommercial 4.0 International License (CC BY-NC-ND 4.0).

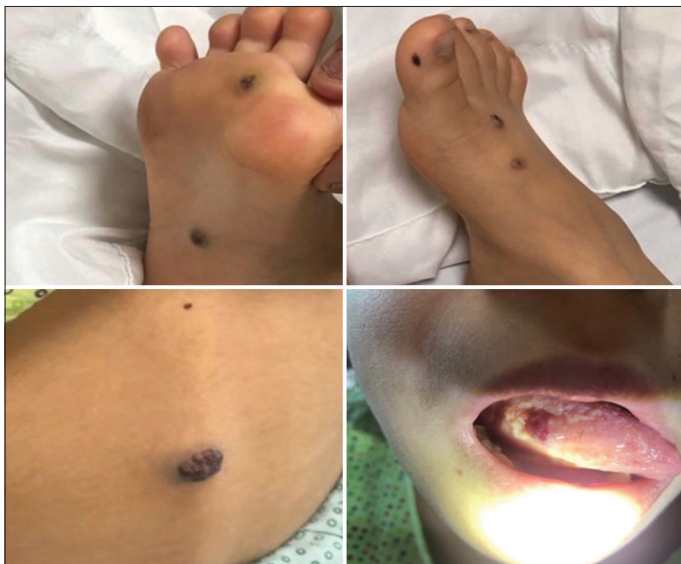

Figure 1: Nevi seen on feet, back and tongue respectively in BRBN

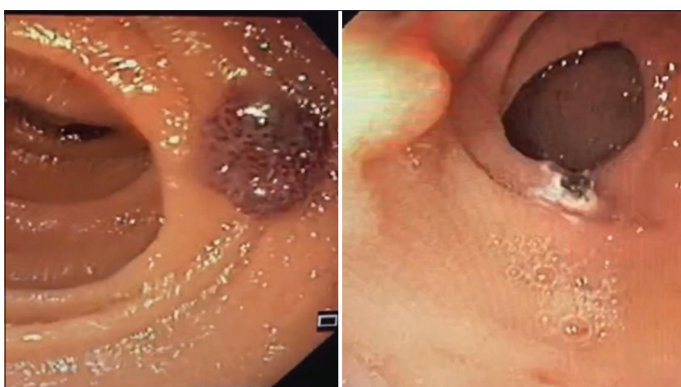

Figure 2: Nevi seen on endoscopy pre and post argon plasma coagulation

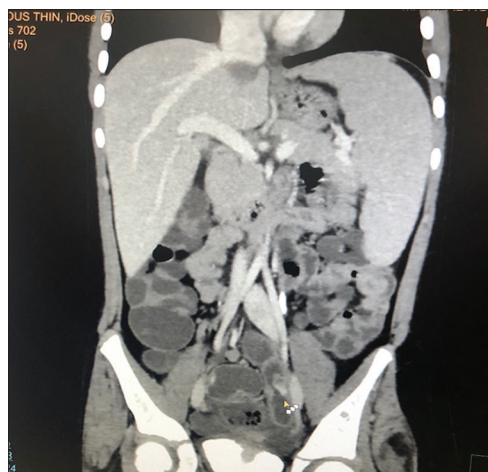

Figure 3: Computed tomography of abdomen reveals multiple hemangiomas in liver, small and large bowel

in reducing bleeding or in permanently controlling blood loss. To date, there are no clinical studies comparing these different treatments. It is important to report more cases in order to know

and understand the prognostic, morbid-mortality, and best modality of treatment. In this case, our patient remains stable with conservative treatment.

## DISCUSSION

BRBNS is a rare condition in childhood. There are only a few case reports in the paediatric age group. The skin and GI tract are the most commonly involved in this disease, and symptoms at presentation vary according to the organ affected. Patients may present with acute GI haemorrhage (in the form of hematemesis, melaena, or haematochezia) or chronic GI bleed (in the form of iron deficiency anaemia) [3]. A wide range of surgical and non-surgical modalities for the management of BRBNS have been described. However, the efficacy of the available therapies, including surgical excision, is not well established.

The treatment of BRBNS depends on the organ involved and the symptoms at presentation, while the management of GI lesions depends on the extent of involvement of the bowel and the severity of the bleed at presentation. In patients with chronic minimal bleed, various antiangiogenic agents (e.g. corticosteroids, interferon-alpha, gamma globulins, and octreotide) have been tried, and there has been response in some patients [4]. However, the long-term benefits of pharmacotherapy are still controversial.

GI lesions can also be treated endoscopically, such as via endoscopic laser photocoagulation and sclerotherapy, which have been reported in the literature [5,6]. For pedunculated lesions, endoscopic removal and band ligation may be attempted. The role of surgical resection in the management of GI lesions has remained controversial because of the belief that the lesions would recur after excision [7,8].

## CONCLUSION

To conclude, this case emphasises that BRBNS is a rare cause of lower GI bleeding in children and early diagnosis and appropriate management is crucial for ensuring better quality of life.

## REFERENCES

1. Wenguo C, Hongtan C, Guodong S, Ming Y, Fengling H, Qi L, *et al.* Blue rubber bleb nevus syndrome. *Medicine* 2017;96:e7792.
2. Gallione CJ, Pasyk KA, Boon LM, Lennon F, Johnson DW, Helmbold EA, *et al.* A gene for familial venous malformations maps to chromosome 9p in a second large kindred. *J Med Genet* 1995;32:197-9.
3. Hasosah MY, Abdul-Wahab AA, Bin-Yahab SA, Al-Rabeaah AA, Rimawi MM, Eyonk YA, *et al.* Blue rubber bleb nevus syndrome: Extensive small bowel vascular lesions responsible for gastrointestinal bleeding. *J Paediatr Child Health* 2010;46:63-5.
4. Boente MC, Cordisco MR. Blue rubber bleb nevus syndrome (Brbns). In: Ruggieri M, Pascual-Castroviejo I, Di Rocco C, editors. *Neurocutaneous Disorders Phakomatoses and Hamartoneoplastic Syndromes*. Vienna:

- Springer; 2008.
5. Jin XL, Wang ZH, Xiao XB, Huang LS, Zhao XY. Blue rubber bleb nevus syndrome: A case report and literature review. *World J Gastroenterol* 2014;20:17254-9.
  6. Andersen JM. Blue rubber bleb nevus syndrome. *Curr Treat Options Gastroenterol* 2001;4:433-40.
  7. Ertem D, Acar Y, Kotiloglu E. Blue rubber bleb nevus syndrome. *Pediatrics* 2001;107:418-20.
  8. Gonzalez-Hernandez J, Lizardo-Sanchez L. An atypical presentation of

blue rubber bleb nevus syndrome. *Baylor Univ Med Cent Proc* 2016;29:323-4.

*Funding: None; Conflicts of Interest: None Stated.*

**How to cite this article:** Saxena S, Batra H, Taneja V. Blue rubber bleb nevus syndrome – A rare cause of chronic gastro intestinal bleed in children. *Indian J Child Health*. 2021; 8(10):374-376.