

Clinico-radiological Correlation of An Uncommon presentation of Caffey's Disease

Cherukuri Nirmala¹, Kommu Pradeep²

From Department of Pediatrics, ¹Government Medical College, Nellore, Andhra Pradesh, ²Gandhi Medical College, Secunderabad, Telangana, India

Correspondence to: Dr. C Nirmala, Flat No. 3, Esteem Villa, Behind Bhavan's School, Vivekanandapuram North, Sainikpuri, Secunderabad, Telangana, India. E-mail: cnirmala06@yahoo.com

Received – 07 March 2016

Initial Review – 10 April 2016

Published Online – 03 May 2016

ABSTRACT

Caffey's disease which is also known as infantile cortical hyperostosis usually affects young infants <6 months of age. It is a rare, mostly self-limiting disease. It is characterized by a triad of soft tissue swelling, cortical thickening of the underlying bone, and hyperirritability. The mean age of the presentation is 9-11 weeks of age. It typically involves the mandible, clavicles, ribs, and diaphysis of the long bones. We report a case of Caffey's disease presenting at an early age of 6 weeks, affecting long bones, with symmetrical involvement of ulnar bones, and thrombocytosis as an uncommon presentation. On follow-up for 48 months, there were no recurrences.

Key words: Caffey's, Long bones, Symmetrical, Thrombocytosis, Ulna

Caffey's disease, also called as infantile cortical hyperostosis (ICH), is characterized by an episode of massive subperiosteal new bone formation typically involving the diaphysis of the long bones, mandible and clavicles, along with soft tissue swelling and systemic symptoms of fever and irritability [1]. It is a rare entity, mostly self-limiting and affecting young infants <6 months of age. The incidence is reported to be 3/1000 worldwide [2]. The differential diagnosis includes osteomyelitis, congenital syphilis, hypervitaminosis A, scurvy, bone tumors, and trauma [3]. The case is being reported to emphasize that Caffey's disease cannot be excluded in the differential diagnosis, whenever there is inflammation of long bones during early infancy, more so when there is no involvement of flat bones.

CASE REPORT

A 6-week-old female infant was referred for the management of soft tissue swelling, the paucity of movements of the left forearm, low-grade fever, excessive cry and irritability of 3 days duration.

The child was born to a primi mother, term gestation by spontaneous vaginal delivery with a birth weight of 3 kg. Antenatal, natal and postnatal history was normal. There was no history of consanguinity. Neonatal period was uneventful. The developmental history was appropriate for age. The infant was immunized with Bacille Calmette-Guérin, oral polio vaccine at birth. She was formula fed and did not receive any vitamin supplements. No history of parental discordance and trauma.

On examination, the infant was irritable, well-nourished with a weight of 4.5 kg, length of 54 cm, and head circumference of 37 cm. The child had low-grade fever but all other vital signs were normal. There was no pallor/icterus/cyanosis/lymphadenopathy/rash. A soft tissue swelling was noted in the left forearm which became prominent over next 3 days. The swelling was sudden in onset, with tenderness and induration. The child was started on parenteral antibiotics initially with a diagnosis of acute osteomyelitis. Swellings of similar nature appeared a week later on the right forearm and left leg associated with fever and irritability.

Hematological investigations showed hemoglobin 9 g/dl, thrombocytosis (8,35,000), total white blood cell counts revealed mild leukocytosis, normocytic normochromic peripheral smear, raised erythrocyte sedimentation rate (ESR) with 75 mm in 1st h, and C-reactive protein (CRP) was positive. Serum alkaline phosphatase (ALP-248 IU/l), calcium, and phosphorus were within normal limits. *Treponema pallidum* particle agglutination assay of mother and baby were normal. Vitamin C (1.33 mg/dl) and vitamin A levels (47 mg/dl) were within normal limits. A blood culture was sterile.

Skeletal Survey showed a diffuse periosteal reaction with cortical thickening involving the diaphysis of both left and right ulnae (Fig. 1) and left tibia (Fig. 2). The epiphysis/metaphysis regions of the involved bones were spared. Rest of the skeletal system is normal. Knee, elbow, and wrist joints are normal.

Magnetic resonance imaging (MRI) of long bones was done. Images of MRI of both forearms and left lower limb in T1

and T2 weighted axial and sagittal planes show normal signal intensities in the medullary regions of the long bones. There is diffuse cortical thickening of the periosteum of left tibia and both ulnae. There was no fluid collection along the long bones. In view of non-responsiveness to antibiotics and involvement of multiple sites other possibilities were entertained. As there was no history of excessive ingestion of vitamins in any form, possibility of hypervitaminosis A was ruled out. As the vitamin C levels were normal, scurvy was excluded. As there was no history suggestive of parental discordance child abuse was excluded.

The presence of periosteal reaction involving multiple long bones with anemia, thrombocytosis, raised ESR, CRP and non-response to antibiotics pointed toward a diagnosis of ICH. To alleviate the symptoms, she was treated with Indomethacin (3 mg/kg/day). The infant became asymptomatic with partial reduction of swelling in 8 weeks and full recovery in 3 months.

Review after 10 and 48 months showed a healthy child with no recurrences and the X-ray findings revealed bone remodeling.

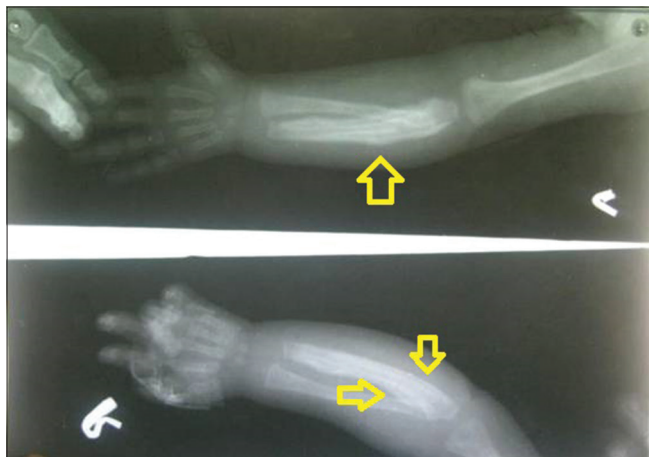

Figure 1: X-ray of forearm bones showing subperiosteal reaction of right and left ulna

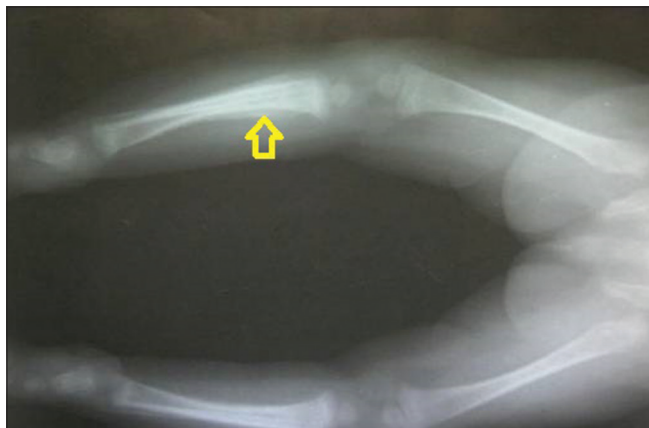


Figure 2: X-ray of left tibia showing subperiosteal reaction

DISCUSSION

Caffey's disease also known as ICH is an uncommon disease during infancy characterized by a triad of systemic symptoms (irritability, fever), soft tissue swelling, and underlying cortical bone thickening. It was first reported in 1945 as a distinct entity by Caffey and Silverman [1]. Caffey's disease is a rare disorder of unknown etiology. ICH is usually sporadic, but the occurrence of a few familial cases suggests an autosomal dominant inheritance with variable penetrance. The commonly affected bones are mandible and tibia in sporadic and familial forms respectively [3,4]. In the familial form, a novel missense mutation COL1A1, which is the gene encoding for the alpha-1 chain of Type 1 collagen was found [5]. The signs and symptoms include fever, hyperirritability, painful swelling, and tenderness of the affected site, with paucity of movements, i.e., pseudoparalysis noted when the extremities are affected. Laboratory investigations demonstrate anemia, moderate leukocytosis, thrombocytosis, increased ESR, CRP, and alkaline phosphatase levels, confirming an inflammatory process [6,7].

There may be involvement of single or multiple bones, and sequential involvement is common. The mandible, clavicle, and ribs are most often involved and the changes are generally symmetrical. Long bones are less commonly involved, usually with an asymmetrical distribution [8]. Although involvement of mandible is diagnostic it may not always be involved [9]. In our case mandible, ribs and clavicles were spared and only long bones were involved. It is rare to find symmetrical involvement of long bones more so of both ulnae which was observed in our case. This along with thrombocytosis presenting at an early age of 6 weeks makes our case unique. Radiography is the most reliable investigation in the diagnosis of ICH [10]. The characteristic radiological findings are cortical and periosteal new bone formation at the affected site.

As the baby was thriving well and there was no history suggestive of marital discordance, child abuse was not considered. The absence of osteolytic lesions on radiography rules out bone tumors. Skeletal changes affect the diaphysis of the bones in ICH rather than the epiphyses or metaphysis which differentiates it from rickets and scurvy [11]. Radionuclide bone scan can be used to know the extent of skeletal involvement [12]. Bone scan is more sensitive but less specific than MRI for diagnosing Caffey's disease [11].

Caffey's disease is mostly self-limiting and resolves within 6 months to 1 year and may not need any treatment [13]. NSAIDs are used for symptomatic relief. Antibiotics should be administered and vitamin A supplements are to be discontinued until the diagnosis can be definitely ascertained. For symptomatic relief, Indomethacin and naproxen were found to be very effective [14]. Rarely, steroids are used if there is poor response to Indomethacin [15]. In cases with

thrombocytosis, use of steroids need to be closely monitored as they may lead to thrombotic episodes. In some cases, sudden recurrence of bony lesions can occur at their original or at new sites. The clinical course is unpredictable with remissions and relapses [16]. A combination of clinical history, examination, basic investigations, and radiography can make a diagnosis of this entity in most cases.

CONCLUSION

The aim of this report is to remind clinicians about the likelihood of this disease, with presenting age much earlier than mean age. To consider it in the differential diagnosis in atypical presentations, with the involvement of only the long bones without the classical presentation involving the flat bones, namely, mandible, clavicles, and ribs.

ACKNOWLEDGMENT

I thank Dr J.V.Rao, the Professor and HOD Department of Paediatrics Gandhi Medical College, Gandhi Hospital, and Dr. Siva Ram Prasad, Professor for their encouragement. I thank Dr. Vasudeva Murali and Dr. T. Usha Rani Associate Professor Paediatrics, Gandhi Medical College for their critical inputs.

REFERENCES

1. Caffey J, Silverman WA. Infantile cortical hyperostosis. Preliminary report on a new syndrome. *Am J Roentgenol Radium Ther Nucl Med.* 1945;54:1-16.
2. Mohammed AL. Caffey Silverman disease: Case report and literature review Kuwait. *Med J.* 2006;38(1):49-52.
3. Borochowitz Z, Gozal D, Misselevitch I, Aunallah J, Boss JH. Familial Caffey's disease and late recurrence in a child. *Clin Genet.* 1991;40(4):329-35.
4. Kamoun-Goldrat A, le Merrer M. Infantile cortical hyperostosis (Caffey disease): A review. *J Oral Maxillofac Surg.* 2008;66(10):2145-50.
5. Gensure RC, Mäkitie O, Barclay C, Chan C, Depalma SR,

- Bastepe M, et al. A novel COL1A1 mutation in infantile cortical hyperostosis (Caffey disease) expands the spectrum of collagen-related disorders. *J Clin Invest.* 2005;115(5):1250-7.
6. Kumar TS, Scott JX, Mathew LG. Caffey disease with raised immunoglobulin levels and thrombocytosis. *Indian J Pediatr.* 2008;75(2):181-2.
7. Caffey J. Infantile cortical hyperostosis. A review of the clinical and radiographic features. *Proc R Soc Med.* 1957;50(5):347-54.
8. Kaufmann HJ, Mahboubi S, Mandell GA. Case report 39. *Skeletal Radiol.* 1977;2(2):109-11.
9. Gentry RR, Rust RS, Lohr JA, Alford BA. Infantile cortical hyperostosis of the ribs (Caffey's disease) without mandibular involvement. *Pediatr Radiol.* 1983;13(4):236-8.
10. Ranadheer M, Murari SB, Sujith N, Jayanthi, Sudhakar P, Rao VP. Scintigraphic and radiological correlative and confirmative features obviating invasive biopsy in Caffey's disease. *Indian J Nucl Med.* 2010;25(14):20-2.
11. Agrawal A, Purandare N, Shah S, Rangarajan V. A rare variant of Caffey's disease - X-rays, bone scan and FDG PET findings. *Indian J Nucl Med.* 2011;26(2):112-4.
12. Katz JM, Kirkpatrick JA, Papanicolaou N, Desai P. Case report 139. Infantile cortical hyperostosis (Caffey disease). *Skeletal Radiol.* 1981;6(1):77-80.
13. Pohl A, Orha L, Dragoi AM. Infantile cortical hyperostosis (Caffey's disease). *Rev Pediatr Obstet Ginecol Pediatr.* 1989;38(4):369-73.
14. Dutta S, Jain N, Bhattacharya A, Mukhopadhyay K. Infantile cortical hyperostosis. *Indian Pediatr.* 2005;42(1):64-6.
15. Varma R, Johnny VF. Infantile cortical hyperostosis. *Indian Pediatr.* 2002;39(11):1057.
16. Hall C. Caffey disease. *Orphanet Encyclopedia.* February, 2005. Available from: <http://www.orpha.net>. [Last accessed on 2009 Apr 03].

Funding: None; Conflict of Interest: None Stated.

How to cite this article: Nirmala C, Pradeep K. An uncommon presentation of Caffey's disease. *Indian J Child Health.* 2016; 3(2):178-180.