

Neurogenic bladder in an adolescent managed by vesicostomy

R B Nerli^{1,2}, Sushant Deole¹, Priyeshkumar Patel¹, Shridhar C Ghagane³, Murigendra B Hiremath⁴, Neeraj S Dixit³

From ¹Department of Urology, JN Medical College, KLE Academy of Higher Education and Research, ³Department of Urology, ²KLES Kidney Foundation, KLES Dr. Prabhakar Kore Hospital and Medical Research Centre, Belagavi, ⁴Department of Biotechnology and Microbiology, Karnataka University, Dharwad, Karnataka, India

Correspondence to: R B Nerli, Department of Urology, JN Medical College, KLE Academy of Higher Education and Research, JNMC Campus, Belagavi, Karnataka, India. E-mail: rbnerli@gmail.com

Received - 30 January 2020

Initial Review - 19 February 2020

Accepted - 16 March 2020

ABSTRACT

The child with a neuropathic or neurogenic bladder requires dedicated care throughout his/her lifetime. Every patient presents with a unique physiology and each phase in their life brings along varying challenges. The primary concern is their renal health, but continence and independence also play significant roles. Although most patients can be managed conservatively, a number of surgical options are also available to manage incontinence. Appropriate pre-surgical planning is required to ensure that the best treatment may be provided. It is important to understand associated potential complications. Long-term follow-up and surveillance are required in all patients. We report a case of an 18-year-old male child who was operated at the age of 6 months for lumbosacral myelomeningocele and was lost to follow-up and later presented with incontinence.

Key words: Long term, Neuropathic bladder, Spina bifida, Vesicostomy

Management of neurogenic bladders remains one of the major challenges of pediatric urology. Despite the advances in technology, knowledge, and medications, desired outcomes may not be achieved. The previous studies observed that children with neurogenic bladders progressed to chronic renal failure and had a significantly reduced life expectancy [1,2]. With proper management and care, the health and quality of life of these patients can be markedly improved.

Children with neurogenic bladders require lifelong care and each child must be thoroughly and independently evaluated irrespective of the diversity of pathophysiology, comorbidities, and expectations. One of the unique aspects of pediatric urological care is the tailoring of care to the development of the child. Family and the child's expectations can change significantly as the child goes through various phases such as the newborn, preschool, elementary, adolescent, and adult periods. Optimal management requires comprehensive knowledge of the family, pathophysiology, and the full complement of treatment options [3]. We report a case of an adolescent male child presenting with complications of neglected care.

CASE REPORT

An 18-year-old male adolescent presented with a history of complete incontinence of urine. He was operated for a lumbosacral myelomeningocele at the age of 6 months and

was asked to come for regular follow-up. The child presented for timely follow-up for about 2 years after surgery and later on discontinued follow-up. On examination, the child had stunted growth. The height of the child was 149.35 cm and weight was 52 kg. The child leaked urine continuously which carried a malodorous smell. On examination, the child had a midline scar over the lower back. There were bilateral lower limb spasticity and lax anal tone with hard stools.

His blood hemoglobin was 10.6 g%, serum creatinine was 4.75 mg%, and serum calcium was 8.3 mg%. Abdominal ultrasonography showed gross dilatation of the pelvicalyceal system of both the kidneys with the parenchymal thickness of 11 mm on the right side and 13 mm on the left side. The bladder was distended and showed trabeculations with irregular walls with wall thickness of 4 mm. Cystometry showed a functional capacity of 46 ml with poor compliance and vesicosphincteric dyssynergia. Plain X-ray kidney, ureter, and bladder region showed spina bifida of lumbar 4th and 5th vertebra (Fig. 1). Magnetic resonance urogram revealed bilateral dilated pelvicalyceal system with thickened bladder wall.

Due to the raised renal parameters and bilateral dilated system, Blocksom vesicostomy (Fig. 2) was planned to allow low pressure drainage of urine and improvement of renal function. The patient's serum creatinine came down to 4.4 mg% at the end of 2 weeks, suggesting that the kidneys had progressed to chronic renal failure. Estimated glomerular filtration rate was 16.5 ml/h.

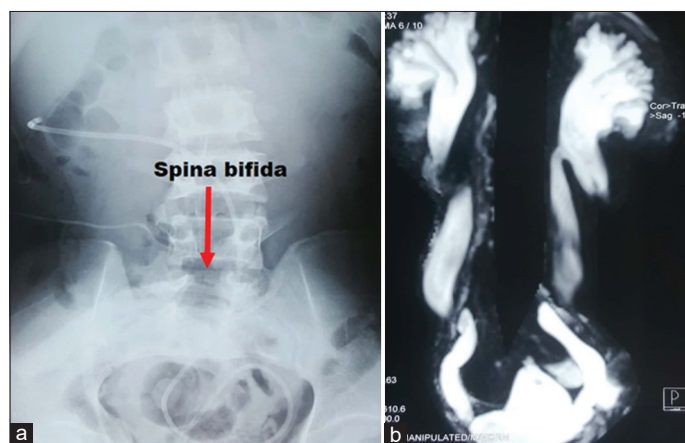


Figure 1: (a) Plain X-ray kidney, ureter, and bladder region shows L4-5 spina bifida. (b) Plain magnetic resonance urogram shows B/L hydronephroureterosis with irregular thickened bladder

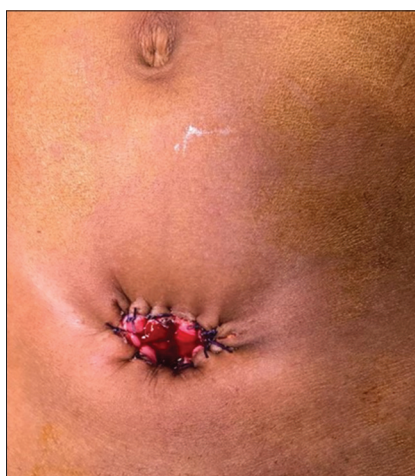


Figure 2: Vesicostomy performed

DISCUSSION

The management of patients with neuropathic/neurogenic bladder secondary to spina bifida has evolved significantly over the past two decades. Early goals of management are to maintain a low pressure/high compliance bladder, prevent upper urinary tract deterioration (UTD), and preserve renal function [4]. Initial treatment strategies may include clean intermittent catheterization, anticholinergic medications, and detrusor botulinum toxin injection. When these are unsuccessful, more advanced approaches such as bladder augmentation or vesicostomy are performed [4].

Improvement in the care of these patients has resulted in a drastic increase in the life expectancy. Unfortunately, this has also resulted in a significant gap in health care as these children grow on to become adolescents and then adults. The neurosurgical and orthopedic issues stabilize at sometime; however, the urological problems of these adult patients remain at the forefront. Incontinence and high bladder pressures are prevalent, especially since many are without their parental supports. Although surgical intervention is quite prevalent

at this age, endoscopic revisions to continent diversions and bladder stones account for a majority of the cases [3]. Over a period of time, catheterizing becomes an increasing burden and many patients look toward converting to an incontinent diversion.

Long-term compliance and risks of renal insufficiency in the patients who have had prior reconstructions are a matter of concern as studied by Husmann [5]. He concluded that an incontinent diversion is preferable in an adult with a neurogenic bladder, as many are unable to provide sufficient self-care to ensure their long-term health. Suprapubic management is the simplest means of maximizing renal preservation. Vesicostomy is a form of suprasphincteric incontinent urinary diversion that accomplishes the goal of maintaining a low-pressure urinary system. It is an alternative to bladder augmentation when conservative strategies have failed [6]. It is also a permanent diversion for selected cases of neurogenic bladder [7,8].

Donmez *et al.* evaluated the outcomes of 14 patients (eight females and six males) who underwent cutaneous vesicostomy for the management of neurogenic bladder secondary to spina bifida [4]. Seven patients had a median of three (range 1–5) febrile UTI before surgery for cutaneous vesicostomy. Median creatinine level before surgery was 0.26 mg/dL (range 0.16–0.97). Median age at vesicostomy creation was 26.5 months (range 4–96). Mean functional bladder capacity assessed during pre-operative urodynamic studies was 107 mL (range 20–279), and detrusor sphincter dyssynergia was present in all patients. High-grade vesicoureteral reflux (grade ≥ 3) was present in three patients, all with UTD. Mean follow-up after vesicostomy was 62.4 \pm 39.3 months. After vesicostomy, only two of the seven patients with a history of febrile UTIs experienced an additional febrile UTI. The median serum creatinine level was 0.36 mg/dL (range 0.2–0.58) at last follow-up. Moreover, 11/14 patients had no hydronephrosis and just two patients had unilateral SFU Grade 1 hydronephrosis. The authors concluded that vesicostomy was a safe method for temporary diversion of the lower urinary tract in patients with spina bifida who were refractory to conservative and minimally invasive treatments.

CONCLUSIONS

The child with spina bifida problem requires a lifetime of complex and intensive urological care. There is a great potential to improve their quality of life, however, this requires a comprehensive and accurate assessment of the patient's wishes and abilities. One should never ignore the significant complications that can occur and must be vigilant to ensure supportive follow-up.

REFERENCES

1. Singhal B, Mathew KM. Factors affecting mortality and morbidity in adult spina bifida. *Eur J Pediatr Surg* 1999;9:31-2.
2. Oakeshott P, Reid F, Poulton A, Markus H, Whitaker RH, Hunt GM. Neurological level at birth predicts survival to the mid-40s and urological deaths in open spina bifida: A complete prospective cohort study. *Dev Med*

- Child Neurol 2015;57:634-8.
3. Metcalfe PD. Neuropathic bladders: Investigation and treatment through their lifetime. *Can Urol Assoc J* 2017;11:S81-6.
 4. Donmez MI, Carrasco A Jr., Saltzman AF, Vemulakonda V, Wilcox DT. Long-term outcomes of cutaneous vesicostomy in patients with neuropathic bladder caused by spina bifida. *J Pediatr Urol* 2017;13:622.
 5. Husmann DA. Long-term complications following bladder augmentations in patients with spina bifida: Bladder calculi, perforation of the augmented bladder and upper tract deterioration. *Transl Androl Urol* 2016;5:3-11.
 6. Morrisroe SN, O'Connor RC, Nanigian DK, Kurzrock EA, Stone AR. Vesicostomy revisited: The best treatment for the hostile bladder in myelodysplastic children? *BJU Int* 2005;96:397-400.
 7. Nerli RB, Patil RA, Ghagane SC. Revisited blocksom vesicostomy: Operative steps. *J Sci Soc* 2017;44:58-60.
 8. Hutcheson JC, Cooper CS, Canning DA, Zderic SA, Snyder HM 3rd. The use of vesicostomy as permanent urinary diversion in the child with myelomeningocele. *J Urol* 2001;166:2351-3.

Funding: None; Conflicts of Interest: None Stated.

How to cite this article: Nerli RB, Deole S, Patel P, Ghagane SC, Hiremath MB, Dixit NS. Neurogenic bladder in an adolescent managed by vesicostomy. *Indian J Child Health.* 2020; 7(4):190-192.

Doi: 10.32677/IJCH.2020.v07.i04.014