

Comparison of clinical outcomes in patients with congenital anorectal malformation treated with posterior sagittal anorectoplasty and laparoscopically assisted anorectal pull through

Vijaymahantesh S Kunnur¹, Chandra Shekhar Singh², Shanthala V Kunnur³, Anil Kumar S Kunnur⁴

From ¹Department of Pediatric Surgery, Rajiv Gandhi Super Speciality Hospital, Raichur, Karnataka, ²Era's Lucknow Medical College and Hospital, Lucknow, Uttar Pradesh, ³Consultant Pediatrician, Poojya Shri Sharanbasaveshwar, Raichur, Karnataka, ⁴Department of Anaesthesiology, K.E.M Hospital, Pune, Maharashtra India

Correspondence to: Chandra Shekhar Singh. E-mail: dr.cssingh@yahoo.in

Received – 05 August 2016

Initial Review – 31 August 2016

Published Online – 02 November 2016

ABSTRACT

Aim: To compare the complications and outcomes of laparoscopic-assisted anorectoplasty (LAARP) for anorectal malformation (ARM) with that of posterior sagittal anorectoplasty (PSARP) using Kelly's score. **Materials and Methods:** This was a single-center study conducted over a period of 4-year. A total of 95 male ARM patients were included in the study, of which 25 patients underwent LAARP, whereas 70 patients underwent PSARP. **Result:** Superficial wound infection was seen in 2 (2.85%) cases of the PSARP group while in 1 (4%) case in LAARP group. 12 (17.14%) cases of PSARP group had wound dehiscence at the neo-anal site, of which 6 (8.57%) had complete wound dehiscence and the remaining 6 (8.57%) had partial dehiscence, whereas 4 (16%) cases had wound dehiscence in LAARP group of which 3 (12%) had partial and 1 (4%) had complete dehiscence. Retraction of the neo-anus was seen in 6 (8.57%) cases of PSARP group while in 2 (8%) cases of LAARP group. Ectopically placed neo-anus was seen in 3 (4.28%) patients of PSARP group while in none of the cases in LAARP group. None of the patients in LAARP group had anal stenosis, whereas 2 (2.85%) patients underwent redoanoplasty in PSARP group for anal stenosis. Mucosal prolapse was seen in 8 (11.42%) cases of PSARP group, as compared to 3 (12%) patients of LAARP group. The net average Kelly's score in LAARP group was 4.56, whereas, in PSARP group, it was 4.10. **Conclusion:** This study emphasizes the emerging laparoscopic technique for the management of ARMs. Using this approach, it is possible to achieve better continence rates as the extent of perineal dissection is minimal.

Key words: Kelly's score, Laparoscopic anorectal pull through, Laparoscopic-assisted anorectoplasty, Posterior sagittal anorectoplasty

Anorectal malformations (ARM) affect about 1 in 5000 live born infants [1]. For those with high or intermediate defects (supra-levator or levator-level defects), colostomy in the newborn period is life saving. However, long-term quality of life (QOL) after the construction of a neo-anus and colostomy closure is still unsatisfactory. The modalities of treatment for high and intermediate ARMs are posterior sagittal anorectoplasty (PSARP) or laparoscopic-assisted anorectal pull through (LAARP). Georgeson introduced LAARP in 2000 [2], which involves less dissection and improved visualization of the rectal fistula. LAARP has gained popularity mainly in the management of prostatic or bladder-neck fistulae that would otherwise require laparotomy. The main aim of this study was to compare the complications and outcomes of LAARP for ARM with PSARP using Kelly's score [3].

MATERIALS AND METHODS

The study was conducted in New Amruta Children Hospital and Research Centre, Raichur, Karnataka, India, over a period

of 4-year from July 2009 to October 2013. All male patients of ARM with diversion colostomy were included in the study except patients with low ARM and pouch colon. A total of 115 male ARM patients were initially included in the study, but 20 patients were lost to follow-up, and only 95 patients were finally included in the study. Out of 95 patients, 25 underwent LAARP, whereas 70 patients underwent PSARP (65 patients underwent standard PSARP, whereas 5 patients underwent abdominal PSARP for rectovesical fistula). PSARP or LAARP was done within 6 weeks to 3 months of first surgery in all patients except two patients who presented late. One patient who underwent first surgery (colostomy) elsewhere, presented to us at the age of 4.5 years (because of illiteracy and financial problems) underwent standard PSARP, and another patient presenting late at 1.5 years underwent LAARP. The youngest patients in both groups who underwent second surgery were 3 months old. The distribution of location of fistula encountered in both the groups is shown in Table 1. All LAARP surgery was done by a single surgeon, whereas PSARP was done by different surgeons following standard surgical steps.

Table 1: Distribution of fistula encountered in PSARP as well as LAARP groups

Fistula site	PSARP	LAARP
Recto vesical fistula	5	5
Recto prostatic urethral fistula	37	12
Recto bulbar urethral fistula	21	5
No fistula	7	3

LAARP: Laparoscopic-assisted anorectoplasty PSARP: Posterior sagittal anorectoplasty

Surgical Procedure

A written informed consent was taken from the patients' parents or attenders before enrolling them for the study.

LAARP

Under general anesthesia, the patient's abdomen, perineum, and lower extremities are prepared. Urethral catheterization is done carefully and watched for easy drainage of urine, which confirms that the catheter bulb is in the urinary bladder and not in fistula or the rectum. We use three ports for the procedure. Periumbilical stay sutures with heavy silk (2, 0) at 9 and 3 o' clock positions are taken, and the umbilical incision is made with sharp number 11 blade. A 5 mm port is inserted in the peritoneal cavity, following which pneumoperitoneum is created with carbon dioxide maintaining a pressure of 8-10 mmHg. A zero degree telescope is inserted through the port, and thorough inspection of the peritoneal cavity is done. Then, 3 mm or 5 mm ports (depending on the patient size) are placed in left and right upper quadrants in mid clavicular line. All the ports are inserted under direct vision and control (Fig. 1).

Once position, access, and exposure have been achieved, rectal dissection follows. Incising the peritoneum at the peritoneal reflection with hook cautery, the mesorectum is dissected circumferentially making sure to stay right on the rectal wall (Fig. 2). It is important to identify the ureters and vas deferens bilaterally to avoid injury to these structures during the rectal dissection. As the rectum tapers into the fistula, the recto genitourinary fistula is then transected and dissected without clipping. The rectum is then reflected cephalad, and the pelvic floor is examined. The space from the apex of the pubococcygeus muscle extending posteriorly is identified and developed (Fig. 3). This will be the space through which the rectum will be passed. The vas deferens medially points to the prostate, which aids the surgeon in locating the urethra so to avoid inadvertently injuring it.

Attention is then paid to the perineum, the patients' hips and knees are flexed in such a fashion that the knees are directed up to the patient's shoulders. This position straightens the path for the pull through. The center of superficial anal sphincter is mapped with a muscle stimulator. The area of maximal contraction is marked at its anterior and posterior limits. A 4 cm sagittal incision is made sharply in the center of the sphincter and the subcutaneous tissue is dissected bluntly, making every effort to stay in midline (Fig. 4). The laparoscopic transillumination is then seen at the

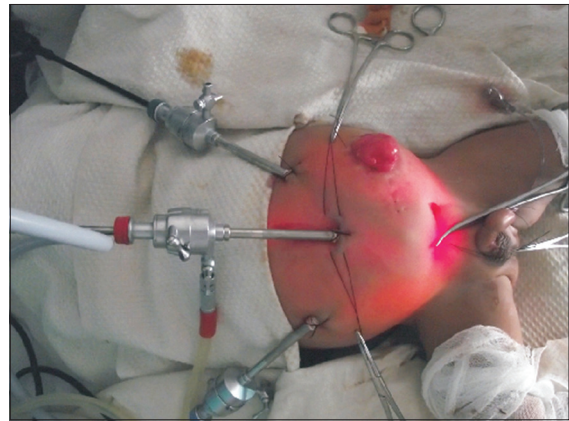


Figure 1: Final appearance after placement of all the ports for laparoscopic-assisted anorectoplasty

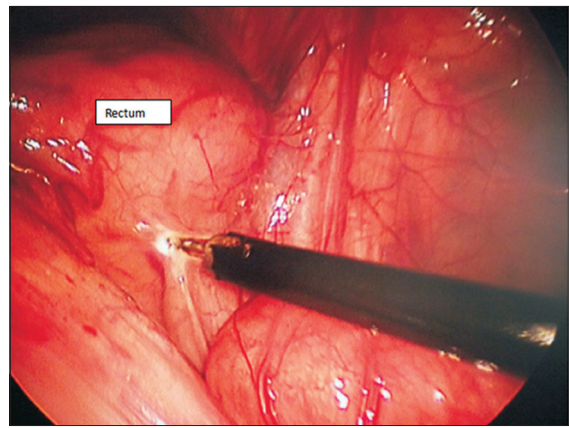


Figure 2: Peritoneal dissection close to the rectal wall in laparoscopic-assisted anorectoplasty

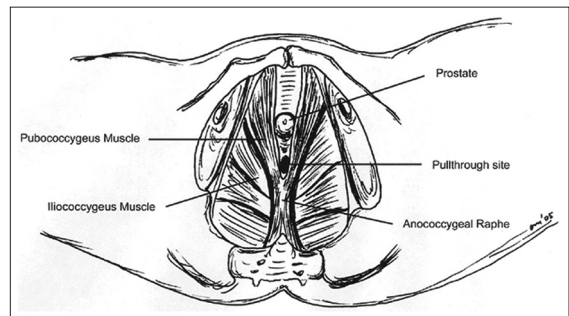


Figure 3: Pull through site in laparoscopic-assisted anorectoplasty through the center of the sphincter complex

site of perineal dissection, and a long curved artery forceps is passed through that tract. Once artery forceps enter the pelvis in the desired position through the sphincter, under vision, the distal end of the rectum is fed to the artery forceps, which is then pulled out toward the perineum. Care should be taken while pulling the rectum down such that there should not be any twisting of the rectum. Anoplasty is then carried out (Fig. 5).

The abdominal cavity and pelvis are inspected laparoscopically for hemostasis, the pneumoperitoneum is released, and all the ports are removed. The linea alba at the level of the umbilical port is reapproximated with 3/0 vicryl sutures, and all the abdominal skin incisions are closed with single horizontal mattress sutures.

PSARP

Under general anesthesia, the patient is catheterized with infant feeding tube of 8 French. The patient is positioned prone at the edge of the table and pelvis elevated by keeping a soft cotton roll underneath the groin. Electro-stimulation of the external sphincter is done, and the anterior and posterior extents of the sphincter are noted and marked. An incision is made strictly in midline extending from the mid sacrum to the marked anterior extent of the sphincter. The muscles of the perineum and sphincter complex are divided in the midline, and presacral fascia is reached. The fascia is opened in the midline near the tip of the coccyx and rectum is identified. The rectum is dissected circumferentially and followed distally till its narrowing is visible, which indicates the site of fistula. The fistula is ligated and divided. The distal end of rectum is then brought out in midline through the divided sphincter muscle complex and anoplasty is done. The levator ani muscle is approximated and wound closed in layers. The urethral catheter is removed on post-operative day five.

All patients underwent colostomy closure at six weeks to 6 months post-PSARP or LAARP surgery.

Kelly's scoring (Table 2) of all the patients was used to assess continence, staining, and sphincter mechanism. Overall, the score of 0-2 was taken as poor, 3-4 as fair, and 5-6 as good outcome.

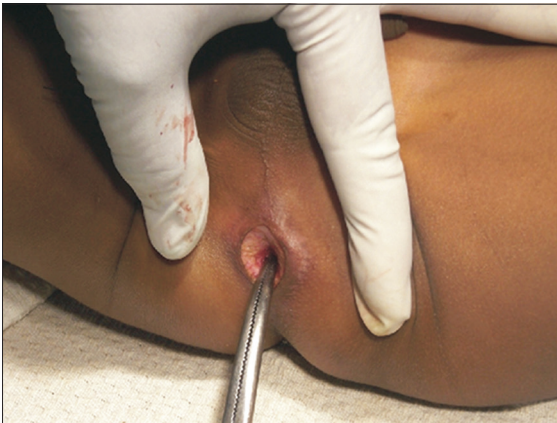

Figure 4: Perineal dissection for creation of space exactly in the midline for rectal pull through

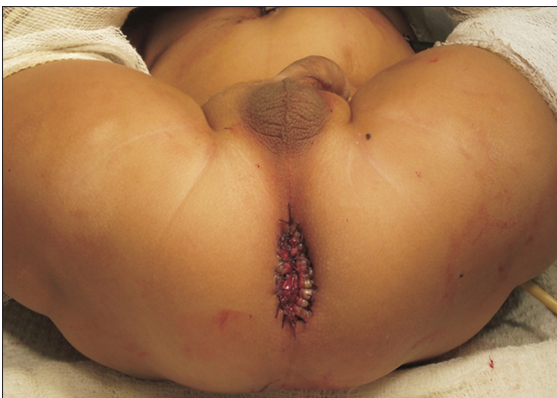

Figure 5: Final appearance after laparoscopic-assisted anorectoplasty and anoplasty

RESULTS

There were no anesthetic or intraoperative complications in both groups. Early post-operative complications included superficial wound infection, wound dehiscence, and rectal retraction, whereas late post-operative complications included anal strictures, mucosal prolapse, and cases where the neo-anus was not centered within the sphincter complex (Table 3). Superficial wound infection at the subcutaneous level which was seen in 2 (2.85%) cases of the PSARP group which was due to surgical site hematoma, and 1 (4%) case in LAARP group. All were managed conservatively with simple saline washes and oral antibiotics.

Around 12 (17.14%) cases of PSARP group had wound dehiscence at the neo-anal site, of which 6 (8.57%) had complete wound dehiscence and the remaining 6 (8.57%) had partial dehiscence. All the cases were managed conservatively without the need for any surgical intervention. 4 (16%) cases had wound dehiscence in LAARP group, of which 3 (12%) had partial and 1 (4%) had complete dehiscence with all being managed conservatively.

Retraction of the neo-anus was seen in 6 (8.57%) cases of PSARP group, of which 4 retractions occurred in high rectoprostic urethral fistula cases; these were the patients who had difficult rectal mobilization during surgery. Rest of the two cases of retraction had rectobulbar urethral fistula. In LAARP

Table 2: Kelly's score

Continence		
Normal, no soiling		2
Occasional accidents, feces/flatus escape		1
No control, frequent accidents		0
Staining		
Always clean		2
Occasional staining		1
Always stained		0
Sphincter		
Strong and effective squeeze		2
Weak and partial squeeze		1
No contraction		0

Table 3: Post-operative complications

Complications	PSARP (%)	LAARP (%)
Early		
Wound sepsis (sub cutaneous level)	2 (2.85)	1 (4)
Wound dehiscence	12 (17.14)	4 (16)
Retraction	6 (8.57)	2 (8)
Late		
Ectopically placed anus	3 (4.28)	0 (0)
Anal stenosis/stricture	2 (2.85)	0 (0)
Mucosal prolapsed	8 (11.42)	3 (12)
Total complications	33 (47)	10 (40)

Early complications: $\chi^2=0.09643$, p: 0.9529, NS: Not significant, late complications: $\chi^2=1.626$, p: 0.6535, NS: Not significant. LAARP: Laparoscopic-assisted anorectoplasty, PSARP: Posterior sagittal anorectoplasty

group, 2 (8%) patients had rectal retraction, 1 patient with rectovesical fistula and another patient with short distal segment. Both the patients underwent redo surgery (PSARP) at a later date.

Ectopically placed neo-anus was seen in 3 (4.28%) patients of PSARP group; these were the cases done by senior residents in early residency period, and later, these patients underwent anterior sagittal anorectoplasty. None of the patients of LAARP group had ectopically placed anus.

None of the patients in LAARP group had anal stenosis, whereas 2 (2.85%) patients underwent redo anoplasty in PSARP group for anal stenosis. Mucosal prolapse was seen in 8 (11.42%) cases of PSARP group, of which 5 had partial prolapse and 3 had circumferential mucosal prolapse. In LAARP group, 3 (12%) patients had mucosal prolapse, of which 2 had partial and 1 had circumferential prolapse, all the cases of prolapse underwent mucosal excision. Overall complication rate in PSARP group was 47%, whereas, in LAARP group, it was 40%.

In terms of continence, three cases (12%) of the LAARP group depended on rectal washouts to achieve social continence, compared to 11 cases (15.71%) of the PSARP group. To the other end of the spectrum, severe constipation was seen in 7 cases (10%) of the PSARP group versus 1 case (4%) of the LAARP group. The net average Kelly's score in LAARP group was 4.56, whereas, in PSARP group, it was 4.10. The average Kelly's scores, when compared to specific fistula types in both the groups, were also favorable for the LAARP group (Table 4).

DISCUSSION

ARMs are associated with significant morbidity because of problems with fecal continence after surgical correction. The modern approach to ARM was heralded by the description of PSARP in 1982 [4]. Traditional descriptions according to the Wingspread classification have been largely superseded by the classification of Pena [5], which allows more meaningful comparison of outcome data. This study provides contemporary data on both early functional and QOL outcomes in children with ARM. Over the years, surgeons have made major contributions to our knowledge of the normal anorectal anatomy [6] and the anatomy of ARM [7]. Stephens [8], Rehbein [9], and Kiesewetter [10], to name a few, appreciated the concept of

placement of the rectum into the levator sling mechanism, and developed the abdominoperineal and later the sacroabdomino perineal approaches for the treatment of high ARM. The adequate visualization of the sphincteric mechanism could be achieved through posterior sagittal approach by division of the external sphincter and levators in the midline to expose the bowel and the associated genitourinary fistula. Unfortunately, PSARP while exposing the muscles responsible for the continence also divides the constricting mechanism of the muscle complex. This may be detrimental for continence.

The greatest benefit of LAARP derives from the fact that it allows the surgeon to treat a high lesion essentially like a low lesion. The basic concept is that of fistula transfer from the urethra or the vagina through the levator sling and external anal sphincter muscle complex to the perineal surface. There is no need to divide the muscle complex from below.

The evaluation of functional outcome after operative repair of ARM has been severely compromised by confusion over classification and the lack of a universally accepted method of assessing continence. Various scores including those of Kelly [3], Iwai [11] Templeton and Ditesheim [12], Kiesewetter and Chang [13], Holschneider [14], and Stephens et al., [15] have been used.

Four studies compared LAARP to PSARP in patients with high or intermediate ARM. These studies included 47 patients. Only one study was prospective in nature, and none were randomized comparisons. These 4 studies compared patients with regard to the following outcomes: Stool frequency, continence, anatomical position of pull through rectum, sphincter function, and symmetry using different post-operative modalities such as manometry, anal endoultrasonography, magnetic resonance imaging (MRI), Kelly's score, and continence evaluation questionnaire. The 4 studies unanimously concluded that LAARP seems to be superior to PSARP for patients with high/intermediate ARM. All 4 studies uniformly concluded that long-term follow-up is necessary to assess fecal continence. In the study by Lin et al., [16], defecation status and anorectal manometry of 9 patients with high/intermediate imperforate anus repaired with LAARP and 13 age-matched patients repaired with PSARP were assessed and compared during the first year of post-operative follow-up evaluation. The study concluded that patients repaired with LAARP had more favorable findings with regard to anorectal manometry than patients repaired with PSARP.

Wong et al. [17] conducted a retrospective review of 10 children with high/intermediate-type imperforate anus, who underwent LAARP between May 2000 and December 2002. MRI of the pelvis was performed postoperatively; the study concluded that LAARP allows for more optical anatomical reconstruction in patients with high/intermediate-type imperforate anus. In the study by Kudou et al. [18], LAARP was performed in 13 patients with high-type imperforate anus between 2000 and 2002. The midterm follow-up of this study revealed that satisfactory fecal continence can be achieved in patients with high-type imperforate anus after LAARP and can be a good alternative in this patient population.

Table 4: Group wise average Kelly's score and net average Kelly's score in LAARP and PSARP groups

Type of fistula	LAARP (average Kelly's score)	PSARP (average Kelly's score)
Rectovesical fistula	4.25	4.10
Recto prostatic urethral fistula	4.12	4.08
Rectobulbar urethral fistula	5.68	4.12
No fistula	4.19	4.13
Net average score	4.56	4.10

t-test: $t=1.208$, $p=0.2723$, NS: Not significant, LAARP: Laparoscopic-assisted anorectoplasty, PSARP: Posterior sagittal anorectoplasty

In a prospective nonrandomized comparative study by Ichijo et al. [19], 24 cases of high/intermediate-type imperforate anus were studied. Within the group, 15 underwent LAARP, and 9 underwent PSARP. The study concluded that although there were no significant differences between the 2 groups, LAARP appeared to provide better outcomes based on CEQ (continence evaluation questionnaire) scores, consisting of 5 parameters: Frequency of defecation, staining/soiling, perianal erosion, anal shape, and requirement for medication.

In our study, the overall complication rate in PSARP group is 47%, whereas, in LAARP group, it is slightly lower (40%). In terms of continence, 15.71% of patients in the PSARP group were severely incontinent depending on rectal washouts to achieve social continence, compared to 12% of the patients in LAARP group. Furthermore, severe constipation was seen in 10% cases of the PSARP group versus 4% cases of the LAARP group. The net average Kelly's score in LAARP group was 4.56, whereas, in PSARP group, it was 4.10. The average Kelly's scores, when compared to specific fistula types in both the groups, were also favorable for the LAARP group. Although the sample size is more in PSARP group compared to the LAARP group, the results appear to be more favorable with the LAARP group. The reason for overall slightly better outcomes in LAARP group could be the less dissection in the perineal region, hence less damage to the muscle complex and the nerves supplying it.

The cost-effectiveness of the both the groups is well comparable, previously it was thought that the LAARP is costlier than PSARP, but in our study, no much cost difference was detected in comparison with the PSARP group.

Considering post-operative morbidity, complications, and functional outcomes, LAARP appears to be slightly superior to PSARP (although statistically not significant). Further studies with larger samples are required to establish the superiority of one procedure over the other.

CONCLUSION

This study emphasizes the emerging laparoscopic technique for the management of ARMs. Using this approach, it is possible to achieve better continence rates as the extent of perineal dissection is minimal, hence inflicting minimal neural and sphincter injury. With the laparoscopic approach, it is possible to visualize the fistula better and even the higher vesical fistulae can be dealt easily. The esthetic appearance following LAARP is better, and complication rates are less.

REFERENCES

1. Smith ED. Incidence, frequency of types, and etiology of anorectal malformations. *Birth Defects Orig Artic Ser.* 1988;24(4):231-46.
2. Georgeson KE, Inge TH, Albanese CT. Laparoscopically assisted anorectal pull-through for high imperforate anus – A new technique. *J Pediatr Surg.* 2000;35(6):927-30.
3. Kelly JH. The clinical and radiological assessment of anal continence in childhood. *Aust N Z J Surg.* 1972;42(1):62-3.
4. Peña A. Anorectal malformations. *Semin Pediatr Surg.* 1995;4(1):35-47.
5. Levitt MA, Peña A. Anorectal malformations. *Orphanet J Rare Dis.* 2007;2:33.
6. Shafik A. A new concept of the anatomy of the anal sphincter mechanism and the physiology of defecation. The external anal sphincter: A triple-loop system. *Invest Urol.* 1975;12(5):412-9.
7. Kiesewetter WB, Nixon HH. Imperforate anus. Its surgical anatomy. *J Pediatr Surg.* 1967;2:60-8.
8. Stephens FD. Imperforate anus: A new surgical technique. *Med J Aust.* 1953;2:2002.
9. Rehbein F. Imperforate anus: Experience with abdominoperineal and abdominosacroperineal pull through procedures. *J Pediatr Surg.* 1967;2:99-105.
10. Kiesewetter WB. Imperforate anus: II. The rationale and technique of the abdominoperineal operation. *J Pediatr Surg.* 1967;2:106-10.
11. Iwai N, Yanagihara J, Tokiwa K, Takahashi T. Rectoanal pressure studies and postoperative continence in imperforate anus. *Prog Pediatr Surg.* 1989;24:115-20.
12. Ditesheim JA, Templeton JM Jr. Short-term v long-term quality of life in children following repair of high imperforate anus. *J Pediatr Surg.* 1987;22(7):581-7.
13. Kiesewetter WB, Chang JH. Imperforate anus: A five to thirty year follow-up perspective. *Prog Pediatr Surg.* 1977;10:111-20.
14. Holschneider AM. Treatment and functional results of anorectal continence in children with imperforate anus. *Acta Chir Belg.* 1983;82(3):191-204.
15. Stephens FD, Smith ED. Classification, identification, and assessment of surgical treatment of anorectal anomalies. *Pediatr Surg Int.* 1986;1:200-5.
16. Lin CL, Wong KK, Lan LC, Chen CC, Tam PK. Earlier appearance and higher incidence of recto anal relaxation reflex in patients with imperforate anus repaired with laparoscopically assisted anorectoplasty. *Surg Endosc.* 2003;17(10):1646-9.
17. Wong KK, Khong PL, Lin SC, Lam WW, Lan LC, Tam PK. Post-operative magnetic resonance evaluation of children after laparoscopic anorectoplasty for imperforate anus. *Int J Colorectal Dis.* 2005;20(1):33-7.
18. Kudou S, Iwanaka T, Kawashima H, Uchida H, Nishi A, Yotsumoto K, et al. Midterm follow-up study of high-type imperforate anus after laparoscopically assisted anorectoplasty. *J Pediatr Surg.* 2005;40(12):1923-6.
19. Ichijo C, Kaneyama K, Hayashi Y, Koga H, Okazaki T, Lane GJ, et al. Midterm postoperative clinicoradiologic analysis of surgery for high/intermediate-type imperforate anus: Prospective comparative study between laparoscopy-assisted and posterior sagittal anorectoplasty. *J Pediatr Surg.* 2008;43(1):158-62.

Funding: None; Conflict of Interest: None Stated.

How to cite this article: Kunnur VS, Singh CS, Kunnur SV, Kunnur AKS. Comparison of clinical outcomes in patients with congenital anorectal malformation treated with posterior sagittal anorectoplasty and laparoscopically assisted anorectal pull through. *Indian J Child Health.* 2016; 3(4):330-334.