

Isolated congenital factor VII deficiency

Anand Suresh Somkuwar¹, Saira Merchant², Rajkumar Meshram³, Mukesh Waghmare⁴, Manisha Mahalinge⁵, Tushar Somkuwar⁶

From ¹Senior Resident, ²Professor, ³Associate Professor, Department of Pediatrics, ⁴Assistant Professor, ⁵Senior Resident, Department of Pathology, ⁶Senior Resident, Department of Radiology, Government Medical College, Nagpur, Maharashtra, India

Correspondence to: Dr. Anand Suresh Somkuwar, Department of Pediatrics, Government Medical College, Hanuman Nagar, Ajni Road, Nagpur - 440003, Maharashtra, India. E-mail: somkuwar761@gmail.com

Received - 10 October 2019

Initial Review - 26 October 2019

Accepted - 08 November 2019

ABSTRACT

Congenital factor VII (FVII) (proconvertin) is a rare autosomal recessive bleeding disorder. Bleeding manifestations and clinical findings vary widely, ranging from being asymptomatic to life-threatening bleeding. Intracranial bleeding is relatively less common with inherited FVII deficiency than with other coagulation disorders. We report a rare case of congenital FVII deficiency in an 11-year-old male child. The patient had recurrent subdural hemorrhages. The prothrombin time was markedly prolonged with a normal bleeding time, normal partial thromboplastin time and normal platelet count. Treatment consists of replacement therapy with fresh frozen plasma, prothrombin complex concentrates or plasma-derived FVII concentrates, and/or recombinant factor VIIa. Clinical heterogeneity is the hallmark of this disorder.

Key words: *Congenital factor VII deficiency, Inherited bleeding disorder, Recombinant factor VIIa*

Isolated congenital factor VII (FVII) (proconvertin) deficiency is a rare autosomal recessive bleeding disorder. Bleeding manifestations and clinical findings vary widely. There may be asymptomatic or can develop to life-threatening bleeding [1]. Although the highest incidence of intracranial hemorrhage is observed in factor (F)XIII deficiency (~30%), intracranial hemorrhage is less common in afibrinogenemia, FVIII, FIX, FVII, and FX deficiencies and is rare in severe FV and FII deficiencies, Type 3 von Willebrand disease and inherited platelet function disorders [2]. Treatment of congenital FVII deficiency consists of replacement therapy with fresh frozen plasma (FFP), prothrombin complex concentrates (PCCs) or plasma-derived FVII concentrates, and/or recombinant factor VIIa (rFVIIa) [3].

CASE REPORT

An 11-year boy was admitted to the department of neurosurgery with severe headache and vomiting for 2 days. It was not associated with convulsions, altered sensorium, or fever. The patient gave history of trauma to head 3 years back. He had vomiting and mild headache at that time. Computed tomography (CT) brain had revealed subdural hemorrhage in left temporoparietal region which was treated conservatively and was not further investigated for bleeding disorders. There was a history of single blood transfusion 4 years back when patient had a complaint of bleeding from rectum. There was no history of bleeding from

any other site. The child was born of a non-consanguineous marriage after an uneventful pregnancy and delivery. He had one normal younger sibling. There was no significant family history suggestive of any bleeding disorder.

Physical examination revealed a pulse rate of 110 beats/min, respiratory rate 24/min, blood pressure of 100/70 mmHg, and body temperature was 37.3°C. He had mild pallor, but there were no icterus, petechiae, or ecchymosis. Ear, nose, and throat examination was within normal limits. Systemic examination did not reveal hepatosplenomegaly or lymphadenopathy. There were no clinical signs of hepatic dysfunction and neurological status of the child was normal. CT brain demonstrated a large right frontoparietal subdural hemorrhage 13 mm thick with midline shift of 10 mm toward left (Fig. 1).

The child received FFP preoperatively and underwent emergency evacuation of subdural hemorrhage due to worsening of neurological status. Postoperatively, he received eight units of FFP and Vitamin K. His post-operative period was uneventful and he was transferred later to the department of pediatrics for further management.

Laboratory findings were as follows: Hemoglobin 9.8 g/dl; white blood cell count of 9100/mm³, and platelet count of 313,000/mm³. Screening tests for hemostasis showed a bleeding time of 5 min (Ivy's technique, normal 2–7 min) and a clotting time of 12 min (Lee and White, normal 4–9 min). Liver function tests were within normal limits. Coagulation profile showed that prothrombin time (PT) was prolonged 38 s (control 12 s),

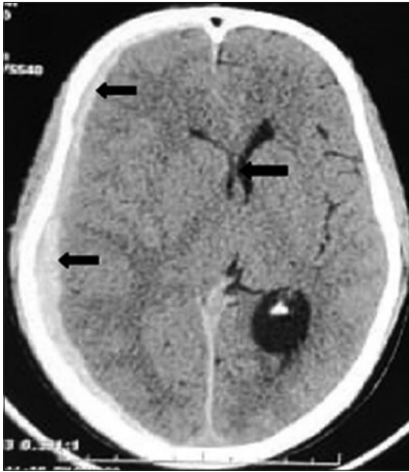


Figure 1: Computed tomography brain head axial image showing large right frontoparietal subdural hemorrhage with shift of midline toward the left and dilatation of contralateral lateral ventricle

partial thromboplastin time (PTT) with Kaolin was normal – 28 s (control 24 s) with INR of 4.28. Thrombin time was done which was normal - 7 s (control 8 s).

Serum fibrinogen level was within normal limits. Mixing studies were done in our patient. A 1:1 mixture of normal control plasma mixed with the patient's plasma showed complete correction of PT. We did not screen for the presence of specific inhibitors as mixing studies showed normalization of PT. Since PT was repeatedly prolonged even after FFP and Vitamin K supplementation in the post-operative period, isolated FVII deficiency was suspected. Later on FVII assay was done, which showed the functional activity of 4.2% of normal (70.00–120.00). Coagulation profiles of both parents were within normal limits and thus the diagnosis of FVII deficiency was established. The child was asymptomatic on further 1 year follow-up. He did not require prophylactic FVII infusion during this period.

DISCUSSION

Congenital FVII deficiency is a rare autosomal recessive bleeding disorder that has a prevalence of 1 in 500,000 [4]. FVII deficiency was first described by Alexander *et al.* [5]. Cases of FVII deficiency were reported in India by Jagruti *et al.* [6] and Krishnan *et al.* [7]. Narang *et al.* reported combined FVII and X deficiency [8]. The clinical presentation of FVII deficiency is heterogeneous, and the bleeding severity is not directly related to the FVII levels [9]. Type 1 deficiency occurs due to decreased biosynthesis or accelerated clearance and Type 2 abnormalities occur due to a dysfunctional molecule. Mostly, missense mutations have been identified in the FVII gene located on chromosome 13 which is mostly associated with missense mutations [10].

Acquired FVII deficiency may arise due to Vitamin K deficiency, Vitamin K antagonist therapy, or liver disease. In these conditions, reduced FVII levels are associated with reduced levels of other Vitamin K-dependent

factors. Acquired FVII deficiency is more common than inherited deficiency [11,12]. There is a poor correlation between FVII coagulation activity and bleeding tendency [13]. Prolonged PT with a normal PTT should be suspected of FVII deficiency. The prolonged PT is corrected by normal serum as it is rich in FVII [14]. Definitive diagnosis can be made by specific assay of FVII activity.

rFVIIa is the most widely accepted replacement therapy in acute bleeding at 15–30 mg/kg of body weight. Thrombosis related to rFVIIa treatment is very rare and no risk of virus transmission, and rarely leads to the development of inhibitory antibodies. However, it has short half-life and is expensive. FFP is an effective, cheap, and easily available option but can cause fluid overload. It is acceptable for newborns (e.g., a minimally invasive diagnostic procedure or a minor cutaneous surgery). PCC and activated PCC were the possible options but are associated with post-treatment thrombosis. FFP, PCCs, and FVII concentrates are associated with the risk of transmission of pathogens [15]. Antifibrinolytic tranexamic acid could be used in minor bleeding symptoms such as mild menorrhagia alone or in combination with replacement therapy [15]. Prophylaxis programs should be established to prevent central nervous system and gastrointestinal bleeding episodes and/or their recurrences in infants with FVIIc levels <1%, and in young children with recurrent hemarthroses [16].

CONCLUSION

Isolated congenital FVII deficiency is a rare bleeding disorder suspected in a healthy bleeding child when platelets and activated PTT are normal and there is deranged PT. Clinical heterogeneity is the hallmark of this disorder; the severity ranges from lethal to mild, and there are asymptomatic forms.

REFERENCES

1. Lee WS, Park YS. A case of intracranial hemorrhage in a neonate with congenital factor VII deficiency. *Korean J Pediatr* 2010;53:913-6.
2. Alavi SE, Jalalvand M, Assadollahi V, Tabibian S, Dorgalaleh A. Intracranial hemorrhage: A devastating outcome of congenital bleeding disorders-prevalence, diagnosis, and management, with a special focus on congenital factor XIII deficiency. *Semin Thromb Hemost* 2018;44:267-75.
3. Mariani G, Konkle BA, Ingerslev J. Congenital factor VII deficiency: Therapy with recombinant activated factor VII-a critical appraisal. *Haemophilia* 2006;12:19-27.
4. Mannucci PM, Duga S, Peyvandi F. Recessively inherited coagulation disorders. *Blood* 2004;104:1243-52.
5. Alexander B, Goldstein R, Landwehr G, Cook CD. Congenital SPCA deficiency: A hitherto unrecognized coagulation defect with hemorrhage rectified by serum and serum fractions. *J Clin Invest* 1951;30:596-608.
6. Sanghvi JP, Muranjan MN, Bavdekar SB, Parmar RC. Congenital factor VII deficiency. *Indian J Pediatr* 2004;71:441-3.
7. Krishnan P, Dabre L, Jatoo Z, Burli P. Factor VII deficiency in a home delivered neonate. *J Adv Med Dent Sci Res* 2018;6:14-5.
8. Narang GS, Arora S, Pahwa JS. Combined factor VII and X deficiency. *Online J Health Allied Sci* 2010;9:179.
9. Cattivelli K, Distefano C, Bonetti L, Testa S, Siboni SM, Plebani A, *et al.* Recurrent bleedings in newborn: A factor VII deficiency case report. *Transfus Med Hemother* 2018;45:104-6.

10. Mahale R, Rathi P, Ginegiri C, Aggarwal R. Factor VII deficiency: A rare case report. *Indian J Hematol Blood Transfus* 2010;26:68-9.
11. Biron C, Bengler C, Gris JC, Schved JF. Acquired isolated factor VII deficiency during sepsis. *Haemostasis* 1997;27:51-6.
12. Jeremy G, Vinod KG. Acquired factor VII deficiency in wilms tumor. *Pediatr Blood Cancer* 2009;52:394-5.
13. Mariani G, Dolce A, Marchetti G, Bernardi F. Clinical picture and management of congenital factor VII deficiency. *Haemophilia* 2004;10 Suppl 4:180-3.
14. Sikka M, Gomber S, Madan N, Rusia U, Sharma S. Congenital deficiency of factor VII. *Indian J Pediatr* 1996;63:571-3.
15. Sevenet PO, Kaczor DA, Depasse F. Factor VII deficiency: From basics to clinical laboratory diagnosis and patient management. *Clin Appl Thromb Hemost* 2017;23:703-10.
16. Brenner B, Wiis J. Experience with recombinant-activated factor VII in 30 patients with congenital factor VII deficiency. *Hematology* 2007;12:55-62.

Funding: None; Conflict of Interest: None Stated.

How to cite this article: Somkuwar AS, Merchant S, Meshram R, Waghmare M, Mahalinge M, Somkuwar T. Isolated congenital factor VII deficiency. *Indian J Child Health*. 2019; 6(11):629-631.

Doi: 10.32677/IJCH.2019.v06.i11.015