

Varied clinical presentation of Meckel's diverticulum in pediatric population

S Pramod¹, G S Meghan², G Sridhar²

From ¹Associate Professor, Department of Pediatric Surgery, ²Resident, Department of Surgery, Kempegowda Institute of Medical Sciences and Research Institute, Bengaluru, Karnataka, India

Correspondence to: Dr. S Pramod, Department of Paediatric Surgery, Kempegowda Institute Of medical Sciences and Research Institute, K. R. Road, V. V. Puram, Bengaluru, Karnataka - 560 004, India. E-mail: pramodbmc76@gmail.com

Received - 24 April 2019

Initial Review - 07 June 2019

Accepted - 11 June 2019

ABSTRACT

Background: Meckel's diverticulum (MD) is one of the most prevalent congenital abnormalities of the small intestine. Due to its wide-ranging presentations, it often becomes a challenge to diagnose it. **Objective:** The objective of the study is to analyze varied clinical manifestations of MD in children and their outcomes. **Materials and Methods:** This was a retrospective study of children diagnosed with MD in the Department of Pediatric Surgery, Medical College of Karnataka from January 2015 to January 2019. A total of 13 patients (10 male and 3 female) aged 1 month–15 years with a diagnosis of MD were included in the study. Their demographic and clinical parameters, investigation, and histopathological findings along with the surgical interventions were collected and analyzed. **Results:** Patients were presented with varied clinical features such as intestinal obstruction (30.76%), perforated MD (15.38%), diverticulitis (15.38%), gastrointestinal bleed (7.69%), patent vitellointestinal duct (7.69%), and incidental (23.07%). All the cases were investigated and underwent treatment. The most common post-operative complication was wound infection in 2 children which were treated conservatively. **Conclusion:** A pre-operative diagnosis of complicated MD may be challenging because of the overlapping clinical and imaging features of the other acute surgical and inflammatory conditions of the abdomen. Therefore it is necessary to maintain a high incidence of suspicious in the pediatric age group.

Key words: Congenital, Gastrointestinal tract, Meckel's diverticulum, Perforation

Although originally described by Fabricius Hildanus in 1598, it is named after Johann Friedrich Meckel who established its embryonic origin in 1809; Meckel's diverticulum (MD) has transformed into a common congenital abnormality of the gastrointestinal tract, with the occurrence rate of approximately 2% [1]. MD is a true intestinal diverticulum containing all normal layers of the intestinal wall. It is located 30–60 cm from the ileocecal junction. In 50% cases, it contains ectopic tissue (gastric mucosa in 60–85% and 5–16% pancreatic tissue) [2]. Failure of the vitelline duct to obliterate during the 5th week of fetal development results in the occurrence of MD. The incomplete obliteration results in a diverticulum in the small intestine. Majority of the cases are asymptomatic, and MD is found incidentally during other surgeries.

Children are more prone to complications due to the ectopic epithelial lining and various bands. The lifetime risk of MD complications varies from 4 to 34%. 50–60% of children who are <2 years of age are more prone to have complications associated with MD [3]. The complications present with non-specific symptoms mimicking other acute abdominal conditions like appendicitis which makes the diagnosis difficult. The manifestation of MD through its different clinical outcome brings diagnostic challenges in children, and often this condition is diagnosed during surgery. Risk factors for increased risk of developing symptoms include age younger than 50, male gender,

diverticulum >2 cm of length, the presence of ectopic tissue, broad-based diverticulum, and fibrous bands attached to the diverticulum. The purpose of this study was to analyze the diverse clinical manifestations of MD in children and their outcome.

MATERIALS AND METHODS

This retrospective observational study was conducted in the Department of Pediatric Surgery of a Tertiary Care Teaching Institution of Bangalore, Karnataka, over a period of 4 years, from January 2015 to January 2019. All patients <18 years of age with MD who presented during the study period were included in the study after obtaining consent. The exclusion criteria consisted of children with MD with inadequate data. The data of children with respect to sex, age, symptoms, and their duration were tabulated. All children underwent routine and specific investigations according to symptoms such as erect X-ray abdomen, ultrasonography (USG) abdomen, computed tomography (CT) abdomen, and Meckel's scan.

The children were categorized depending on the presentation into two groups, emergency and elective patients. The symptomatology of the patients was tabulated. With respect to symptoms, the children were divided into two broad groups: Those with intestinal obstruction (band obstruction and intussusception) and those without intestinal obstruction (bleeding, perforation,

inflammation, and incidental). The children underwent resection anastomosis or diverticulectomy. Using absorbable sutures, ileum of about 5 cm on either side of the diverticulum was excised and the anastomosis was done in 2 layers. In diverticulectomy, only wedge resection of the diverticulum was done and the bowel continuity was established using absorbable sutures.

Patients were followed up for a period of 6 months–4 years post-surgery. The complication with respect to immediate and late post-operative period was analyzed. In the immediate post-operative period, complications observed were wound infection, bleeding, anastomotic leak, and pelvic abscess. In the late post-operative period, complications observed were anastomotic stricture and adhesive obstruction. The data were analyzed using descriptive statistical methods. Descriptive statistical analyses included determination of mean, median, and mode of the data.

RESULTS

Thirteen children were present with MD in the study period. The age of the children at presentation ranged between 3 months and 15 years (Table 1).

Mean age of presentation was 93±43.9 months. Out of 13 children, 10 (77%) were males and 3 (23%) were females. The male-to-female ratio was 3.3:1. Total 11 (84.6%) out of 13 children were presented to the casualty as an emergency. The mean age of children presenting to casualty was 107.1±33.1 months. The clinical features of the included children are mentioned in Table 2.

Table 1: Age and sex incidence

Characteristics	Number (%)
Age (year)	
<2	03 (23.07)
2–10	05 (38.46)
>10	05 (38.46)
Sex	
Male	10 (76.92)
Female	3 (23.07)

Table 2: Presentation, investigation, and treatment of all the children

Age/Sex	Symptoms	Investigation	Diagnosis	Surgery
3 months/M	Bilious vomiting, distention	X-ray	Band obstruction	Resection
5 years/F	Pain abdomen, distention	CT scan	Band obstruction	Resection
10 years/M	Bilious vomiting, distention	X-ray	Band obstruction	Diverticulectomy
3 years/M	Bilious vomiting, pain abdomen	USG	Obstruction due to intussusceptions	Resection
10 years/M	Pain abdomen, vomiting	USG	Diverticulitis	Resection
5 years/M	Pain abdomen, vomiting	USG	Diverticulitis	Diverticulectomy
2 years/F	Bleeding per rectum	Meckel's scan	MD with ectopic gastric mucosa	Resection
12 years/M	Pain abdomen, distension	X-ray	Meckel's perforation	Resection
11 years/M	Pain abdomen, distension	X-ray	Meckel's perforation	Resection
6 months/M	Bilious discharge from umbilicus	USG	Patent vitellointestinal duct with Meckel's	Resection
15 years/M	Pain abdomen, distention	X-ray	Duodenal perforation with Meckel's diverticulum	Diverticulectomy
12 years/F	Pain abdomen, vomiting	USG	Acute appendicitis with Meckel's diverticulum	Appendicectomy
15 years/M	Pain abdomen, vomiting	USG	Acute appendicitis with Meckel's diverticulum	Appendicectomy

M: Male, F: Female, USG: Ultrasonography, CT: Computed tomography

The most common symptom of the children was pain in the abdomen followed by vomiting. All 11 cases were subjected to routine and specific investigations. The X-ray showed air under diaphragm in 3 cases (perforation) and multiple air-fluid levels in 2 (obstruction) while it was inconclusive in 2 cases as only dilated bowel loops could be visualized [Figure 1]. USG was suggestive of intussusceptions in 1 case and appendicitis in 2 cases. CT scan showed band obstruction in 1 child.

In two children with features of diverticulitis, all the investigations were inconclusive; however, laparotomy was performed in view of acute abdomen. All 11 cases were subjected for emergency exploratory laparotomy. Three cases had small bowel obstruction in the region of ileum due to mesodiverticular band [Figure 2b] The band was released with resection anastomosis done in two cases and diverticulectomy in one case. In one child, cause of obstruction was intussusception with Meckel's as a lead point. This child underwent resection anastomosis. In two cases, Meckel's perforation was noticed and these children underwent resection anastomosis [Figure 2].

Four cases presented with clinical features of appendicitis. In two cases, during laparoscopic appendicectomy, incidental normal MD was observed. These children underwent the only appendectomy as we found wide-based MDs. In the remaining

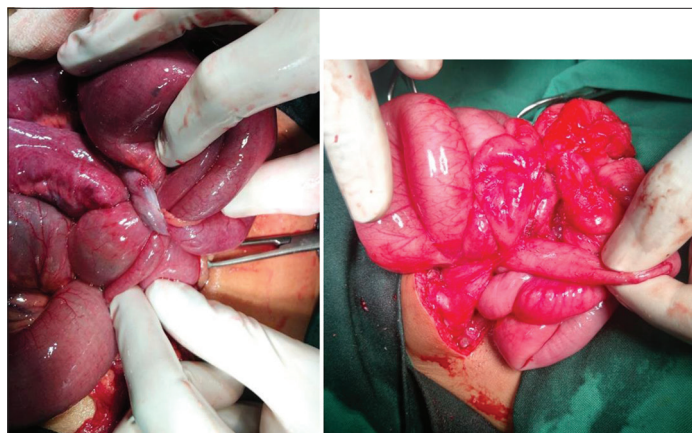


Figure 1: Meckel's band causing obstruction

two cases, normal appendix was observed intraoperatively, but MD was inflamed (diverticulitis) and both of them underwent excision of MD [Figure 3]. One child with air under diaphragm on X-ray was found to have duodenal perforation with MD, intraoperatively. Perforation was closed with Graham's procedure along with diverticulectomy.

A 2-year-old child was presented with bleeding per rectum for 3 months. On clinical examination, anemia was reported. Meckel's scan showed ectopic gastric mucosa in the periumbilical region, right of the midline, suggestive of the MD which was treated with resection anastomosis of MD [Figure 4]. A 6-month-old child was presented with a history of greenish-colored discharge from the umbilicus, since birth. USG showed evidence of track extending from umbilicus to bowel. On exploration, a patent vitellointestinal duct with MD was found. The child underwent resection anastomosis of MD [Figure 5].

During follow-up, three out of 13 cases (23%) had complications and the most common surgical complication was wound infection which was observed in two cases. In both the

cases, wound was treated with regular dressing. 5-month post-surgery, one child was presented with adhesive obstruction and he was treated conservatively by keeping him nil by oral and intravenous fluids. None of the children required re-exploration.

DISCUSSION

The worldwide distribution of MD is approximately in 2% of the population but symptomatic in only 4–6% of the patients [4]. "Rule of two" is characteristic for MD, which includes the prevalence in 2% of the population, diagnosed under the age of two, it is two-inches size and 2 cm diameter, two feet proximal to the ileocecal valve [5,6]. The male-to-female ratio is reported to be around 2:1–4:1 [7]. In the present study, the ratio was 3.3:1. Complications in MD occur more commonly in males. The median age of presentation in the present study was 7.7 years. In other series, the median age of presentation was ranging from 3.1 to 5.2 years [8,9]. The youngest child in the present study was 3 months old.

MD can present with a wide range of complications such as intestinal obstruction, hemorrhage, diverticulitis, and perforation.

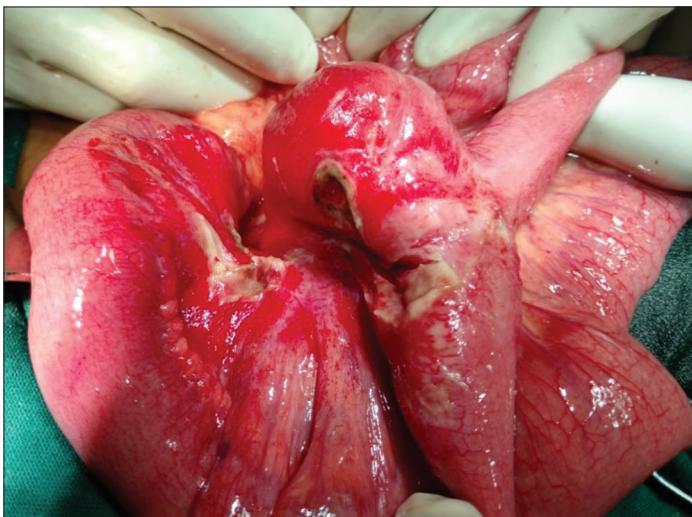


Figure 2: Meckel's perforation

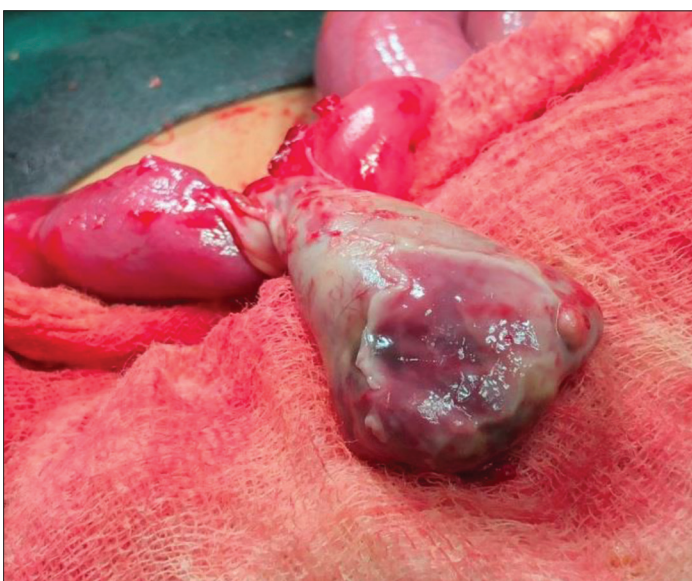

Figure 3: Meckel's Diverticulitis

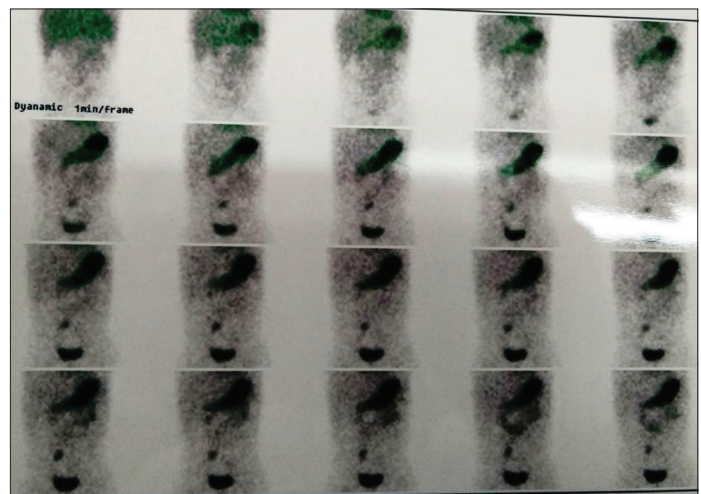


Figure 4 : Meckel's scan showing ectopic gastric mucosa

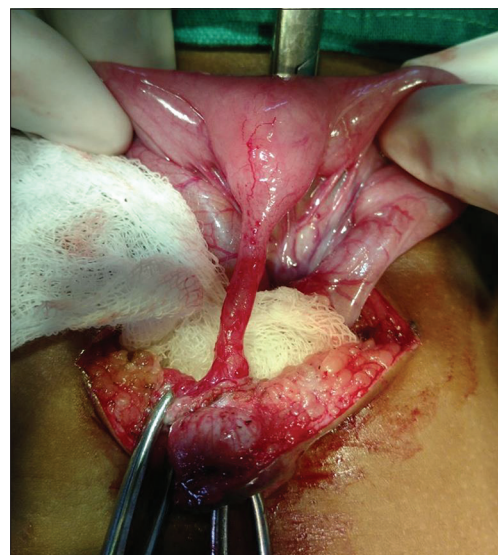

Figure 5: Patent vitello intestinal tract with Meckels

Intestinal obstruction is a leading presence in all age groups globally with a prevalence of 38–80% [10]. In children, intestinal obstruction is reported as the second most common presentation. However, Mayo clinical experience reported intestinal obstruction as the most common complication in a pediatric age group with an incidence of 40% [11]. In the present study, intestinal obstruction was the most common presentation seen in 30% of the children.

Hemorrhage is a common complication in a pediatric age group. Incidence is as high as 50% but ranges between 27 and 56% [12]. The average age of the patient with hemorrhage is 2.1 years. In the present study, age of the child presenting with hemorrhage was 2 years. Intestinal hemorrhage occurs as a result of ulceration of the intestinal wall due to acid/alkali production by ectopic mucosa. Authors observed found ectopic gastric mucosa in the present study case.

Intestinal hemorrhage in children can occur in many conditions such as polyps, clotting disorder, and arteriovenous malformations. Tc-99 sodium pertechnetate is very useful in defining the presence of ectopic gastric mucosa due to high affinity for parietal cells. The sensitivity of Meckel's scan is 81–90% and specificity is more than 95%. It is preferred investigation in children with unexplained gastrointestinal hemorrhage due to its non-invasiveness.

Diverticulitis is common in older children with an incidence of around 2.7–19.5% [13]. In the present study, incidence was 15.38%. Clinical presentation is usually similar to appendicitis. If treatment is delayed, it leads to perforation. There are more chances of peritonitis in perforated MD than appendicitis because diverticulum lies free in the peritoneal cavity. Two children in our group presented with perforation. The incidence of perforation ranges from 6.6 to 13% [14], while in the present study, it was 15.38%. In two children, MD was incidentally found during laparoscopic surgery for acute appendicitis. In both the children, Meckel's was not removed as both had a wide base.

Controversy exists in the management of incidentally detected MDs. It is reported that if an MD is found incidentally during the course of an operation, it can be left alone provided and it is wide mouthed and not thickened [15]. On the contrary, there are opinions that incidentally found Meckel's should be resected. The rationale behind this is that the lifetime risk of potential complication of MD is 5–6% and the complication rate from prophylactic resection is only 1% [16]. Both the children in the present study were on regular follow-up.

Definitive management of symptomatic MD is surgery through either wedge resection diverticulectomy or segmental resection and anastomosis. In the present study, three cases underwent diverticulectomy and eight cases underwent segmental resection and anastomosis. MD accounts for 6–7.5% mortality and morbidity of 6–30% [17]. No deaths occurred in the present study and two children had wound infections; both were treated conservatively with dressing. One child presented with adhesive obstruction 5 months after the primary surgery. The child recovered with conservative management.

CONCLUSION

Pre-operative diagnosis of MD may be challenging because of the overlapping clinical and imaging features of other acute surgical conditions. Intestinal obstruction was the most common complication observed in our study. As this condition can mimic other abdominal diseases, a high degree of suspicion is required for timely diagnosis and surgical intervention to reduce morbidity.

REFERENCES

1. Meckel JF. Uber die divertikel am darmkanal. Arch Physiol 1809;9:421-53.
2. Maroof SA, Khan MJ, Yousuf K, Uzair M. Surgical management of omphalomesenteric duct remnant in children. J Postgrad Med Inst 2009;23:179-83.
3. Moore GP, Burkle FM Jr. Isolated axial volvulus of a Meckel's diverticulum. Am J Emerg Med 1988;6:137-42.
4. Mayo CW. Meckel's diverticulum. Proc Mayo Clin 1933;8:230.
5. Altaf A, Aref H. A case report: Cecal volvulus caused by Meckel's diverticulum. Int J Surg Case Rep 2014;5:1200-2.
6. Murruste M, Rajaste G, Kase K. Torsion of Meckel's diverticulum as a cause of small bowel obstruction: A case report. World J Gastrointest Surg 2014;6:204-7.
7. Menezes M, Tareen F, Saeed A, Khan N, Puri P. Symptomatic Meckel's diverticulum in children: A 16-year review. Pediatr Surg Int 2008;24:575-7.
8. Pollak R. Adjunctive procedure in intestinal surgery. In: Mastery of Surgery. 5th ed. Philadelphia, PA: Lippincott Williams and Wilkins; 2007. p. 1392-3.
9. Bazrafshan A, Heydarian F, Rahmani S. Meckel's diverticulum: Prevalence in 1000 laparotomies. Patient Saf Qual Improv 2013;1:10-2.
10. Rehman I, Burki T, Alam S, Rahman F. Presentations of Meckel's diverticulum at Khyber teaching hospital Peshawar. J Ayub Med Coll Abbottabad 2003;15:30-2.
11. Ruscher KA, Fisher JN, Hughes CD, Neff S, Lerer TJ, Hight DW, *et al.* National trends in the surgical management of Meckel's diverticulum. J Pediatr Surg 2011;46:893-6.
12. Blevrakis E, Partalis N, Seremeti C, Sakellaris G. Meckel's diverticulum in paediatric practice on Crete (Greece): A 10-year review. Afr J Paediatr Surg 2011;8:279-82.
13. Oguzkurt P, Talim B, Tanyel FC, Caglar M, Senocak ME, Büyükpamukçu N. The role of heterotopic gastric mucosa with or without colonization of *Helicobacter pylori* upon the diverse symptomatology of Meckel's diverticulum in children. Turk J Pediatr 2001;43:312-6.
14. Mittal BR, Kashyap R, Bhattacharya A, Singh B, Radotra BD, Rao KL, *et al.* Meckel's diverticulum in infants and children; technetium-99m pertechnetate scintigraphy and clinical findings. Hell J Nucl Med 2008;11:26-9.
15. Norman SW, Christopher JK, O'Connell PR. Bailey and Love's Short Practice of Surgery. 25th ed. London: Hodder Arnold; 2008. p. 1158-9.
16. Ciardo LF, Agresta F, Bedin N. Meckel's diverticulum. A neglected entity. Chir Ital 2004;56:689-92.
17. Cullen JJ, Kelly KA, Moir CR, Hodge DO, Zinsmeister AR, Melton LJ 3rd, *et al.* Surgical management of Meckel's diverticulum. An epidemiologic, population-based study. Ann Surg 1994;220:564-8.

Funding: None; Conflict of Interest: None Stated.

How to cite this article: Pramod S, Meghan GS, Sridhar G. Varied clinical presentation of Meckel's diverticulum in pediatric population. Indian J Child Health. 2019; 6(6):320-323.

Doi: 10.32677/IJCH.2019.v06.i06.014