

Joubert syndrome: Case report of three affected siblings

Lt Col Saikat Bhattacharjee¹, Lt Col Suprita Kalra², Lt Col Preema Sinha³, Col Samar Chatterjee⁴

From Department of Radiology, ¹Military Hospital, Kirkee, ⁴Command Hospital, ²Department of Pediatrics and Pediatric Nephrology, Command Hospital, ³Department of Dermatology, Armed Forces Medical College, Pune, Maharashtra, India

Correspondence to: Dr. Suprita Kalra, Department of Pediatrics and Pediatric Nephrology, Command Hospital, Pune, Maharashtra, India. Phone: +91-9871467926. E-mail: kalrasuprita@gmail.com

Received – 08 January 2017

Initial Review – 09 February 2017

Published Online – 17 March 2017

ABSTRACT

Joubert syndrome (JS) is a rare autosomal recessive disorder that has variable phenotype but characteristic magnetic resonance imaging (MRI) findings. “Molar tooth” appearance of cerebellar peduncles and “bat-wing” appearance of the fourth ventricle are the classically described MRI findings. Herein, we describe JS in three siblings, products of a second-degree consanguineous marriage, who presented with developmental delay, abnormal eye movements, and impaired vision. The axial MRI in all three siblings revealed the classic MRI findings described in the JS.

Key words: Ciliopathies, Joubert syndrome, Molar tooth sign

Joubert syndrome (JS) is an extremely rare and under reported autosomal recessive hereditary disorder characterized by episodes of ataxic breathing, abnormal eye movements, hypotonia, ataxia, and developmental retardation with evidence of neuropathologic abnormalities of the cerebellum and brainstem [1]. The extreme heterogeneity of phenotype often causes a delay in the diagnosis of this disorder.

CASE REPORT

Three siblings, two males aged 16 and 14 years and a female aged 13 years, products of a second-degree consanguineous marriage were brought to the Pediatric Outpatient Department of a tertiary care hospital for poor scholastic performance, decreased vision, abnormal eye movements, and history of frequent falls while walking. All the three children had institutional delivery with no history of perinatal asphyxia and a birth weight of >2.5 kg. The abnormal eye movements were noticed shortly after birth. There was global developmental delay in all three siblings with history of being able to walk without support only after 3 years of age. The poor vision was noticed by the parents in late infancy. The speech was late to develop in the two male siblings and the female sibling could not speak till date. There was no history of seizures.

Clinical examination revealed that all the three children were thin built with weight, height, and head circumference between –2 and –3 standard deviations for age [2]. Head to toe examination revealed mild facial dysmorphism in the form of broad, prominent foreheads and widely spaced, and deep-set eyes. There was no cleft lip, cleft palate, and polydactyly. Furthermore, there were no neurocutaneous markers. Eye examination revealed a normal pupillary reaction and a normal fundus examination. Ocular apraxia was present with intermittent movements of eyes

to extremes of gaze were noted throughout the examination. All the three children had tachypnea with a respiratory rate of 30/min, 32/min, and 36/min, respectively. Speech in the male children was dysarthric and staccato in nature. The girl child had no verbal speech output. The neurological evaluation revealed a power of 4+ in all joints for all three children with truncal and limb hypotonia. Motor examination revealed hypotonia with exaggerated tendon reflexes, pendular knee jerks, and ataxia. Per abdomen examination showed no organomegaly. Cardiovascular and respiratory system examination were within normal limits.

Ultrasound evaluation of the abdomen and the urinary tract was unremarkable. The axial T1-weighted (Figs. 1 and 2) magnetic resonance imaging (MRI) in all three patients showed thickened superior cerebellar peduncles that were oriented parallel to each other resulting in a “molar tooth” configuration. The more caudal T1-weighted (Fig. 3) axial MRI showed the fourth ventricle shaped such as a “bat-wing.” Dandy-Walker like malformation with vermian hypoplasia leading to a median approach of the two cerebellar hemispheres and an enlarged posterior fossa with a cerebrospinal fluid (CSF) collection was also noted. The fastigium was rostrally deviated (Fig. 4) in the three siblings. Based on the clinical and MRI findings, a diagnosis of JS was made and the parents were counseled accordingly.

DISCUSSION

JS, estimated to affect between 1 in 80,000 and 1 in 100,000 newborns, is characterized by decreased muscle tone, difficulties with coordination, abnormal breathing pattern, developmental delay, and intellectual disability [1,3]. When the characteristic features of JS occur in combination with kidney disease, liver disease, skeletal abnormalities such as polydactyly and endocrine

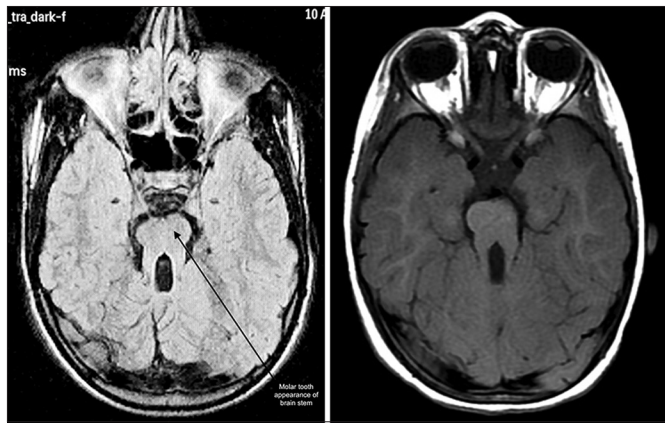


Figure 1&2: Axial T1-weighted images showing the “molar tooth sign”

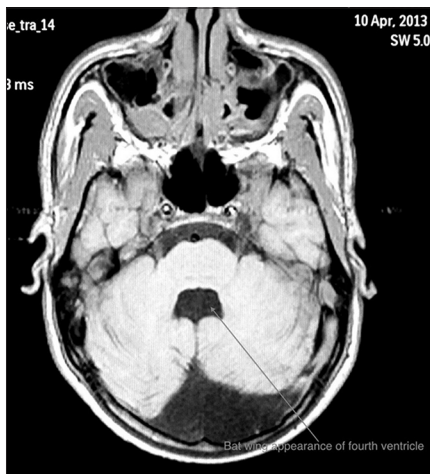

Figure 3: Axial T1-weighted image showed “bat-wing” appearance of the fourth ventricle

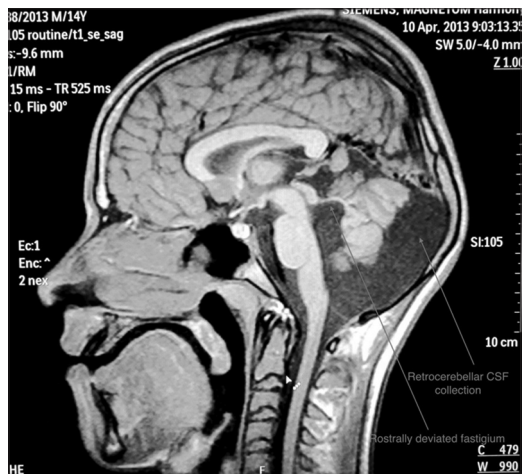


Figure 4: Sagittal T1-weighted image showing the rostrally deviated fastigium and a retrocerebellar cerebrospinal fluid collection

problems, the term JS and related disorders (JSRD) is used [4]. Most of the cases of JS are inherited in an autosomal recessive manner. Rare cases of X-linked recessive inheritance have also been reported. Till date, 19 genes including *NPHP1*, *AH11*, *CEP290*, *RPGRIP1L*, *TMEM67/MKS3*, *ARL13B*, and *CC2D2A* have been implicated in the causation of JSRD [4]. JSRD is the part of the group of disorders labeled as “ciliopathies,” caused by dysfunction of cilia [5]. Disruption of ciliary function likely

explains the involvement of the brain, kidney, and liver along with visual, auditory, and olfactory problems in individuals with JSRD. The genetic etiology could not be ascertained in our cases due to the technical difficulties involved in studying the possible mutations in the large number of causative genes and its financial implications.

Owing to the heterogeneity of presentation of JSRD, diagnosis depends on the MRI findings that are virtually diagnostic [6]. There is elongation and thickening of superior cerebellar peduncles and a deep interpeduncular fossa due to non-decussation of the superior cerebellar peduncle [7]. These give rise to the “molar tooth sign” (MTS) on axial MRI images [6,7] and was exquisitely depicted in all three cases reported here. There is partial or complete vermian agenesis, leading to a midline cleft between the normal appearing cerebellar hemispheres. Dilatation and rostral deviation of the fourth ventricle give rise to the “bat-wing” appearance, also noted in all three siblings. The size of the posterior fossa is variable. In all of the three cases reported here, the posterior fossa was enlarged with an increased retrocerebellar CSF collection. A wide range of other central nervous system malformations have been described in association with the MTS [3] namely hydrocephalus, corpus callosum dysgenesis, white matter cysts, hypothalamic hamartomas and absence of the pituitary gland, periventricular nodular heterotopia, cortical organization defects, and meningoencephalocele. These were however not seen in our cases.

CONCLUSIONS

This case report is perhaps the only report of all three siblings being affected in the family which is unusual given its autosomal recessive inheritance but may be explained due to the presence of second-degree consanguinity. It highlights the difficulty in clinically diagnosing this rare disease and the role of MRI in establishing the diagnosis where genetic studies are not readily available.

REFERENCES

1. Joubert M, Eisenring JJ, Robb JP, Andermann F. Familial agenesis of the cerebellar vermis: A syndrome of episodic hyperpnea, abnormal eye movements, ataxia, and retardation 1969. *J Child Neurol.* 1999;14(9):554-64.
2. Available from: <http://www.who.int/growthref/tools/en>. [Last accessed on 2015 May 31].
3. Brancati F, Dallapiccola B, Valente EM. Joubert syndrome and related disorders. *Orphanet J Rare Dis.* 2010;5:20.
4. Valente EM, Dallapiccola B, Bertini E. Joubert syndrome and related disorders. *Handb Clin Neurol.* 2013;113:1879-88.
5. Badano JL, Mitsuma N, Beales PL, Katsanis N. The ciliopathies: An emerging class of human genetic disorders. *Annu Rev Genomics Hum Genet.* 2006;7:125-48.
6. Sturm V, Leiba H, Menke MN, Valente EM, Poretti A, Landau K, et al. Ophthalmological findings in Joubert syndrome. *Eye (Lond).* 2010;24(2):222-5.
7. Poretti A, Huisman TA, Scheer I, Boltshauser E. Joubert syndrome and related disorders: Spectrum of neuroimaging findings in 75 patients. *AJNR Am J Neuroradiol.* 2011;32(8):1459-63.

Funding: None; Conflict of Interest: None Stated.

How to cite this article: Bhattacharjee S, Kalra S, Sinha P, Chatterjee S. Joubert syndrome: Case report of three affected siblings. *Indian J Child Health* 2017; 4(2):282-283.