

Valvular heart disease after scorpion sting in a child - A case report

Arun Prasad¹, Sanjeev Kumar², Anil Kumar³, Neelam Kumari⁴

From Departments of ¹Pediatrics (Trauma & Emergency) and ²Cardiothoracic & Vascular Surgery, All India Institute of Medical Sciences, ⁴Department of Biochemistry, Patna Medical College Hospital, Patna, Bihar; ³Department of Anaesthesiology, Institute of Medical Sciences, Varanasi, Uttar Pradesh, India

Correspondence to: Arun Prasad, Department of Pediatrics (Trauma and Emergency), All India Institute of Medical Sciences, Phulwari Sharif, Patna - 801 507, Bihar, India. Phone: +91-9472140820. E-mail: drarunpd@gmail.com

Received - 31 January 2017

Initial Review - 27 February 2017

Published Online - 14 April 2017

ABSTRACT

Myocarditis is a life-threatening complication of scorpion sting envenomation, and the victims who survive after this injury have normal cardiac function without any residual valvular lesion unlike acute rheumatic fever which causes residual valvular disease by thickening and scarring. We report here a case of a 9-year-old girl who was detected to have valvular heart disease, 2 months after she had scorpion sting envenomation.

Key words: Cardiac valvular lesion, Myocarditis, Scorpion sting

The most common cause of acquired heart disease in children and adolescents is valvular thickening and scarring developing after acute rheumatic fever. Valvular incompetence developing in some cases of scorpion sting myocarditis improves to normal within 5 days [1]. Scorpion stings are widespread in tropical and subtropical regions. This accident is common in rural areas, and numerous envenomations are unreported. Among 86 species of scorpion in India, *Mesobuthus tamulus* and *Palamneus swammerdami* are of medical importance [2].

Scorpion sting causes a wide range of manifestations from local skin reaction to neurological, respiratory, and cardiovascular collapse. Cardiovascular effects are particularly prominent after sting by Indian red scorpion (*M. tamulus*) [3]. Residual valvular heart disease in patients of scorpion sting myocarditis has not been reported so far on long-term follow-up. We are reporting a case here, who was found to have cardiac valvular lesions, 2 months after scorpion sting.

CASE REPORT

A 9-year-old girl reported in our outpatient department with complaints of dyspnea on exertion for 10 days. She was apparently well before appearance of this symptom. Her history revealed that she had scorpion sting 2 months ago, and she was admitted in a medical college hospital with sweating and cold extremities. Scorpion was identified and killed after the sting. On the basis of history and clinical examination, she was diagnosed to have scorpion sting myocarditis. Echocardiography was not done during this admission. She improved with conservative treatment with oral prazosin and dobutamine infusion and discharged after

5 days of admission. At the time of discharge, cardiac and other systemic examination was normal. She was asymptomatic for 2 months after discharge after which she was brought in our department with above-mentioned complaint of dyspnea on exertion. There was no history of joint pain, joint swelling, and abnormal movement or behavior.

On clinical examination, there was no pallor, lymphadenopathy, or edema. Jugular venous pressure was normal. Chest was clear and cardiovascular system revealed grade III mid-diastolic murmur at apex. There was no growth in throat swab culture, and C-reactive protein, antistreptolysin O (ASO) titer, and electrocardiogram were normal. Echocardiography showed thick cusps of mitral valves (Fig. 1) and aortic valves. These valvular lesions were causing moderate mitral stenosis, mild mitral regurgitation, and mild aortic regurgitation without aortic stenosis. Left ventricular ejection fraction was normal (65%). She was put on mild diuretics for congestive heart failure and showed improvement in her symptoms. Balloon mitral valvulotomy further improved her symptoms.

DISCUSSION

Cardiac complications are important cause of mortality in patients with a scorpion sting. The venom causes myocarditis with resultant reduced ventricular systolic function leading to shock and pulmonary edema which may terminate in fatal consequences. Those who recover with cardiac complications show improvement in left ventricular ejection fraction to normal. Adrenergic myocarditis, toxic myocarditis, and myocardial ischemia are the three mechanisms that explain the cardiac dysfunction. The cardiac damage can be due to or enhanced by the depressive effect of the cytokines on the myocardial cells.

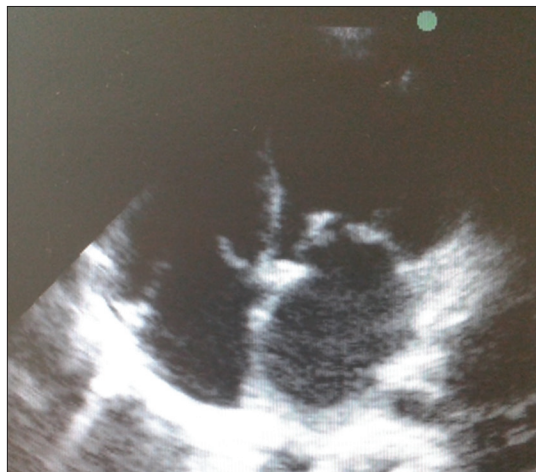


Figure 1: Thickened mitral valve noted after scorpion sting

The frequently observed hyperglycemia worsens the state of the already damaged myocardium [4].

Case fatality rates of 3-22% were reported among children hospitalized for scorpion stings in India, Saudi Arabia, and South Africa [5-9]. Chandra et al. studied 21 cases of acute severe myocarditis due to scorpion sting envenomation in children with follow-up echocardiography for 6 months. Two cases were died, and out of 19 cases who survived, 3 cases showed transient mitral incompetence which was normalized on the 5th day. By the end of 1 month, all the survivors had normal ventricular ejection fraction. No residual cardiac dysfunction or valvular lesion was observed at 6 months [1]. Valvular lesion following scorpion sting has not been reported so far in any available literatures. The inflammation of endocardium due to the effect of venom with subsequent healing by scarring in some patients could be the possible etiopathogenesis for valvular lesions observed in this case reported here. Although this patient had no history of joint pain or sore throat, ASO titer was negative and cardiovascular examination during initial hospital admission was normal without any clinical evidence of valvular affection; there could be a possibility that these valvular lesions were missed earlier during clinical examination, which has increased in severity by the time she reported to us.

Various larger studies involving school children estimated the prevalence of rheumatic heart disease ranging from 0.68 to 2.9/1000 India [10-12]. Larger studies by echocardiographic follow-up in survivors of scorpion sting victims might reveal whether there is any relationship of cardiac complications of scorpion sting and development of residual valvular heart disease. If any relationship is found, a course of steroid could be helpful in preventing the complications of residual valvular disease. It can be

used after initial stabilization, as it might worsen hyperglycemia which is common with scorpion sting envenomation.

CONCLUSION

Scorpion sting envenomation usually has a good prognosis but occasionally a potentially fatal complication, myocarditis can occur. Those who recover from myocarditis usually regain normal cardiac function without any valvular involvement. The detection of valvular lesions in the reported case here could be a matter of further research involving echocardiography of a sizable number of survivors of scorpion sting myocarditis to reveal whether there is any association between scorpion sting myocarditis and cardiac valvular lesions.

REFERENCES

1. Kumar CM, Prasad SV. Echocardiologic evaluation and follow-up of cardiovascular complications in children with scorpion sting in coastal South India. *Indian J Crit Care Med.* 2015;19(1):42-6.
2. Erfati P. Epidemiology, symptomatology and treatment of buthinae stings. In: Bettini S, editor. *Handbook of Experimental Pharmacology.* New York: Springer-Verlag; 1978. p. 312-5.
3. Bawaskar HS, Bawaskar PH. Indian red scorpion envenoming. *Indian J Pediatr.* 1998;65(3):383-91.
4. Bahloul M, Kallel H, Rekik N, Ben Hamida C, Chelly H, Bouaziz M. Cardiovascular dysfunction following severe scorpion envenomation. Mechanisms and pathophysiology. *Presse Med.* 2005;34:115-20.
5. Rajarajeswari G, Sivaprakasam S, Viswanathan J. Morbidity and mortality pattern in scorpion stings. (A review of 68 cases). *J Indian Med Assoc.* 1979;73(7-8):123-6.
6. Mahadevan S, Choudhury P, Puri RK, Srinivasan S. Scorpion envenomation and the role of lytic cocktail in its management. *Indian J Pediatr.* 1981;48(395):757-61.
7. Biswal N, Charan MV, Betsy M, Nalini P, Srinivasan S, Mahadevan S. Management of scorpion envenomation. *Pediatr Today.* 1999;2:420-6.
8. Ismail M. The scorpion envenoming syndrome. *Toxicon.* 1995;33(7):825-58.
9. Müller GJ. Scorpionism in South Africa. A report of 42 serious scorpion envenomations. *S Afr Med J.* 1993;83(6):405-11.
10. Jose VJ, Gomathi M. Declining prevalence of rheumatic heart disease in rural schoolchildren in India: 2001-2002. *Indian Heart J.* 2003;55(2):158-60.
11. Grover A, Dhawan A, Iyengar SD, Anand IS, Wahi PL, Ganguly NK. Epidemiology of rheumatic fever and rheumatic heart disease in a rural community in northern India. *Bull World Health Organ.* 1993;71(1):59-66.
12. Thakur JS, Negi PC, Ahluwalia SK, Vaidya NK. Epidemiological survey of rheumatic heart disease among school children in the Shimla Hills of Northern India: Prevalence and risk factors. *J Epidemiol Community Health.* 1996;50(1):62-7.

Funding: None; Conflict of Interest: None Stated.

How to cite this article: Prasad A, Kumar S, Kumar A, Kumari N. Valvular heart disease after scorpion sting in a child - A case report. *Indian J Child Health.* 2017; 4(2):273-274.