

## Scrub typhus in children: Clinical profile and complications at a Tertiary Care Teaching Hospital in Uttarakhand

Shruti Kumar<sup>1</sup>, Mritunjay Kumar<sup>1</sup>, Bindu Aggarwal<sup>1</sup>, Rashmi Kumari<sup>2</sup>

From Departments of <sup>1</sup>Pediatrics and <sup>2</sup>Community Medicine, SGRR Institute of Medical and Health Sciences, Dehradun, Uttarakhand, India

**Correspondence to:** Dr. Mritunjay Kumar, Department of Pediatrics, SGRR Institute of Medical and Health Sciences, Patel Nagar, Dehradun - 248 001 Uttarakhand, India. Phone: +91-8193020304. E-mail: drmkumar409@gmail.com

Received – 02 February 2017

Initial Review – 27 February 2017

Published Online – 22 April 2017

### ABSTRACT

**Background:** Scrub typhus is an acute febrile illness caused by rickettsia *Orientia tsutsugamushi*. Rickettsial infections are grossly underdiagnosed in India because of their non-specific clinical presentation, low index of suspicion among clinicians, and lack of diagnostic facilities. **Objective:** Objective of the study is to study the clinical profile, complications, and outcome of pediatric scrub typhus. **Materials and Methods:** This prospective observational study was conducted in the Department of Pediatrics, SGRR Institute of Medical and Health Sciences, Dehradun, Uttarakhand, India, over a period of 2 years from November 2013 to October 2015. Children up to 18 years of age with signs and symptoms compatible with scrub typhus along with serological confirmation were included in the study. Serological study was conducted using rapid immunochromatographic assay and/or immunoglobulin M enzyme-linked immunosorbent assay technique. Clinical presentation, laboratory findings, complications, and outcome of these children were recorded on a performa. The data were analyzed using SPSS version 20 for windows. **Results:** About 115 children were diagnosed as scrub typhus during the study period. All children presented with fever. Other common symptoms were myalgia (56%), vomiting (50.5%), abdominal pain (26%), headache (28%), facial puffiness (15%), and seizures (8.7%). Pallor was present in 48% of children. Other common signs were hepatomegaly (29%), splenomegaly (28%), hypotension (24%), edema (21%), oliguria (17%), maculopapular rash (10%), meningeal signs (10.4%), and conjunctivitis (3%). Thrombocytopenia (67%), anemia (51%), pleural effusion (23%), shock (16%), hepatitis (23%), acute kidney injury (17%), meningoencephalitis (10%), myocarditis (7%), and acute respiratory distress syndrome (7%) were the complications observed. Azithromycin, doxycycline or chloramphenicol were used for the treatment. Overall mortality rate was 12.2%. **Conclusion:** A high degree of suspicion and knowledge of geographical distribution of rickettsial diseases is crucial for its early diagnosis and favorable outcome. The presence of an eschar is a valuable clinical clue in the diagnosis of scrub typhus; however, its absence does not rule out the disease.

**Key words:** Children, Complications, Rickettsial, Scrub typhus, Uttarakhand

Scrub typhus has now become the most commonly reported rickettsial infection from the Indian subcontinent. *Orientia tsutsugamushi*, the causative agent of scrub typhus is found in many parts of Asia including India. In the past few years, the number of cases of scrub typhus in India has increased; especially, during late rainy and early winter season of the year [1]. Scrub typhus and other rickettsial infections are grossly underdiagnosed in India because of their non-specific clinical presentation, low index of suspicion among clinicians, limited awareness about the disease and lack of diagnostic facilities. The clinical presentation of rickettsial diseases ranges from a mild, non-specific febrile syndrome to a life-threatening fatal condition.

They may mimic tropical febrile illnesses such as malaria, dengue fever, typhoid fever, and leptospirosis [2]. Delay in the diagnosis and initiation of appropriate treatment may result in severe complications such as acute respiratory distress syndrome (ARDS), septic shock, myocarditis, multi-organ failure, and death. Treatment must be initiated empirically in suspected

cases without awaiting laboratory confirmation, as morbidity and mortality escalate rapidly with each day of treatment delay. This study was conducted to evaluate the varying clinical profile, complications and outcome of serologically confirmed scrub typhus cases at a tertiary care teaching hospital of North India.

### MATERIALS AND METHODS

This prospective observational study was conducted in the Department of Pediatrics, SGRR Institute of Medical and Health Sciences, Dehradun, Uttarakhand, India, over a period of 2 years from November 2013 to October 2015. Prior approval from Institutional Ethics Committee was obtained. Children up to 18 years of age with signs and symptoms compatible with scrub typhus along with serological confirmation were included in the study. Children diagnosed and treated outside as scrub typhus before they presented to us were not included in the study. Serological study was carried out using rapid

immunochromatographic assay (RIA) and/or immunoglobulin M (IgM) enzyme-linked immunosorbent assay (ELISA) technique.

For RIA, one step scrub typhus test (SD *Tsutsugamushi* bioline kit from Standard Diagnostics, Inc., Hagal-Dong, Kyonggi-do, Korea, with a sensitivity of 99% and specificity of 96%) and for IgM ELISA test, (Scrub typhus detect TM IgM ELISA system, In BiOS International, Inc. Seattle, USA) was used. Rapid immunochromatographic test was carried out as a first line investigation for most of the children with a probable diagnosis of scrub typhus. Cases found positive on RIA were reconfirmed by IgM ELISA test. In some cases where history and clinical presentation was very much suggestive of scrub typhus, only IgM ELISA method was used to confirm the diagnosis. All IgM ELISA confirmed cases were enrolled in the study.

Clinical presentation, laboratory findings, complications, and outcome of these children were recorded on a performa. A careful search for eschar was performed in all patients. Data regarding age, sex, residence and history of going to fields were collected. Complete blood count, chest X-ray, tests for renal and liver function, urinalysis and serum electrolyte estimation were done. Peripheral smear and rapid antigen test for malaria, IgM typhidot test for enteric fever, dengue serology (nonstructural protein 1 antigen and IgM antibody), and blood/urine cultures were sent to rule out other infective conditions. Cardiac evaluation and cerebrospinal fluid (CSF) analysis was performed for selected cases with suspected myocarditis or meningoencephalitis, respectively. All children serologically confirmed as scrub typhus were treated with a 10 days course of antibiotics (doxycycline - 4 mg/kg/day, azithromycin - 10 mg/kg/day, or chloramphenicol - 100 mg/kg/day) [3,4]. The data were entered into Microsoft excel sheet and analyzed later using SPSS version 20 for Windows.

## RESULTS

A total of 115 children were diagnosed as scrub typhus during the study period. No obvious sex predilection was observed as there were 57 males in comparison to 58 females (male/female ratio was 0.98:1). The youngest patient of the cohort was 12 months and oldest was 18 years. Majority of the children (37.4%) were in the age group of 11-15 years. Mean age at presentation was found to be 10.63 years (standard deviation=4.934). 82 (71.3%) children belonged to the state of Uttarakhand while 33 (28.7%) children were referred from other states out of which majority were from western Uttar Pradesh (Table 1).

All children diagnosed with scrub typhus presented with fever. Myalgia was the second most predominant symptom found in 64 (55.6%) children. 57 (49.6%) presented with <7 days of fever while 48 (41.7%) had fever of 7-13 days duration. A significant 8 children (7%) presented with fever of >14 days duration. Vomiting was present in 58 (50.5%) children and abdominal pain was a major concern in 30 (26.1%). Headache was complained by 33 (28.7%) children and 21 (18.1%) had altered sensorium. Other symptoms reported were breathlessness, facial puffiness, seizures, rash, jaundice, joint pain, oliguria, bleeding, lymphadenopathy, and conjunctivitis (Table 2).

**Table 1: Demographic data of pediatric scrub typhus cases (n=115)**

Characteristics	n (%)
Gender	
Male	57 (49.6)
Female	58 (50.4)
Age (years)	
<5	19 (16.5)
5-10	31 (27.0)
11-15	43 (37.4)
>16	22 (19.1)
Residence	
Uttarakhand	82 (71.3)
Outside Uttarakhand	33 (28.7)
History of going to fields	
Yes	11 (9.6)
No	104 (90.4)

**Table 2: Clinical profile of children with scrub typhus (n=115)**

Symptoms and Signs	n (%)
Symptoms	
Fever (days)	
<7	57 (49.6)
7-13	48 (41.7)
14-29	8 (7.0)
>30	2 (1.7)
Myalgia	64 (55.6)
Vomiting	58 (50.5)
Headache	33 (28.7)
Abdominal pain	30 (26.1)
Breathlessness	28 (24.3)
Seizures	10 (8.7)
Altered sensorium	21 (18.1)
Facial puffiness	17 (14.8)
Bleeding	4 (3.5)
Joint pain	3 (2.6)
Signs	
Pallor	54 (47.8)
Hepatomegaly	33 (28.7)
Splenomegaly	32 (27.8)
Icterus	14 (12.2)
Rash	11 (9.6)
Petechiae/purpura	2 (1.7)
Eschar	2 (1.7)
Oliguria	20 (17.4)
Hypotension	28 (24.3)
lymphadenopathy	5 (4.3)
Conjunctivitis	3 (2.6)
Meningeal signs	12 (10.4)
Ascites	6 (5.2)
Unconsciousness	17 (14.8)
Edema	25 (21.7)

The most interesting observation in our study was the absence of eschar in almost all the cohorts of scrub typhus barring 2 cases. Even rash was present only in 11 (9.6%) children. Pallor, hepatomegaly and splenomegaly were the major clinical finding observed in 55 (47.8%), 33 (28.7%) and 32 (27.8%) of children, respectively. 28 (24.3%) developed hypotension either at initial presentation or during further stay. 11 children (9.6%) had a history of going to fields before they presented to us.

On investigations, anemia (hemoglobin <11 g %) was present in 59 (51.3%) children while thrombocytopenia (platelet <1.5 lac/mm<sup>3</sup>) was there in 77 (67%) children. Out of these, 40 children (34.8%) had platelet count between 50,000 and 100,000/mm<sup>3</sup> while 25 (21.7%) had severe thrombocytopenia (platelets <50,000/mm<sup>3</sup>). Leukocytosis (total leukocyte count [TLC] >11,000/mm<sup>3</sup>) was present in 44 (38.3%) while 11 (9.6%) children had leukopenia (TLC <4000/mm<sup>3</sup>). 26 children (22.6%) had complete derangement of liver function, and isolated transaminitis was present in significant number of the children (54 [47%] with high serum glutamic-pyruvic transaminase and 40 [34.8%] with high serum glutamic oxaloacetic transaminase). Hypoalbuminemia (serum albumin <3 g/dl) was found in 48 (41.7%) children. 23 (20%) children had azotemia (serum creatinine >1 mg/dl) and 20 (17.4%) of them developed acute kidney injury (AKI). 16 children with AKI were managed conservatively and 4 required renal replacement therapy.

Respiratory failure was one of the major complications observed in 18 (15.7%) children and all of them required ventilator support. Mean ventilation days was 2.7 days. Pleural effusion was noted in 27 (23.4%) children and 9 (7.8%) had bronchopneumonia. ARDS developed in 8 (6.9%) children and were a significant contributor to the overall mortality. 18 (15.6%) children had shock either as initial presentation or during the pediatric intensive care unit stay and 12 (10.4%) of them required inotropes. Lumbar puncture was done in 20 (17.4%) children and 12 (10.4%) of them had CSF findings consistent with meningoencephalitis. 10 (8.7%) children had seizures during their disease course and 2 of them developed status epilepticus. 8 (7%) children with scrub typhus were found to have coinfection with malaria (3 for *Plasmodium vivax* and 5 for *Plasmodium falciparum*). One child had dengue coinfection. Other complications noted were myocarditis, ascites, glomerulonephritis, gastroenteritis, epistaxis, peritonitis, febrile seizures, acute fulminant liver failure, and disseminated intravascular coagulation (DIC) (Fig. 1).

Azithromycin, doxycycline, and chloramphenicol were used for the treatment. Azithromycin was used in 46 (40%) children while doxycycline was used in 32 (27.8%) children. 25 (21.7%) children were given a combination of both the drugs as these were not responding to single drug. Chloramphenicol was used in 12 (10.4%) children. The mean duration from admission to defervescence was 2.8 days; however, subjective improvement was documented within 48 h in most of the children. Overall mortality rate in our study was 12.2%. All these children had refractory shock. Other contributors were ARDS, myocarditis, encephalitis, DIC, acute fulminant liver failure, and multiorgan dysfunction.

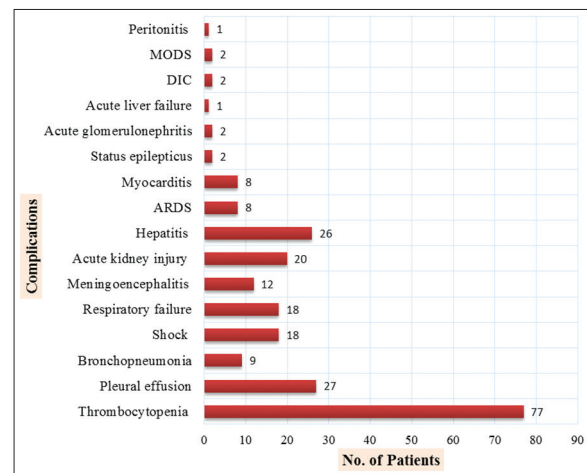


Figure 1: Complications of scrub typhus (n=115)

## DISCUSSION

There have been reports of the outbreaks of scrub typhus from various parts of the country in the recent past. This study was one of the largest prospective studies carried out over a period of 2 years in a tertiary care referral hospital. *O. tsutsugamushi*, the causative agent of scrub typhus is transmitted to humans through the bite of an infected chigger, the larval stage of trombiculid mite [5]. The bacteria multiply at the inoculation site with the formation of a papule that ulcerates and becomes necrotic. Later, it evolves into an eschar with regional lymphadenopathy that may progress to generalized lymphadenopathy within few days. Vasculitis is the basic pathogenic mechanism in scrub typhus. It is responsible for the skin rash, microvascular leakage, edema, tissue hypoperfusion, and end organ ischemic injury [6].

In this study, most of the children belonged to the state of Uttarakhand and a large majority were from neighboring western Uttar Pradesh. The mean age at presentation was 10.63 years, and our observations were a bit different from others [7,8]. Majority of the cases were diagnosed between the months of September and November, which follow the rainy monsoon season and coincide with the peak growth of secondary scrub vegetations and mite population [9]. Similar observations were reported in many other studies [10,11]; although, a study from Taiwan found the greatest number of cases between May and August [12].

Scrub typhus presents as an acute febrile illness with non-specific signs and symptoms. Fever was documented in all children in this study similar to observations by Digra et al. and Kumar Bhat et al. [7,10]. Myalgia was the most common association with fever, which was similar to many previous reports [13,14]. 11 children had a history of going to fields and only 2 had history of any bite before they presented to us. The most remarkable observation in our study was almost complete absence of eschar, once considered as one of the pathognomonic features of scrub typhus. Only 2 children had eschar at the time of admission. Eschar is a black necrotic lesion resembling a cigarette burn, usually found in areas where skin is thin, moist or wrinkled and where the clothing is tight such as axilla, genitalia, and inguinal area [7]. Review of literature suggests wide variations



in observations for the presence or absence of eschar in children with scrub typhus. Some authors have reported eschar in 50-80% of cases [15-17], while others did not find an eschar in any of their cases [18,19].

Vomiting and headache were predominant symptoms in 51% and 29% of children, respectively. Abdominal pain (26%), breathlessness (24%), and seizures (8.7%) were other common symptoms in our study. Lymphadenopathy has been reported in 18% to 62% of cases in many previous studies [8,20]. In our study, it was observed only in 10% of cases. Pallor was present in 47.8% of cases which could not be explained by the disease per se and probably, it reflected the poor nutritional status and rural background of our study population. Hepatomegaly and splenomegaly were observed in 28.7% and 27.8%, respectively. The presence of splenomegaly is an important sign to distinguish scrub typhus from dengue fever as splenomegaly is uncommon in the latter.

Thrombocytopenia was the major laboratory finding observed in the present study and it was present in 67% cases. Similar observations were reported by Palanivel et al. (77%), Jain and Jain (68.4%), and Kumar Bhat et al. (53%). Thrombocytopenia was not associated with an elevated hematocrit, a valuable clue which helps to differentiate scrub typhus from dengue fever. Similar to many other case series [15,17], most of the patients had elevation of serum transaminases, even without any other evidence of multiorgan dysfunction. Other laboratory findings noted were leukocytosis and low serum albumin. While low serum albumin and leukocytosis are thought to be associated with severe scrub typhus [21], these findings need to be validated in a large sample.

Serious complications of scrub typhus usually occur in the 2<sup>nd</sup> week of illness which includes ARDS, pneumonia, meningoencephalitis, AKI, GI bleeding, and severe thrombocytopenia [1]. Thrombocytopenia was the most common complication observed in our study (Fig. 1). Pleural effusion (23.4%) and bronchopneumonia (7.8%) were other notable complications and associated with significant morbidity. Palanivel et al. had similar observations. However, meningoencephalitis was the most common complication observed by Kumar Bhat et al., while in the present study, 10.4% children had meningoencephalitis. Hepatitis and AKI were the other common complications and observed in 22.6% and 17.4% cases, respectively. Hepatitis had been reported in 13-80% of cases in different studies [7,14].

Rickettsial infections have often been overlooked as a cause of AKI, especially in children. It can be a presenting feature of rickettsial disease and is associated with a bad prognosis [4]. Three previous studies based on pediatric scrub typhus have reported lower incidences of AKI ranging from 2% to 10% [7,22], whereas another study from South India has reported a higher frequency of 20% [8]. AKI that is caused by acute tubular necrosis is a result of direct invasion by *O. tsutsugamushi* [23]. Both ARDS and myocarditis were reported in 7% of the study population. A study from South India has reported 34% incidence of myocarditis [8].

15.7% of children in this study developed respiratory failure and needed assisted ventilation. As our center is a tertiary referral center, there was considerable referral bias and it led to higher complication rates.

The mainstay of scrub typhus diagnosis and of epidemiology studies is serologic testing. The gold standard for the serologic detection of scrub typhus antibodies is indirect immunofluorescence assay [4,24]. As most of our study population belonged to low socioeconomic status, we could not consider IFA as a diagnostic method due to its high cost and non-availability. The cheapest test currently available and used extensively is Weil-Felix test which is highly specific, but lacks sensitivity [25]. We used RIA and/or ELISA for IgM antibodies against *O. tsutsugamushi*. RIA was the only diagnostic test available at our institute for the diagnosis of Scrub typhus. Therefore, it was used as a first line investigation for most of the cases where scrub typhus was a probability. As most of the recent guidelines do not recommend RIA as a confirmatory test [4], we outsourced IgM ELISA test for confirmation of positive RIA results. Although in some children where history and clinical presentation was very much in favor of scrub typhus, IgM ELISA was used straightaway as confirmatory test. ELISA for IgM antibodies against *O. tsutsugamushi* has shown good sensitivity and specificity and it has been adequately validated [26].

The study patients were treated with azithromycin, doxycycline or chloramphenicol. Azithromycin was preferred drug in children <8 years age group while doxycycline was considered in older children [13]. Doxycycline is bacteriostatic to *O. tsutsugamushi* and does not cross the blood-brain barrier (BBB) beyond 15-30% [27]. Chloramphenicol being a bactericidal drug with better BBB penetration was preferred in cases complicated with meningoencephalitis [13]. Rickettsial strains with reduced susceptibility to doxycycline were reported, and alternative drugs can be used in such situation [28]. The response to doxycycline is dramatic and fever persisting beyond 48 h of initiation of doxycycline should prompt consideration of alternative or additional diagnosis, including coinfection [29]. Alternative effective drugs are macrolides (oral clarithromycin or oral/intravenous azithromycin), chloramphenicol, and rifampicin. We added azithromycin to doxycycline in cases where there was poor response to doxycycline alone and possibility of doxycycline resistance was high [30]. A recent Cochrane meta-analysis found no difference in efficacy between doxycycline and azithromycin in treating scrub typhus [31]. Rifampicin has been found useful in cases not responding to doxycycline or azithromycin [32]. The mortality rate in this study was 12.2% which was comparable to Palanivel et al. and Kamarasu et al., who reported mortality in 12% and 15%, respectively [1,19].

There were few limitations in our study. This study was conducted at a tertiary referral hospital; therefore, it could not reflect the actual burden of scrub typhus in the community. RIA and IgM ELISA were used for serological diagnosis as very high cost and availability was the limiting factor for indirect immunofluorescence assay. Availability of an affordable, readily

available, and reliable diagnostic test for scrub typhus targeted on local population is the need of the hour. Further research must focus on preventive strategy against scrub typhus including vector control and availability of a vaccine in the near future. Even if suspected by clinician, therapy is empirical as serological tests for diagnosis become positive around a week after onset of fever and early diagnostic test like polymerase chain reaction is not freely available.

## CONCLUSION

A clear knowledge of geographical distribution and compatible clinical scenarios of rickettsial disease is crucial for its early diagnosis and favorable outcome. A probable diagnosis of scrub typhus must be considered in children presenting with acute unspecified febrile illness with maculopapular rash, hepatosplenomegaly, lymphadenopathy, thrombocytopenia, and features of capillary leak. Although eschar is pathognomonic of the disease, its absence does not rule out scrub typhus.

## REFERENCES

- Palanivel S, Nedunchelian K, Poovazhagi V, Raghunadan R, Ramachandran P. Clinical profile of scrub typhus in children. *Indian J Pediatr.* 2012;79(11):1459-62.
- Hamaguchi S, Cuong NC, Tra DT, Doan YH, Shimizu K, Tuan NQ, et al. Clinical and epidemiological characteristics of scrub typhus and murine typhus among hospitalized patients with acute undifferentiated fever in Northern Vietnam. *Am J Trop Med Hyg.* 2015;92(5):972-8.
- DHR-ICMR Guidelines for Diagnosis and Management of Rickettsial Diseases in India. Available from: <http://www.icmr.nic.in/guide/DHR-ICMRGuidelinesonRickettsialdiseases.pdf>. [Last accessed on 2017 Apr 06].
- Rathi N, Kulkarni A, Yewale V; For Indian Academy of Pediatrics Guidelines on Rickettsial Diseases in Children Committee. IAP Guidelines on Rickettsial Diseases in Children. *Indian Pediatr.* 2017;54(3):223-9.
- Reller ME, Dumler JS. Scrub typhus (*Orientia tsutsugamushi*). In: Kleigman RM, Stanton BF, Geme JW, Schor NF, editors. *Nelson Textbook of Pediatrics*. 19<sup>th</sup> ed. Philadelphia, PA: Elsevier; 2011. p. 1045-6.
- Rathi N, Rathi A. Rickettsial infections: Indian perspective. *Indian Pediatr.* 2010;47(2):157-64.
- Kumar Bhat N, Dhar M, Mittal G, Shirazi N, Rawat A, Prakash Kalra B, et al. Scrub typhus in children at a tertiary hospital in north India: Clinical profile and complications. *Iran J Pediatr.* 2014;24(4):387-92.
- Kumar M, Krishnamurthy S, Delhikumar CG, Narayanan P, Biswal N, Srinivasan S. Scrub typhus in children at a tertiary hospital in southern India: Clinical profile and complications. *J Infect Public Health.* 2012;5(1):82-8.
- Meena M, Meena S. Chiggerosis: An emerging disease. *Int J Res Med Sci.* 2016;4(10):4236-40.
- Digra SK, Saini GS, Singh V, Sharma SD, Kaul R. Scrub typhus in children: Jammu experience. *JK Sci.* 2010;12(2):95-7.
- Somashekar HR, Moses PD, Pavithran S, Mathew LG, Agarwal I, Rolain JM, et al. Magnitude and features of scrub typhus and spotted fever in children in India. *J Trop Pediatr.* 2006;52(3):228-9.
- Huang CT, Chi H, Lee HC, Chiu NC, Huang FY. Scrub typhus in children in a teaching hospital in eastern Taiwan, 2000-2005. *Southeast Asian J Trop Med Public Health.* 2009;40(4):789-94.
- Jain N, Jain V. Study on clinico - Laboratory profile of children with scrub typhus. *J Nepal Paediatr Soc.* 2012;32(2):187-92.
- Narvencar KP, Rodrigues S, Nevrekar RP, Dias L, Dias A, Vaz M, et al. Scrub typhus in patients reporting with acute febrile illness at a tertiary health care institution in Goa. *Indian J Med Res.* 2012;136(6):1020-4.
- Krishna MR, Vasuki B, Nagaraju K. Scrub typhus: Audit of an outbreak. *Indian J Pediatr.* 2015;82(6):537-40.
- Lee CS, Min IS, Hwang JH, Kwon KS, Lee HB. Clinical significance of hypoalbuminemia in outcome of patients with scrub typhus. *BMC Infect Dis.* 2010;10:216.
- Vivekanandan M, Mani A, Priya YS, Singh AP, Jayakumar S, Purty S. Outbreak of scrub typhus in Pondicherry. *J Assoc Physicians India.* 2010;58:24-8.
- Mahajan SK, Rolain JM, Sankhyan N, Kaushal RK, Raoult D. Pediatric scrub typhus in Indian Himalayas. *Indian J Pediatr.* 2008;75(9):947-9.
- Kamarasu K, Malathi M, Rajagopal V, Subramani K, Jagadeeshramasamy D, Mathai E. Serological evidence for wide distribution of spotted fevers and typhus fever in Tamil Nadu. *Indian J Med Res.* 2007;126(2):128-30.
- Silpapojakul K, Varachit B, Silpapojakul K. Paediatric scrub typhus in Thailand: A study of 73 confirmed cases. *Trans R Soc Trop Med Hyg.* 2004;98(6):354-9.
- Kim DM, Kim SW, Choi SH, Yun NR. Clinical and laboratory findings associated with severe scrub typhus. *BMC Infect Dis.* 2010;10:108.
- Kulkarni A, Vaidya S, Kulkarni P, Bidri LH, Padwal S. Rickettsial disease-an experience. *Pediatr Infect Dis.* 2009;1(3):118-24.
- Kim DM, Kang DW, Kim JO, Chung JH, Kim HL, Park CY, et al. Acute renal failure due to acute tubular necrosis caused by direct invasion of *Orientia tsutsugamushi*. *J Clin Microbiol.* 2008;46(4):1548-50.
- Blacksell SD, Bryant NJ, Paris DH, Doust JA, Sakoda Y, Day NP. Scrub typhus serologic testing with the indirect immunofluorescence method as a diagnostic gold standard: A lack of consensus leads to a lot of confusion. *Clin Infect Dis.* 2007;44(3):391-401.
- Mahajan SK, Kashyap R, Kanga A, Sharma V, Prasher BS, Pal LS. Relevance of Weil-Felix test in diagnosis of scrub typhus in India. *J Assoc Physicians India.* 2006;54:619-21.
- Koh GC, Maude RJ, Paris DH, Newton PN, Blacksell SD. Diagnosis of scrub typhus. *Am J Trop Med Hyg.* 2010;82(3):368-70.
- Viswanathan S, Muthu V, Iqbal N, Remalayam B, George T. Scrub typhus meningitis in South India - a retrospective study. *PLoS One.* 2013;8:e66595.
- Liu Q, Panpanich R. Antibiotics for treating scrub typhus. *Cochrane Database Syst Rev.* 2002;3:CD002150.
- Biggs HM, Behravesh CB, Bradley KK, Dahlgren FS, Drexler NA, Dumler JS, et al. Diagnosis and management of tickborne rickettsial diseases: Rocky mountain spotted fever and other spotted fever group rickettsioses, ehrlichioses, and anaplasmosis - United States. *MMWR Recomm Rep.* 2016;65(2):1-44.
- Rajapakse S, Rodrigo C, Fernando SD. Drug treatment of scrub typhus. *Trop Doct.* 2011;41(1):1-4.
- Liu Q, Panpanich R. Antibiotics for treating Scrub typhus. *Cochrane Database Syst Rev.* 2010;7:CD002150.
- Watt G, Kantipong P, Jongsakul K, Watcharapichat P, Phulsuksombati D, Strickman D. Doxycycline and rifampicin for mild scrub-typhus infections in Northern Thailand: A randomised trial. *Lancet.* 2000;356(9335):1057-61.

Funding: None; Conflict of Interest: None Stated.

**How to cite this article:** Kumar S, Kumar M, Aggarwal B, Kumari R. Scrub typhus in children: Clinical profile and complications at a Tertiary Care Teaching Hospital in Uttarakhand. *Indian J Child Health.* 2017; 4(2):188-192.