

## *Pentatrichomonas hominis* in an immunosuppressed patient with enteric manifestations

Rumpa Saha<sup>1</sup>, Archana Singal<sup>2</sup>, Stuti Kaushik<sup>1</sup>, Shukla Das<sup>1</sup>

From Departments of <sup>1</sup>Microbiology, <sup>2</sup>Dermatology & STD, University College of Medical Sciences and Guru Teg Bahadur Hospital, Dilshad Garden, New Delhi, India

**Correspondence to:** Rumpa Saha, Department of Microbiology, University College of Medical Sciences and Guru Teg Bahadur Hospital, Dilshad Garden, New Delhi - 110095, India. Phone: +91-9953007273. E-mail: rumpachatterjee@yahoo.co.in

Received – 15 April 2017

Initial Review – 05 May 2017

Published Online – 25 May 2017

### ABSTRACT

*Pentatrichomonas hominis* is a flagellated protozoa considered to be a commensal that inhabits caecum and large intestine in man. It is regarded to be non-pathogenic, however, it has been postulated that these trichomonads undergo multiplication under favorable conditions for growth and exhibit a form of opportunism eventually causing diarrhea. We report, for the first time in India, a case of diarrhea due to *P. hominis* in an elderly male with myeloid malignancy that resolved on treatment with metronidazole.

**Key words:** Diarrhea, Metronidazole, *Pentatrichomonas hominis*

Trichomonads are flagellated protozoa. Four species, namely, *Dientamoeba fragilis*, *Pentatrichomonas hominis*, *Trichomonas vaginalis*, and *Trichomonas tenax* are specifically found in human hosts. *T. vaginalis* is the only member that holds an established pathogenic potential for humans and contributes to a majority of cases of non-viral sexually transmitted infections [1]. *T. tenax* has been recovered from the human oral cavity in periodontal infections and some chronic pulmonary illnesses [2]. *Dientamoeba fragilis* has been reported from stool samples of patients presenting with gastrointestinal disturbances and a possible link with irritable bowel syndrome has been put forward in recent times [3]. In the past three decades, *P. hominis* has been reported to be a prospective cause of diarrheal illness, particularly in children [4].

### CASE REPORT

We present a case of diarrhea due to *P. hominis* in our tertiary care hospital in Delhi. A 60-year-old cachectic male from the neighboring state of Uttar Pradesh was admitted in dermatology inpatient, with generalized fluid filled lesions of 3 days duration. He developed these lesions 3-4 days after taking antimalarial treatment along with norfloxacin and cefixime from emergency for fever, vomiting, and pain abdomen. He was running intermittent high-grade fever and anorexia with unintended weight loss (7-8 kg) in past 2 months.

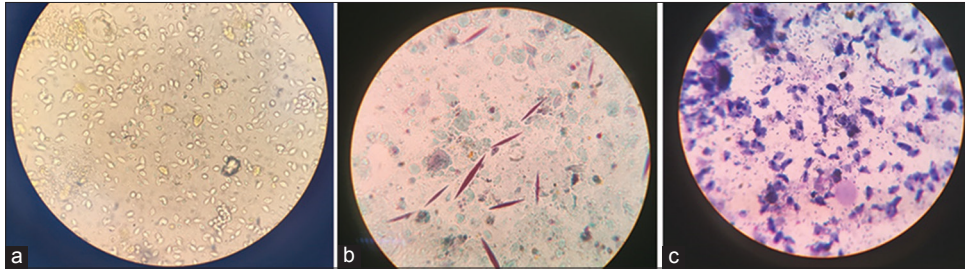
Hematological examination revealed moderate anemia, thrombocytopenia, neutropenia, and significant eosinophilia. Large numbers of trophozoites of trichomonas were detected on stool examination. Hepatosplenomegaly along with retroperitoneal and mesenteric lymphadenopathy was detected on ultrasonography

abdomen. Fine needle aspiration cytology axillary lymph nodes showed atypical cells in a reactive background with numerous neutrophils and eosinophils. Due to moderate anemia, bone marrow examination was done that depicted presence of dysplastic cells with increased number of monocytes and immature blood cells. A final diagnosis of drug-induced toxic epidermal necrolysis with myeloid malignancy was made.

During the hospital stay, he developed acute onset diarrhea (6-8 episodes/day) associated with colicky abdominal pain. A stool sample was sent to the enterobacteriaceae and parasitology laboratory of the microbiology department for routine examination and culture sensitivity. The sample was pale brown to yellowish in color, watery in consistency, not associated with blood or mucus and had a foul odor. No adult worm segments were seen.

Routine microscopy was done after preparation of wet mount in normal saline and Lugol's iodine. More than 100 pear shaped motile trophozoites of *P. hominis* per high power field were seen (Figure 1a). The motility was jerky. There were numerous pus cells and Charcot-Leyden crystals (Figure 1b). Smears (stained with Giemsa and modified trichrome stain after methanol fixation) revealed numerous trophozoites, each trophozoite measuring around 10-12  $\mu$ . The trophozoites were pear shaped with a single nucleus and the undulating membrane extended beyond the length of the body (Figure 1c). The number of flagella could not be ascertained. Trophozoites were pink and blue colored (modified trichrome and Giemsa stains, respectively). Similar findings were noted on all three occasions when stool sample was received. No bacterial cause of diarrhea was isolated on stool culture.

The patient was promptly started on tablet metronidazole 400 mg thrice daily along with water and electrolyte replacement. Repeat sample on the 3<sup>rd</sup> day of treatment showed a significant



**Figure 1: (a) Trophozoites of *Pentatrichomonas hominis* on stool wet mount under  $\times 400$  magnification in light microscope, (b) trophozoites of *Pentatrichomonas hominis* on Giemsa stain under  $\times 1000$  magnification in light microscope, (c) Charcot-Leyden crystals on modified trichrome stain under  $\times 1000$  magnification in light microscope**

reduction in the number of trophozoites (10-15/hpf). After 5 days of treatment with metronidazole, trophozoites of *P. hominis* were not seen on stool routine microscopy. Charcot-Leyden crystals were found to persist probably due to significantly elevated eosinophil counts.

Urine sample of both the patient and his wife was examined for trophozoites of *Trichomonas vaginalis*. It was, however, found to be negative. At this stage, the patient was then transferred to AIIMS, New Delhi, for the treatment of his malignancy and hence his further clinical improvement was not known.

## DISCUSSION

To the best of our knowledge, this is the first case report of diarrhea due to *P. hominis* in an immune suppressed individual being reported in India.

Severe diarrhea due to this organism has been reported in a patient with lymphoma in China [5]. It was also cited as the cause of watery diarrhea in a 28-year-old woman with systemic lupus erythematosus in Thailand [6]. Two cases, in an adult and child, respectively, have been reported from Italy in 2011 [7]. Diarrhea in a 68-year-old man with rheumatoid arthritis was attributed to this organism in France in 2013 [8]. Children of Morocco have shown a prevalence of 1.1% of this organism [9].

*P. hominis* is considered to be a commensal that inhabits caecum and large intestine in man. Although regarded to be non-pathogenic, it has been postulated that these trichomonads undergo multiplication under favorable conditions for growth and exhibit a form of opportunism eventually causing diarrhea. The distinct role as an etiopathological agent of diarrhea is yet to be elucidated. This organism is also found in non-human primate hosts, such as cats and dogs throwing light on the zoonotic potential of this trichomonad [10]. Reports of the few cases available shows that the parasite is susceptible to metronidazole and furazolidone with evidence of complete cure [4,7,8].

With only a handful of such reports across the world and none before this from India, it is highlighted that this organism is grossly

under-reported. Being a commensal of the gastrointestinal tract, an insight into the possible role of *P. hominis* as an etiological agent of diarrhea needs to be further contemplated to estimate its true prevalence. A need to spread awareness among clinicians is also warranted.

## REFERENCES

1. Kissinger P, Adamski A. Trichomoniasis and HIV interactions: A review. *Sex Transm Infect.* 2013;89(6):426-33.
2. Duboucher C, Mogenet M, Périé G. Salivary trichomoniasis. A case report of infestation of a submaxillary gland by *Trichomonas tenax*. *Arch Pathol Lab Med.* 1995;119(3):277-9.
3. Hussein EM, Al-Mohammed HI, Hussein AM. Genetic diversity of *Dientamoeba fragilis* isolates of irritable bowel syndrome patients by high-resolution melting-curve (HRM) analysis. *Parasitol Res.* 2009;105(4):1053-60.
4. Mancilla-Ramírez J, González-Yunes R. Diarrhea associated with *Trichomonas hominis* in a newborn infant. *Bol Med Hosp Infant Mex.* 1989;46(9):623-5.
5. Shaio MF, Lo HS, Huang SW. *Trichomonas hominis*: Isolation and axenic cultivation (author's transl). *Zhonghua Min Guo Wei Sheng Wu Ji Mian Yi Xue Za Zhi.* 1981;14(2):73-7.
6. Jongwutiwes S, Silachamroon U, Putaporntip C. *Pentatrichomonas hominis* in empyema thoracis. *Trans R Soc Trop Med Hyg.* 2000;94(2):185-6.
7. Meloni D, Mantini C, Goustille J, Desoubreux G, Maakaroun-Verresse Z, Chandenier J, et al. Molecular identification of *Pentatrichomonas hominis* in two patients with gastrointestinal symptoms. *J Clin Pathol.* 2011;64(10):933-5.
8. Compaoré C, Kemta Lekpa F, Nebie L, Niamba P, Niakara A. *Pentatrichomonas hominis* infection in rheumatoid arthritis treated with adalimumab. *Rheumatology (Oxford).* 2013;52(8):1534-5.
9. El-Fadeli S, Bouhouch R, Lahrouni M, Chabaa L, Asmama S, Fdil N, et al. The prevalence of intestinal parasites in school children in a rural region of Marrakech-Morocco. *Int J Innov Sci Res.* 2015;19(2):229-34.
10. Maritz JM, Land KM, Carlton JM, Hirt RP. What is the importance of zoonotic trichomonads for human health? *Trends Parasitol.* 2014;30(7):333-41.

*Funding: None; Conflict of Interest: None Stated.*

**How to cite this article:** Saha R, Singal A, Kaushik S, Das S. *Pentatrichomonas hominis* in an immunosuppressed patient with enteric manifestations. *East J Med Sci.* 2017;2(2):37-38.