

Case Series

Plantar warts: Clinical insights and the Role of homeopathy in treatment

Kirti Mutreja¹, Hariharan Mani²

From, ¹Consultant Homeopathic Physician & Psychiatrist, Department of Homeopathy, Bhaktivedanta Hospital and Research Institute, Mira Road, Maharashtra, India, ²Clinical Research Co-Ordinator, Department of Medical Research, Bhaktivedanta Hospital and Research Institute, Mira Road, Maharashtra, India.

ABSTRACT

This case series reports both pediatric and adolescent patients with plantar and multiple cutaneous warts of varying duration, including recurrent and treatment-resistant lesions, who were treated with individualized constitutional homeopathic medicines. Remedies were selected following a comprehensive evaluation of physical, mental, and emotional symptoms, supported by repertorization. All patients demonstrated complete resolution of warts without scarring, without the use of local applications. Improvement in overall well-being was noted, and sustained long-term remission was observed, with no recurrence during follow-up periods ranging from four to ten years. These cases highlight the effectiveness of individualized homeopathic management in addressing persistent plantar warts and suggest the need for further systematic and controlled studies to evaluate its therapeutic potential.

Key words: Warts, Homeopathy, Complementary Therapies, Papillomavirus infections, Adolescent.

Warts are benign dermatological conditions that occur at any age and are caused by infection with human papillomavirus (HPV). Transmission occurs either directly through skin-to-skin contact or indirectly from surfaces infected with the virus, with viral entry facilitated by minor skin abrasions or macerations. Despite widespread exposure to HPV, only a proportion of individuals develop warts, indicating that host-related factors, like immune susceptibility, play an important role in their development. Clinically, warts are characterized by slow-growing, hyperkeratotic, verrucous lesions that may present as single or multiple [1, 2].

Among the various clinical types, plantar warts (*verruca plantaris*) are considered the most difficult to manage. Located on weight-bearing areas of the soles, these lesions often grow inward due to constant mechanical pressure, making them painful and resistant to treatment. The recurrence rates remain high with conventional management protocols, including topical salicylic acid, cryotherapy, and other destructive modalities. No single therapy has demonstrated consistent effectiveness across all patients. In immunocompetent individuals, a wait-and-watch approach is sometimes adopted, as spontaneous resolution may occur, although this may prolong symptoms and cause long-term functional discomfort [1, 3, 4].

In homeopathy, cutaneous manifestations such as warts are regarded as expressions of an underlying constitutional

susceptibility rather than a solely localized viral pathology. Treatment is therefore directed towards individualized internal remedies based on the patient's overall physical and psychological symptom profile, rather than local destructive measures. Several clinical reports and observational studies have described favorable outcomes with homeopathic management of warts, particularly in recurrent or treatment-resistant cases [5, 6, 7].

The present case series describes three pediatric and adolescent patients with plantar and multiple cutaneous warts who demonstrated complete resolution following individualized homeopathic treatment, with sustained long-term remission observed on follow-up.

CASE PRESENTATION

Case 1:

A 14-year-old female patient presented with multiple plantar warts involving the soles of both feet, along with a few hyperkeratotic lesions on the palms and fingers. The condition had been present for approximately four years, with repeated recurrences despite prior topical treatments. Lime water application was also tried by the patient, but it provided only temporary relief. Over the preceding two years, the lesions had become persistent, prompting concern regarding both cosmetic appearance and lack of sustained response to treatment. The warts were painless and non-pruritic, with no history of bleeding, discharge, or systemic illness.

Correspondence to: Dr. Kirti Mutreja, Department of Homeopathy, Bhaktivedanta Hospital and Research Institute, Mira Road, Maharashtra, India.

Email: kirti.m@bhaktivedantahospital.com

Access this article online

Received – 16th December 2025
Initial Review – 29th December 2025
Accepted – 31st December 2025

Quick response code

On general examination, the patient was afebrile with stable vital signs. Cutaneous examination revealed multiple well-defined, elevated, hyperkeratotic papules and plaques located predominantly in overweight-bearing areas of the plantar surface, including the metatarsal head region and plantar aspect of the great toe and adjacent toes. An isolated hyperkeratotic lesion was also noted on the palm (Figure 1).

There was no surrounding erythema, tenderness, or signs of inflammation. Appetite and bowel habits were normal. Perspiration was excessive on the palms, occurring mainly during hot weather and not associated with anxiety. Psychological assessment revealed that the patient was talkative, friendly, and emotionally expressive, with a strong attachment to family and friends. She was short-tempered and easily angered when contradicted. A marked fear of cockroaches was also reported.

Repertorization was carried out using Synergy Homoeopathic Software, incorporating rubrics related to plantar and multiple painless warts, perspiration of palms in heat, fear of insects, anger from contradiction, and affectionate disposition. The repertorization analysis highlighted Natrum muriaticum, Lycopodium, Sulphur, Sepia, Phosphorus, and Calcarea carbonica as leading remedies. Based on the totality of symptoms and constitutional assessment, Natrum muriaticum 200C was prescribed as a single dose. No local applications were advised (Table 1).

During follow-up, lesions were flattened, followed by a reduction in size and resolution of hyperkeratosis. The surrounding skin regained a smooth and healthy appearance

without scarring or residual pigmentation. Complete resolution was achieved, and the patient has remained wart-free with no recurrence during a follow-up period of five years (Figure 2).

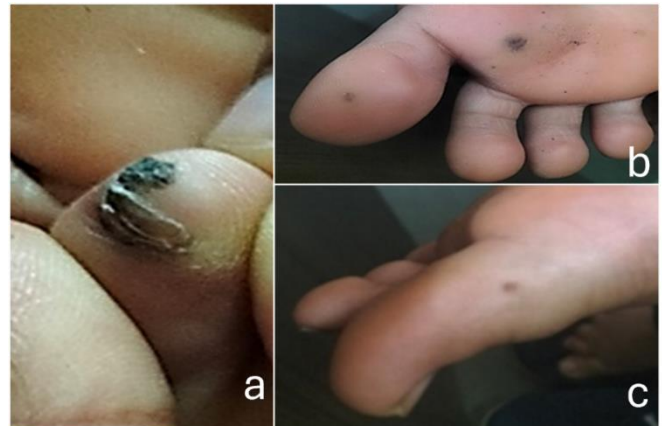


Figure 1 (a, b, c). Multiple plantar and palmar warts before treatment.

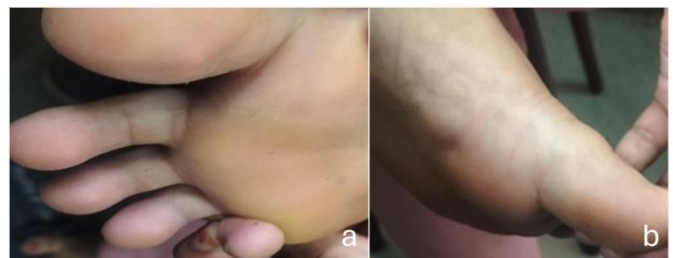

Figure 2 (a, b): Complete resolution of lesions after individualized homeopathic treatment.

Table 1. Repertorization chart of Case 1

| Grade | CR21 - mind; anger; ailments from, agg.; violent anger (18) | CR21 - mind; anger; contradiction, from (82) | CR21 - mind; anger; answer, when obliged to (14) | CR21 - mind; fear; bugs, insects (22) | CR21 - extremities; perspiration; hands; palms (126) | CR21 - mind; affectionate (91) | R.R. - Extremities; Warts; fingers (29) | CR21 - extremities; warts; hands; back (16) | CR21 - extremities; warts; feet (40) | CR21 - extremities; warts; feet; soles (33) |
|---------|---|--|--|---------------------------------------|--|--------------------------------|---|---|--------------------------------------|---|
| Total | 18 | 82 | 14 | 22 | 126 | 91 | 29 | 16 | 40 | 33 |
| Rubrics | 10 | 9 | 8 | 7 | 7 | 7 | 6 | 6 | 5 | 5 |
| Kingdom | 10 | 9 | 8 | 7 | 7 | 7 | 6 | 6 | 5 | 5 |

| | Nat-m. | Lyc. | Sulph. | Sep. | Calc. | Ars. | Nit-ac. | Phos. | Thuj. | Carc. | Nux-v. | Bry. | Sil. | Con. | Bar-c. | Hoch. | Med. | Calc-p. | Sanic. | Anac. | Ferr. | Caust. | |
|--------------------------------------|--------|------|--------|------|-------|------|---------|-------|-------|-------|--------|------|------|------|--------|-------|------|---------|--------|-------|-------|--------|--|
| CR21 - mind; anger; ailments fr... | | | | | | | | | | | | | | | | | | | | | | | |
| CR21 - mind; anger; contradicti... | | | | | | | | | | | | | | | | | | | | | | | |
| CR21 - mind; anger; answer, wh... | | | | | | | | | | | | | | | | | | | | | | | |
| CR21 - mind; fear; bugs, insect... | | | | | | | | | | | | | | | | | | | | | | | |
| CR21 - extremities; perspiratio... | | | | | | | | | | | | | | | | | | | | | | | |
| CR21 - mind; affectionate(91) | | | | | | | | | | | | | | | | | | | | | | | |
| R.R. - Extremities; Warts; finger... | | | | | | | | | | | | | | | | | | | | | | | |
| CR21 - extremities; warts; hand... | | | | | | | | | | | | | | | | | | | | | | | |
| CR21 - extremities; warts; feet... | | | | | | | | | | | | | | | | | | | | | | | |
| CR21 - extremities; warts; feet; ... | | | | | | | | | | | | | | | | | | | | | | | |

Case 2:

A 5-year-old male child presented with painless warts on the right palm (Figure 3) and the plantar aspect of the left foot. There was no associated itching, bleeding, or discharge. In addition, the child had a history of recurrent upper respiratory tract infections and tonsillitis, accompanied by a dry allergic

cough triggered by minimal intake of cold food. The cough was characteristically aggravated between 3–4 pm and 6 pm. Bowel movements were hard but regular. The child was thermally hot in nature.

Physical examination revealed multiple warts on the palm and plantar surface, without signs of inflammation or

secondary infection. Systemic examination was unremarkable. Emotionally, the child displayed perfectionistic behavior in academic tasks and had a strong desire to be appreciated by teachers. There was marked fear of punishment, pain, and injections.

Repertorization was performed using Synergy Homoeopathic Software with Phatak Repertory and Complete Repertory (CR21). Rubrics included fear of pointed objects and needles, tendency to catch cold easily, perspiration of hands and feet, warts on extremities, functional bowel disturbances, and dry cough aggravated in the evening. The leading remedies identified were Silicea, Calcarea carbonica, Sulphur, Sepia, Phosphorus, Natrum carbonicum, Lycopodium, and Medorrhinum. Correlation with the patient's constitutional features favored Silicea, which was prescribed in 200C potency as a single dose (Table 2).

Within two to three weeks of treatment, the warts dried and detached spontaneously without scarring or callosity. After a follow-up of ten years, the patient reported no recurrence of warts (Figure 4).

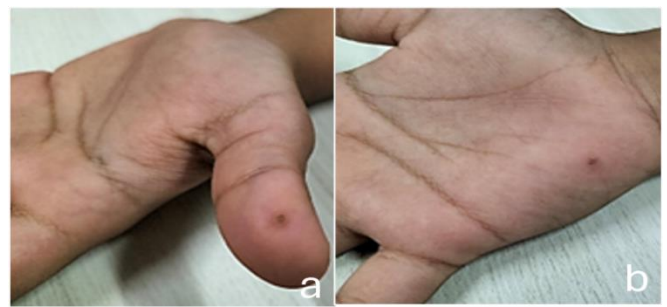

Figure 3 (a, b). Warts on the palm before the treatment

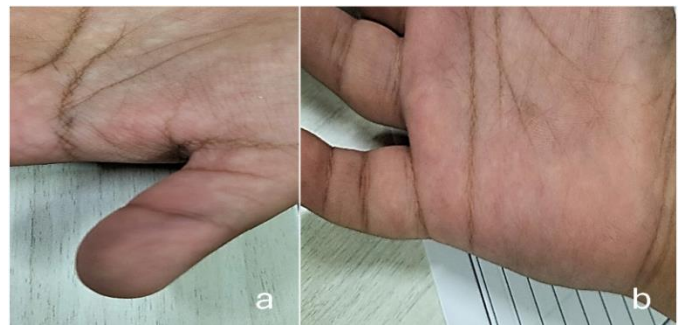

Figure 4 (a, b): Complete resolution of lesions following treatment.

Table 2. Repertorization chart of Case 2

| Clipboard 1 | synergy | Waffle graph | Go to Remedy | | | | | | | | | | | | | | | | | | | | | | | | | | | | | | | | | | | | | | | | | | | | | | | | | | | | | | | | | | | | | | | | | | | | | | | | | | | | | | | | | | | | | | | | | | | | | | | | | | | | | | | | | | | | | | | | | | | | | | | | | | | | | | | | | | | | | | | | | | | | | | | | | | | | | | | | | | | | | | | | | | | | | | | | | | | | | | | | | | | | | | | | | | | | | | | | | | | | | | | | | | | | | | | | | | | | | | | | | | | | | | | | | | | | | | | | | | | | | | | | | | | | | | | | | | | | | | | | | | | | | | | | | | | | | | | | | | | | | | | | | | | | | | | | | | | | | | | | | | | | | | | | | | | | | | | | | | | | | | | |
|--|-----------------------|---|--------------|---------|-------|---------|---------|--------|---------|---------|--------|-------|---------|------|-------|-------|------|------|-------|-------|--------|-------|-------|--------|----|----|----|----|----|----|----|----|----|---|----|----|----|----|----|----|---|---|---|---|----|----|----|----|---|---|---|---|---|---|---|---|---|---|---|---|---|---|---|---|---|---|---|---|---|---|--|--|--|--|--|--|--|--|--|--|--|--|--|--|--|--|--|--|--|--|--|--|--|--|--|--|--|--|--|--|--|--|--|--|--|--|--|--|--|--|--|--|--|--|--|---|--|--|--|--|--|--|--|--|--|--|--|--|--|--|--|--|--|--|--|--|--|--|--|--|--|--|--|--|--|--|--|--|--|--|--|--|--|--|--|--|--|--|--|--|--|--|--|--|--|--|--|--|--|--|--|--|--|--|--|--|--|--|--|--|--|--|--|--|---|--|--|--|--|--|--|--|--|--|--|--|--|--|--|--|--|--|--|--|--|--|--|--|--|--|--|--|--|--|--|--|--|--|--|--|--|--|--|--|--|--|--|--|--|--|---------------------------------------|--|--|--|--|--|--|--|--|--|--|--|--|--|--|--|--|--|--|--|--|--|--|-----------------------------------|--|--|--|--|--|--|--|--|--|--|--|--|--|--|--|--|--|--|--|--|--|--|---------------------------------------|--|--|--|--|--|--|--|--|--|--|--|--|--|--|--|--|--|--|--|--|--|--|--|--|--|--|--|--|--|--|--|--|--|--|--|--|--|--|--|--|--|--|--|--|--|
| Phatak - Phatak repertory; Fear, anxiety, fright; pointed things, needles, pins (7) : CR21 - generalities; cold taking, becoming; heated, after becoming (5) : CR21 - mind; obstinate, headstrong; children, in (42) : Phatak - Phatak repertory; Stools; hard (24) : CR21 - extremities; perspiration; hands; palms (126) : CR21 - extremities; perspiration; feet; soles (51) : Phatak - Phatak repertory; Callosities, corns (14) : CR21 - extremities; warts; hands (65) : CR21 - cough; cold; becoming (16) : CR21 - cough; dry; daytime; agg. (59) : CR21 - cough; convulsive, spasmodic; evening (39) : | Total Rubrics Kingdom | <table border="1"> <thead> <tr> <th>Sil.</th> <th>Calc.</th> <th>Sep.</th> <th>Sulph.</th> <th>Rhus-L.</th> <th>Phos.</th> <th>Kali-C.</th> <th>Nat-m.</th> <th>Bar-C.</th> <th>ArS.</th> <th>Nit-oc.</th> <th>Con.</th> <th>Psor.</th> <th>Puls.</th> <th>Bry.</th> <th>Lyc.</th> <th>Merc.</th> <th>Med.</th> <th>Arn.</th> <th>Bell.</th> <th>ThuJ.</th> <th>Ant-c.</th> </tr> </thead> <tbody> <tr> <td>29</td> <td>24</td> <td>20</td> <td>17</td> <td>18</td> <td>12</td> <td>14</td> <td>13</td> <td>11</td> <td>8</td> <td>13</td> <td>11</td> <td>11</td> <td>11</td> <td>10</td> <td>10</td> <td>9</td> <td>6</td> <td>5</td> <td>5</td> <td>11</td> <td>10</td> </tr> <tr> <td>11</td> <td>10</td> <td>8</td> <td>8</td> <td>7</td> <td>7</td> <td>6</td> <td>6</td> <td>6</td> <td>6</td> <td>5</td> <td>5</td> <td>5</td> <td>5</td> <td>5</td> <td>5</td> <td>5</td> <td>5</td> <td>5</td> <td>5</td> <td>4</td> <td>4</td> </tr> </tbody> </table> | Sil. | Calc. | Sep. | Sulph. | Rhus-L. | Phos. | Kali-C. | Nat-m. | Bar-C. | ArS. | Nit-oc. | Con. | Psor. | Puls. | Bry. | Lyc. | Merc. | Med. | Arn. | Bell. | ThuJ. | Ant-c. | 29 | 24 | 20 | 17 | 18 | 12 | 14 | 13 | 11 | 8 | 13 | 11 | 11 | 11 | 10 | 10 | 9 | 6 | 5 | 5 | 11 | 10 | 11 | 10 | 8 | 8 | 7 | 7 | 6 | 6 | 6 | 6 | 5 | 5 | 5 | 5 | 5 | 5 | 5 | 5 | 5 | 5 | 4 | 4 | <table border="1"> <tbody> <tr> <td>Phatak - Phatak repertory; Fear, a... (7)</td> <td></td> <td></td> <td></td> <td></td> <td></td> <td></td> <td></td> <td></td> <td></td> <td></td> <td></td> <td></td> <td></td> <td></td> <td></td> <td></td> <td></td> <td></td> <td></td> <td></td> <td></td> <td></td> </tr> <tr> <td>CR21 - generalities; cold taking, ... (51)</td> <td></td> <td></td> <td></td> <td></td> <td></td> <td></td> <td></td> <td></td> <td></td> <td></td> <td></td> <td></td> <td></td> <td></td> <td></td> <td></td> <td></td> <td></td> <td></td> <td></td> <td></td> <td></td> </tr> <tr> <td>CR21 - mind; obstinate, headstr... (42)</td> <td></td> <td></td> <td></td> <td></td> <td></td> <td></td> <td></td> <td></td> <td></td> <td></td> <td></td> <td></td> <td></td> <td></td> <td></td> <td></td> <td></td> <td></td> <td></td> <td></td> <td></td> <td></td> </tr> <tr> <td>Phatak - Phatak repertory; Stool... (24)</td> <td></td> <td></td> <td></td> <td></td> <td></td> <td></td> <td></td> <td></td> <td></td> <td></td> <td></td> <td></td> <td></td> <td></td> <td></td> <td></td> <td></td> <td></td> <td></td> <td></td> <td></td> <td></td> </tr> <tr> <td>CR21 - extremities; perspiration;... (126)</td> <td></td> <td></td> <td></td> <td></td> <td></td> <td></td> <td></td> <td></td> <td></td> <td></td> <td></td> <td></td> <td></td> <td></td> <td></td> <td></td> <td></td> <td></td> <td></td> <td></td> <td></td> <td></td> </tr> <tr> <td>CR21 - extremities; perspiration; f... (51)</td> <td></td> <td></td> <td></td> <td></td> <td></td> <td></td> <td></td> <td></td> <td></td> <td></td> <td></td> <td></td> <td></td> <td></td> <td></td> <td></td> <td></td> <td></td> <td></td> <td></td> <td></td> <td></td> </tr> <tr> <td>Phatak - Phatak repertory; Callo... (14)</td> <td></td> <td></td> <td></td> <td></td> <td></td> <td></td> <td></td> <td></td> <td></td> <td></td> <td></td> <td></td> <td></td> <td></td> <td></td> <td></td> <td></td> <td></td> <td></td> <td></td> <td></td> <td></td> </tr> <tr> <td>CR21 - extremities; warts; hands (65)</td> <td></td> <td></td> <td></td> <td></td> <td></td> <td></td> <td></td> <td></td> <td></td> <td></td> <td></td> <td></td> <td></td> <td></td> <td></td> <td></td> <td></td> <td></td> <td></td> <td></td> <td></td> <td></td> </tr> <tr> <td>CR21 - cough; cold; becoming (16)</td> <td></td> <td></td> <td></td> <td></td> <td></td> <td></td> <td></td> <td></td> <td></td> <td></td> <td></td> <td></td> <td></td> <td></td> <td></td> <td></td> <td></td> <td></td> <td></td> <td></td> <td></td> <td></td> </tr> <tr> <td>CR21 - cough; dry; daytime; agg. (59)</td> <td></td> <td></td> <td></td> <td></td> <td></td> <td></td> <td></td> <td></td> <td></td> <td></td> <td></td> <td></td> <td></td> <td></td> <td></td> <td></td> <td></td> <td></td> <td></td> <td></td> <td></td> <td></td> </tr> <tr> <td>CR21 - cough; convulsive, spas... (39)</td> <td></td> <td></td> <td></td> <td></td> <td></td> <td></td> <td></td> <td></td> <td></td> <td></td> <td></td> <td></td> <td></td> <td></td> <td></td> <td></td> <td></td> <td></td> <td></td> <td></td> <td></td> <td></td> </tr> </tbody> </table> | Phatak - Phatak repertory; Fear, a... (7) | | | | | | | | | | | | | | | | | | | | | | | CR21 - generalities; cold taking, ... (51) | | | | | | | | | | | | | | | | | | | | | | | CR21 - mind; obstinate, headstr... (42) | | | | | | | | | | | | | | | | | | | | | | | Phatak - Phatak repertory; Stool... (24) | | | | | | | | | | | | | | | | | | | | | | | CR21 - extremities; perspiration;... (126) | | | | | | | | | | | | | | | | | | | | | | | CR21 - extremities; perspiration; f... (51) | | | | | | | | | | | | | | | | | | | | | | | Phatak - Phatak repertory; Callo... (14) | | | | | | | | | | | | | | | | | | | | | | | CR21 - extremities; warts; hands (65) | | | | | | | | | | | | | | | | | | | | | | | CR21 - cough; cold; becoming (16) | | | | | | | | | | | | | | | | | | | | | | | CR21 - cough; dry; daytime; agg. (59) | | | | | | | | | | | | | | | | | | | | | | | CR21 - cough; convulsive, spas... (39) | | | | | | | | | | | | | | | | | | | | | | |
| Sil. | Calc. | Sep. | Sulph. | Rhus-L. | Phos. | Kali-C. | Nat-m. | Bar-C. | ArS. | Nit-oc. | Con. | Psor. | Puls. | Bry. | Lyc. | Merc. | Med. | Arn. | Bell. | ThuJ. | Ant-c. | | | | | | | | | | | | | | | | | | | | | | | | | | | | | | | | | | | | | | | | | | | | | | | | | | | | | | | | | | | | | | | | | | | | | | | | | | | | | | | | | | | | | | | | | | | | | | | | | | | | | | | | | | | | | | | | | | | | | | | | | | | | | | | | | | | | | | | | | | | | | | | | | | | | | | | | | | | | | | | | | | | | | | | | | | | | | | | | | | | | | | | | | | | | | | | | | | | | | | | | | | | | | | | | | | | | | | | | | | | | | | | | | | | | | | | | | | | | | | | | | | | | | | | | | | | | | | | | | | | | | | | | | | | | | | | | | | | | | | | | | | | | | | | | | | | | | | | | | | | | | |
| 29 | 24 | 20 | 17 | 18 | 12 | 14 | 13 | 11 | 8 | 13 | 11 | 11 | 11 | 10 | 10 | 9 | 6 | 5 | 5 | 11 | 10 | | | | | | | | | | | | | | | | | | | | | | | | | | | | | | | | | | | | | | | | | | | | | | | | | | | | | | | | | | | | | | | | | | | | | | | | | | | | | | | | | | | | | | | | | | | | | | | | | | | | | | | | | | | | | | | | | | | | | | | | | | | | | | | | | | | | | | | | | | | | | | | | | | | | | | | | | | | | | | | | | | | | | | | | | | | | | | | | | | | | | | | | | | | | | | | | | | | | | | | | | | | | | | | | | | | | | | | | | | | | | | | | | | | | | | | | | | | | | | | | | | | | | | | | | | | | | | | | | | | | | | | | | | | | | | | | | | | | | | | | | | | | | | | | | | | | | | | | | | | | | |
| 11 | 10 | 8 | 8 | 7 | 7 | 6 | 6 | 6 | 6 | 5 | 5 | 5 | 5 | 5 | 5 | 5 | 5 | 5 | 5 | 4 | 4 | | | | | | | | | | | | | | | | | | | | | | | | | | | | | | | | | | | | | | | | | | | | | | | | | | | | | | | | | | | | | | | | | | | | | | | | | | | | | | | | | | | | | | | | | | | | | | | | | | | | | | | | | | | | | | | | | | | | | | | | | | | | | | | | | | | | | | | | | | | | | | | | | | | | | | | | | | | | | | | | | | | | | | | | | | | | | | | | | | | | | | | | | | | | | | | | | | | | | | | | | | | | | | | | | | | | | | | | | | | | | | | | | | | | | | | | | | | | | | | | | | | | | | | | | | | | | | | | | | | | | | | | | | | | | | | | | | | | | | | | | | | | | | | | | | | | | | | | | | | | | |
| Phatak - Phatak repertory; Fear, a... (7) | | | | | | | | | | | | | | | | | | | | | | | | | | | | | | | | | | | | | | | | | | | | | | | | | | | | | | | | | | | | | | | | | | | | | | | | | | | | | | | | | | | | | | | | | | | | | | | | | | | | | | | | | | | | | | | | | | | | | | | | | | | | | | | | | | | | | | | | | | | | | | | | | | | | | | | | | | | | | | | | | | | | | | | | | | | | | | | | | | | | | | | | | | | | | | | | | | | | | | | | | | | | | | | | | | | | | | | | | | | | | | | | | | | | | | | | | | | | | | | | | | | | | | | | | | | | | | | | | | | | | | | | | | | | | | | | | | | | | | | | | | | | | | | | | | | | | | | | | | | | | | | | | | | | | | | | | | | | | | | | | | |
| CR21 - generalities; cold taking, ... (51) | | | | | | | | | | | | | | | | | | | | | | | | | | | | | | | | | | | | | | | | | | | | | | | | | | | | | | | | | | | | | | | | | | | | | | | | | | | | | | | | | | | | | | | | | | | | | | | | | | | | | | | | | | | | | | | | | | | | | | | | | | | | | | | | | | | | | | | | | | | | | | | | | | | | | | | | | | | | | | | | | | | | | | | | | | | | | | | | | | | | | | | | | | | | | | | | | | | | | | | | | | | | | | | | | | | | | | | | | | | | | | | | | | | | | | | | | | | | | | | | | | | | | | | | | | | | | | | | | | | | | | | | | | | | | | | | | | | | | | | | | | | | | | | | | | | | | | | | | | | | | | | | | | | | | | | | | | | | | | | | | | |
| CR21 - mind; obstinate, headstr... (42) | | | | | | | | | | | | | | | | | | | | | | | | | | | | | | | | | | | | | | | | | | | | | | | | | | | | | | | | | | | | | | | | | | | | | | | | | | | | | | | | | | | | | | | | | | | | | | | | | | | | | | | | | | | | | | | | | | | | | | | | | | | | | | | | | | | | | | | | | | | | | | | | | | | | | | | | | | | | | | | | | | | | | | | | | | | | | | | | | | | | | | | | | | | | | | | | | | | | | | | | | | | | | | | | | | | | | | | | | | | | | | | | | | | | | | | | | | | | | | | | | | | | | | | | | | | | | | | | | | | | | | | | | | | | | | | | | | | | | | | | | | | | | | | | | | | | | | | | | | | | | | | | | | | | | | | | | | | | | | | | | | |
| Phatak - Phatak repertory; Stool... (24) | | | | | | | | | | | | | | | | | | | | | | | | | | | | | | | | | | | | | | | | | | | | | | | | | | | | | | | | | | | | | | | | | | | | | | | | | | | | | | | | | | | | | | | | | | | | | | | | | | | | | | | | | | | | | | | | | | | | | | | | | | | | | | | | | | | | | | | | | | | | | | | | | | | | | | | | | | | | | | | | | | | | | | | | | | | | | | | | | | | | | | | | | | | | | | | | | | | | | | | | | | | | | | | | | | | | | | | | | | | | | | | | | | | | | | | | | | | | | | | | | | | | | | | | | | | | | | | | | | | | | | | | | | | | | | | | | | | | | | | | | | | | | | | | | | | | | | | | | | | | | | | | | | | | | | | | | | | | | | | | | | |
| CR21 - extremities; perspiration;... (126) | | | | | | | | | | | | | | | | | | | | | | | | | | | | | | | | | | | | | | | | | | | | | | | | | | | | | | | | | | | | | | | | | | | | | | | | | | | | | | | | | | | | | | | | | | | | | | | | | | | | | | | | | | | | | | | | | | | | | | | | | | | | | | | | | | | | | | | | | | | | | | | | | | | | | | | | | | | | | | | | | | | | | | | | | | | | | | | | | | | | | | | | | | | | | | | | | | | | | | | | | | | | | | | | | | | | | | | | | | | | | | | | | | | | | | | | | | | | | | | | | | | | | | | | | | | | | | | | | | | | | | | | | | | | | | | | | | | | | | | | | | | | | | | | | | | | | | | | | | | | | | | | | | | | | | | | | | | | | | | | | | |
| CR21 - extremities; perspiration; f... (51) | | | | | | | | | | | | | | | | | | | | | | | | | | | | | | | | | | | | | | | | | | | | | | | | | | | | | | | | | | | | | | | | | | | | | | | | | | | | | | | | | | | | | | | | | | | | | | | | | | | | | | | | | | | | | | | | | | | | | | | | | | | | | | | | | | | | | | | | | | | | | | | | | | | | | | | | | | | | | | | | | | | | | | | | | | | | | | | | | | | | | | | | | | | | | | | | | | | | | | | | | | | | | | | | | | | | | | | | | | | | | | | | | | | | | | | | | | | | | | | | | | | | | | | | | | | | | | | | | | | | | | | | | | | | | | | | | | | | | | | | | | | | | | | | | | | | | | | | | | | | | | | | | | | | | | | | | | | | | | | | | | |
| Phatak - Phatak repertory; Callo... (14) | | | | | | | | | | | | | | | | | | | | | | | | | | | | | | | | | | | | | | | | | | | | | | | | | | | | | | | | | | | | | | | | | | | | | | | | | | | | | | | | | | | | | | | | | | | | | | | | | | | | | | | | | | | | | | | | | | | | | | | | | | | | | | | | | | | | | | | | | | | | | | | | | | | | | | | | | | | | | | | | | | | | | | | | | | | | | | | | | | | | | | | | | | | | | | | | | | | | | | | | | | | | | | | | | | | | | | | | | | | | | | | | | | | | | | | | | | | | | | | | | | | | | | | | | | | | | | | | | | | | | | | | | | | | | | | | | | | | | | | | | | | | | | | | | | | | | | | | | | | | | | | | | | | | | | | | | | | | | | | | | | |
| CR21 - extremities; warts; hands (65) | | | | | | | | | | | | | | | | | | | | | | | | | | | | | | | | | | | | | | | | | | | | | | | | | | | | | | | | | | | | | | | | | | | | | | | | | | | | | | | | | | | | | | | | | | | | | | | | | | | | | | | | | | | | | | | | | | | | | | | | | | | | | | | | | | | | | | | | | | | | | | | | | | | | | | | | | | | | | | | | | | | | | | | | | | | | | | | | | | | | | | | | | | | | | | | | | | | | | | | | | | | | | | | | | | | | | | | | | | | | | | | | | | | | | | | | | | | | | | | | | | | | | | | | | | | | | | | | | | | | | | | | | | | | | | | | | | | | | | | | | | | | | | | | | | | | | | | | | | | | | | | | | | | | | | | | | | | | | | | | | | |
| CR21 - cough; cold; becoming (16) | | | | | | | | | | | | | | | | | | | | | | | | | | | | | | | | | | | | | | | | | | | | | | | | | | | | | | | | | | | | | | | | | | | | | | | | | | | | | | | | | | | | | | | | | | | | | | | | | | | | | | | | | | | | | | | | | | | | | | | | | | | | | | | | | | | | | | | | | | | | | | | | | | | | | | | | | | | | | | | | | | | | | | | | | | | | | | | | | | | | | | | | | | | | | | | | | | | | | | | | | | | | | | | | | | | | | | | | | | | | | | | | | | | | | | | | | | | | | | | | | | | | | | | | | | | | | | | | | | | | | | | | | | | | | | | | | | | | | | | | | | | | | | | | | | | | | | | | | | | | | | | | | | | | | | | | | | | | | | | | | | |
| CR21 - cough; dry; daytime; agg. (59) | | | | | | | | | | | | | | | | | | | | | | | | | | | | | | | | | | | | | | | | | | | | | | | | | | | | | | | | | | | | | | | | | | | | | | | | | | | | | | | | | | | | | | | | | | | | | | | | | | | | | | | | | | | | | | | | | | | | | | | | | | | | | | | | | | | | | | | | | | | | | | | | | | | | | | | | | | | | | | | | | | | | | | | | | | | | | | | | | | | | | | | | | | | | | | | | | | | | | | | | | | | | | | | | | | | | | | | | | | | | | | | | | | | | | | | | | | | | | | | | | | | | | | | | | | | | | | | | | | | | | | | | | | | | | | | | | | | | | | | | | | | | | | | | | | | | | | | | | | | | | | | | | | | | | | | | | | | | | | | | | | |
| CR21 - cough; convulsive, spas... (39) | | | | | | | | | | | | | | | | | | | | | | | | | | | | | | | | | | | | | | | | | | | | | | | | | | | | | | | | | | | | | | | | | | | | | | | | | | | | | | | | | | | | | | | | | | | | | | | | | | | | | | | | | | | | | | | | | | | | | | | | | | | | | | | | | | | | | | | | | | | | | | | | | | | | | | | | | | | | | | | | | | | | | | | | | | | | | | | | | | | | | | | | | | | | | | | | | | | | | | | | | | | | | | | | | | | | | | | | | | | | | | | | | | | | | | | | | | | | | | | | | | | | | | | | | | | | | | | | | | | | | | | | | | | | | | | | | | | | | | | | | | | | | | | | | | | | | | | | | | | | | | | | | | | | | | | | | | | | | | | | | | |

Case 3:

A 14-year-old female presented with multiple warts on the hands (Figure 5), periocular region, and corns on the soles. The lesions were gradually progressive and painless, with no itching, discharge, or bleeding. The primary concern of the patient and her parents was cosmetic disfigurement. Appetite was associated with flatulence and early satiety, leading to reduced food intake. Perspiration was noted on the palms. She was lean, underweight, and easily fatigued.

On examination, multiple warts were observed over the hands and around the eyes, with corns on the plantar surface.

There was no erythema, tenderness, or secondary infection. Emotionally, the patient exhibited anxiety with trembling and hurried speech during excitement. She was intellectually sharp but physically weak. She feared being alone and avoided going out without her mother. At home, she was dominating and argumentative, whereas outside, she was timid and fearful.

Repertorization was based on rubrics including warts on hands and face, flatulence with appetite and early satiety, chilliness, perspiration of palms, anxiety with trembling, fear of being alone, and contrasting behavior patterns (Table 3).

Lycopodium clavatum was selected as the constitutional remedy and prescribed in 200C potency, twice daily.

Within one month, one wart dried and fell off spontaneously. Over the subsequent two months, all remaining warts, including periocular lesions, resolved completely without scarring (Figure 6). The patient also reported improvement in confidence, reduced anxiety, and better overall well-being.

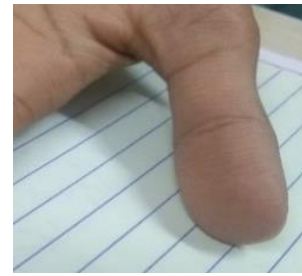

Figure 6: Complete clearance of lesions after treatment.



Figure 5: Warts before treatment.

Table 3. Repertorization chart of Case 3

| Grade | synergy | Total | Rubrics | Kingdom | Lyc. | Sil. | Phos. | Calc. | Ar. | Kali-C. | Sep. | Thu. | Nit-ac. | Sulph. | Caust. | Graph. | Psor. | Rhus-L. | Anac. | Con. | Hyos. | Carc. | Arg-n. | Dulc. | Merc. | Ant-c. |
|--|---------|-------|---------|---------|------|------|-------|-------|-----|---------|------|------|---------|--------|--------|--------|-------|---------|-------|------|-------|-------|--------|-------|-------|--------|
| CR21 - mind; answer, answering, answers; rapidly, quickly; anxious and tremulous (1) | | 90 | | | | | | | | | | | | | | | | | | | | | | | | |
| CR21 - mind; anxiety; agg., ailments from; mental and emotional consequences of (90) | | 90 | | | | | | | | | | | | | | | | | | | | | | | | |
| Boger - Mind; Anthropophobia, bashful, shy, etc. (10) | | 10 | | | | | | | | | | | | | | | | | | | | | | | | |
| CR21 - mind; obstinate, headstrong; children, in (42) | | 42 | | | | | | | | | | | | | | | | | | | | | | | | |
| CR21 - mind; anxiety; alone, while (46) | | 46 | | | | | | | | | | | | | | | | | | | | | | | | |
| CR21 - mind; fear; alone, being; child wants mother to hold her hand (8) | | 8 | | | | | | | | | | | | | | | | | | | | | | | | |
| CR21 - mind; fear; alone, being; solitude, of (35) | | 35 | | | | | | | | | | | | | | | | | | | | | | | | |
| Phatak - Phatak repertory; Appetite; easy satiety (4) | | 4 | | | | | | | | | | | | | | | | | | | | | | | | |
| CR21 - generalities; food and drinks; warm; food, cooked food; desires (44) | | 44 | | | | | | | | | | | | | | | | | | | | | | | | |
| CR21 - generalities; coldness, lack of vital heat; bed, in (66) | | 66 | | | | | | | | | | | | | | | | | | | | | | | | |
| Phatak - Phatak repertory; Callosities, corns (14) | | 14 | | | | | | | | | | | | | | | | | | | | | | | | |
| CR21 - extremities; warts; hands (66) | | 66 | | | | | | | | | | | | | | | | | | | | | | | | |
| CR21 - extremities; perspiration; hands; palms (126) | | 126 | | | | | | | | | | | | | | | | | | | | | | | | |
| CR21 - eyes; warts, condylomata (21) | | 21 | | | | | | | | | | | | | | | | | | | | | | | | |

DISCUSSION

This case series described three patients with plantar and multiple cutaneous warts, including recurrent and long-standing lesions, who showed complete clinical resolution following individualized homeopathic treatment. In all cases, the lesions resolved without the use of local or destructive interventions and healed without scarring. A consistent finding across the cases was sustained remission, with no recurrence observed during long-term follow-up ranging from four to ten years. In addition to dermatological improvement, patients reported better general well-being, which was the result of individualized constitutional management.

The observations from this case series agree with previously published case reports and observational studies

that have described resolution of warts following individualized homeopathic treatment. Several authors have reported favorable outcomes using remedies such as Antimonium crudum, Calcarea carbonica, Natrum muriaticum, Lycopodium, Silicea, and Thuja occidentalis, selected based on the totality of symptoms rather than lesion characteristics alone [5,6,7]. An observational study involving 52 patients documented complete resolution in most cases, supporting the present clinical observations [7].

The small number of cases, absence of a control group, and observational design preclude any conclusions regarding the side effects or comparative effectiveness. Objective virological confirmation of HPV clearance was not performed in this study. Despite these limitations, the consistency of outcomes and the prolonged duration of follow-up strengthen

clinical observations. These cases contribute to the existing literature and highlight the need for larger, well-designed prospective and controlled studies to evaluate individualized homeopathic management of plantar warts.

CONCLUSION

The results of the present case series show the effectiveness of individualized homeopathic treatment of warts in pediatric and adolescent patients. The absence of scarring and recurrence on long-term follow-up was consistent in all cases, recommending larger controlled studies to validate these observations.

REFERENCE

1. Vlahovic TC, Khan MT. The human papillomavirus and its role in plantar warts: a comprehensive review of diagnosis and management. *Clin Podiatr Med Surg*. 2016; 33(3):337–53.
2. Witchey DJ, Witchey NB, Roth-Kauffman MM, Kauffman MK. Plantar warts: epidemiology, pathophysiology, and clinical management. *J Am Osteopath Assoc*. 2018; 118(2):92–105.
3. Zhang Y, Wu S, Zeng Y. Photodynamic therapy for recalcitrant plantar warts: case reports and a literature review. *Photodiagnosis Photodyn Ther*. 2024; 46:104087.
4. Devi K, Intaran A, Made L, Rusyati M, Sadeli M. Current treatment options for cutaneous and plantar warts: a literature review and update. *Dermatol Ther*. 2022; 45:e15432.
5. Nahar L, Debbarma R. Plantar warts treated with homeopathic medicine *Antimonium crudum*: a case report. *Indian J Res Homoeopathy*. 2024; 18(2):127–32.
6. Oza P. Homeopathic management of warts. *Indian J Drugs Dermatol*. 2016; 2(1):45–48.
7. Bhardwaj OP, Manchanda RK, Gupta R. Homeopathy in the treatment of warts. *Br Homoeopath J*. 1991; 80(2):108–11.

How to cite this article: Mutreja K, Mani H. Plantar warts: Clinical insights and the Role of homeopathy in treatment. *Indian J Integr Med*. 2026; Online First.

Funding: None;

Conflicts of Interest: None Stated