

## Primary schwannoma of the appendix: A rare case report with brief review of literature

Shehla Basheer Kollathodi<sup>1</sup>, Shahin Hameed<sup>1</sup>, Faheem Abdulla<sup>2</sup>

From <sup>1</sup>Consultant, Department of Pathology, <sup>2</sup>Consultant, Department of Surgical Oncology, Aster MIMS, Calicut, Kerala, India

### ABSTRACT

Appendiceal schwannoma is an exceptionally rare benign mesenchymal tumor and frequently poses a diagnostic challenge due to non-specific clinical and radiological findings. We report a case of appendiceal schwannoma in a 40-year-old female who presented with right iliac fossa pain and was clinically and radiologically suspected to have appendiceal carcinoma. Laparoscopic radical appendectomy was performed. Histopathological examination revealed a spindle cell neoplasm with nuclear palisading, and immunohistochemistry showed diffuse strong SOX10 positivity with negativity for CD117 and H-caldesmon, confirming the diagnosis. The patient remains asymptomatic on follow-up. A brief review of reported cases is provided.

**Key words:** Appendix, Rare tumor, Schwannoma, SOX10, Spindle cell neoplasm

Schwannomas are benign tumors derived from the Schwann cells, which occur most commonly in the head, neck, and extremities. Gastrointestinal schwannomas account for approximately 2–6% of mesenchymal tumors, with the stomach and colon being the predominant sites. Primary involvement of the appendix is exceedingly uncommon, with fewer than 20 well-documented cases reported in the English literature. Due to non-specific presentation and imaging characteristics, appendiceal schwannomas are frequently misinterpreted preoperatively as appendiceal carcinoma, neuroendocrine tumor, or gastrointestinal stromal tumor (GIST).

We present a rare case of appendiceal schwannoma and review previously reported cases to highlight diagnostic considerations.

### CASE PRESENTATION

A 40-year-old female presented with abdominal pain of 2-week duration. There was no history of fever, vomiting, altered bowel habits, or weight loss. She had no significant comorbidities.

On examination, the patient was hemodynamically stable. Vital signs were within normal limits. Abdominal examination revealed mild tenderness in the right iliac fossa without guarding, rigidity, or palpable mass. No organomegaly was noted.

Laboratory investigations, including complete blood count, inflammatory markers, and serum carcinoembryonic antigen, were within normal limits. Contrast-enhanced computed tomography of the abdomen was performed at an outside center. Although imaging films were not retrievable, the official radiology report described a well-defined right iliac fossa mass arising from the appendiceal region. Owing to the large size of the lesion and its radiological appearance, a clinical impression of appendiceal carcinoma or urachal carcinoma was made. No peritoneal deposits or distant metastasis were identified.

The patient subsequently presented to our institution and underwent laparoscopic radical appendectomy. Intraoperatively, the appendix appeared markedly enlarged without evidence of peritoneal deposits or dissemination.

Gross examination revealed an appendix measuring 11.7 cm in length and 6.5 cm in maximum diameter. Cut section showed a firm yellowish tumor measuring 10.7 cm, involving the body and tip, with relative sparing of the proximal segment (Fig. 1a).

Histopathology demonstrated a spindle cell neoplasm arranged in intersecting fascicles. Tumor cells exhibited elongated nuclei, moderate eosinophilic cytoplasm, and focal nuclear palisading consistent with Antoni A areas. Mitotic figures were sparse, and no necrosis or significant atypia was identified (Fig. 1b and c).

Immunohistochemistry showed diffuse strong nuclear positivity for SOX10 (Fig. 1d). CD117 and

#### Access this article online

Received - 18 January 2026  
Initial Review - 13 February 2026  
Accepted - 22 March 2026

#### Quick Response code



DOI: \*\*\*

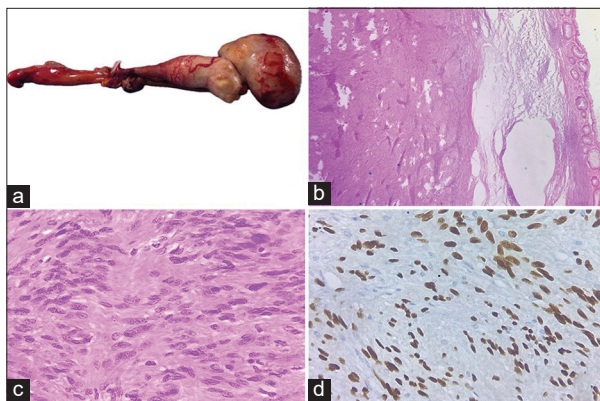
**Correspondence to:** Dr. Shehla Basheer Kollathodi, Department of Pathology, Aster MIMS, Calicut - 673 016, Kerala, India. E-mail: famsonline@gmail.com

© 2026 Creative Commons Attribution-NonCommercial 4.0 International License (CC BY-NC-ND 4.0).

**Table 1: Summary of reported appendiceal schwannoma cases**

Author (Year)	Age/ Sex	Size (cm)	Presentation	Clinical diagnosis	IHC	Treatment/Follow-up
Doyle <i>et al.</i> [1]	62/F	5.0	RIF pain, weight loss	Appendiceal carcinoma	S100, SOX10	Right hemicolectomy; no recurrence
Cheng <i>et al.</i> [2]	55/F	4.5	RIF pain, nausea	Appendiceal neoplasm	S100, SOX10	Appendicectomy; no recurrence
Jeong [3]	52/F	2.8	Acute appendicitis	Acute appendicitis	S100, SOX10	Appendicectomy; no recurrence
Hendriks <i>et al.</i> [4]	38/M	NR	Perforated appendix	Appendicitis/perforation	S100	Appendicectomy; no recurrence
Markey <i>et al.</i> [5]	NR	NR	Incidental finding	Appendiceal mass	S100	Appendicectomy; no recurrence
Nishio <i>et al.</i> [6]	67/F	2.0	Incidental (FDG-PET/CT)	Appendiceal tumor	S100	Appendicectomy; no recurrence
Suh <i>et al.</i> [7]	45/M	3.5	RIF pain	Appendicitis	S100	Laparoscopic appendicectomy; no recurrence
<b>Present case</b>	<b>40/F</b>	<b>10.7</b>	<b>Abdominal (RIF) pain</b>	<b>Appendiceal/urachal carcinoma</b>	<b>SOX10</b>	<b>Laparoscopic radical appendicectomy; asymptomatic at 6 months</b>

NR: Not reported, RIF: Right iliac fossa, IHC: Immunohistochemistry, FDG: Fluorodeoxyglucose, PET/CT: Positron emission tomography/computed tomography, M: Male, F: Female.



**Figure 1: (a) Diffusely enlarged appendix with tumor involving the body and tip; (b and c) Spindle cell neoplasm in fascicles. Tumor cells showing nuclear palisading. (d) Tumor cells showing diffuse nuclear positivity for SOX10**

high-molecular-weight caldesmon (H-caldesmon) were negative. The overall features were diagnostic of appendiceal schwannoma.

The post-operative course was uneventful. At 6-month follow-up, the patient remains asymptomatic with no evidence of recurrence.

## DISCUSSION

Appendiceal schwannomas are extremely rare benign tumors. Doyle *et al.* reviewed 14 previously reported cases up to 2023 [1]. Subsequent individual case reports have been published, and fewer than 20 well-documented cases are currently available in the English literature [2-7]. A summary of reported appendiceal schwannoma cases is presented in Table 1.

Most patients present with abdominal pain or appendicitis-like symptoms [1-3]. Most reported tumors range between 2 cm and 5 cm. The present case, measuring 10.7 cm,

represents one of the largest appendiceal schwannomas described in the literature. Preoperative diagnosis is uncommon, and these lesions are frequently interpreted as appendiceal carcinoma, neuroendocrine tumor, GIST, or complicated appendicitis [2,3,6]. In the present case, the relatively large tumor size and imaging findings led to a preoperative clinical impression of carcinoma.

Histologically, appendiceal schwannomas demonstrate classical spindle cell morphology with Antoni A areas and nuclear palisading [3,8]. Immunohistochemistry is essential for diagnosis. Diffuse SOX10 and/or S100 positivity confirms neural differentiation, while the absence of CD117 and DOG1 excludes GIST [3,8]. No association with neurofibromatosis has been reported in appendiceal cases to date [1].

Complete surgical excision is curative, and recurrence has not been reported following adequate resection [1,2].

## CONCLUSION

Appendiceal schwannoma is a rare benign spindle cell neoplasm that may clinically and radiologically mimic malignant appendiceal tumors. Definitive diagnosis relies on histopathological and immunohistochemical evaluation. Surgical excision is curative, and prognosis is excellent.

## REFERENCES

- Doyle JP, Bhogal RH, Terlizzo M, Mavroeidis VK. Appendiceal schwannoma - report of a case and literature review. *Ir J Med Sci* 2023;192:1801-5.
- Cheng E, Oliphant R, Fung C, Rickard M, Keshava A. Schwannoma of the appendix: A case report and review of the literature. *Surg Pract* 2018;22:81-3.
- Jeong MJ. Appendiceal schwannoma presenting as acute appendicitis. *Radiol Case Rep* 2022;18:775-8.

4. Hendriks T, Ballal H, McCallum DD. Appendiceal schwannoma: A rare cause of perforated appendicitis. *BMJ Case Rep* 2018;2018:bcr2018226065.
5. Markey W, Blundell J, Law C, Warner R. Beyond mere appendicitis: A case report on an unforeseen diagnosis of appendiceal schwannoma. *Surg Case Rep* 2024;3:100068.
6. Nishio M, Tamaki T, Hara M, Shibamoto Y. Appendiceal schwannoma detected by FDG-PET/CT. *Clin Nucl Med* 2010;35:379-80.
7. Suh SW, Park JM, Choi YS, Cha SJ, Chang IT, Kim BG. Laparoscopic approach to a case of appendicular schwannoma. *J Korean Soc Coloproctol* 2010;26:302-6.
8. Miettinen M, Shekitka KM, Sobin LH. Schwannomas in the colon and rectum: A clinicopathologic and immunohistochemical study of 20 cases. *Am J Surg Pathol* 2001;25:846-55.

*Funding: Nil; Conflicts of interest: Nil.*

**How to cite this article:** Kollathodi SB, Hameed S, Abdulla F. Primary schwannoma of the appendix: A rare case report with brief review of literature. *Indian J Case Reports*. 2026; March 31 [Epub ahead of print].