

## De quervain tenosynovitis is an atypical presentation of Graves' disease

Ajit Kumar Pradhan<sup>1</sup>, Priyanka Giri<sup>2</sup>, Santosh Kumar Sahu<sup>3</sup>

From <sup>1</sup>Medical Officer, <sup>3</sup>Yoga Instructor, Department of AYUSH, All India Institute of Medical Sciences, Bhubaneswar, <sup>2</sup>Medical Officer, Department of Kaumarabhritya, Gopabandhu Ayurveda Mahavidyalaya and Hospital, Puri, Odisha, India

### ABSTRACT

De Quervain tenosynovitis is a commonly found wrist pain in women, usually occurring due to autoimmune diseases, overuse, infections and trauma. In Graves' disease, antibodies stimulate the thyroid gland, leading to diffuse enlargement of the thyroid gland and hypersecretion of thyroid hormones. The association between de Quervain tenosynovitis and Graves' disease is rarely discussed in the literature. We present the case of a 57-year-old female patient with Graves' disease with an uncommon initial feature and de Quervain tenosynovitis, before the manifestation of traditional symptoms, which delayed the diagnosis and treatment plan.

**Key words:** Autoimmune thyroid disease, De quervain tenosynovitis, Graves' disease, Hyperthyroidism, Tendinopathy

De Quervain tenosynovitis manifests as radial side wrist pain due to inflammation of the abductor pollicis longus and extensor pollicis brevis tendon sheath [1]. Graves' disease is an autoimmune thyroid disease that produces excessive thyroid hormones and affects multiple organs. In autoimmune diseases, self-reactive lymphocytes and antibodies infiltrate into the tendon sheath, causing inflammation [2]. There may be an association between tenosynovitis and Graves' disease; however, the etiopathologic relationship has yet to be elucidated.

Our case presents de Quervain tenosynovitis as a rare feature of Graves' disease, and shedding light on unusual associations. That can be suggested as a new hypothesis for further research.

### CASE DESCRIPTION

On June 20<sup>th</sup>, 2025, a 57-year-old female patient presented with a 2-month history of right wrist pain, especially over the radial side. Pain worsened by movement of the right thumb. She also complained of palpitation, weakness, and diarrhea for the last 10 days. She consulted the nearby primary health center for diarrhea and continued metronidazole, ofloxacin, prebiotics, and probiotics, but did not improve. She reported a 7-kg weight loss from 54 kg to 47 kg within 2 weeks. Previously, on June 5<sup>th</sup>, 2025, she complained of the same symptoms and

was treated with cold compression and a non-steroidal anti-inflammatory drug. She had no previous history of diabetes mellitus, hypertension, hypothyroidism, or other systemic illnesses. She denied any previous surgery or injury. She denied the lifting of a baby and the mechanical overuse of the thumb in her daily activities.

Upon examination, her systolic and diastolic blood pressures were 96 mmHg and 72 mmHg, respectively. Heart rate was 112 beats/min, regular. Oral body temperature was 99.6°F. Mild swelling over the anterior side of the neck was marked during inspection. Palpation confirmed the diffuse enlargement of the thyroid gland, which was smooth, non-tender, and the margins were well demarcated. She was a right-handed predominant woman, having a sedentary lifestyle and a housewife in occupation. Physical examination revealed mild swelling and tenderness over the radial side of the right wrist. She was found positive for Finkelstein's test and the WHAT test. Ophthalmopathy, dermopathy, and tremor were absent. Appetite was good. No signs of pallor, icterus, cyanosis, clubbing, koilonychia, lymphadenopathy, and edema were found.

Digital X-ray of the right wrist revealed no fracture and bone deformities, but noted soft tissue swelling over the radial styloid process. The above-mentioned findings confirmed the diagnosis of de Quervain's tenosynovitis of the right wrist. Hematological and biochemistry investigations results before treatment are mentioned in Table 1. Ultrasonography of the neck revealed diffuse goiter with increased parenchymal vascularity. Thyroid

Access this article online

Received - 16 October 2025  
Initial Review - 01 November 2025  
Accepted - 22 December 2025

Quick Response code



DOI: 10.32677/ijcr.v12i1.7909

**Correspondence to:** Ajit Kumar Pradhan, Department of AYUSH, All India Institute of Medical Sciences, Bhubaneswar - 751019, Odisha, India. Email: ayush\_ajit@aiimsbhubaneswar.edu.in

© 2026 Creative Commons Attribution-NonCommercial 4.0 International License (CC BY-NC-ND 4.0).

**Table 1: Hematological and biochemistry investigation results before treatment**

Tests	Results	Reference value
Hemoglobin	12.6 g/dL	13–17 g/dL
TLC	5850/cumm	4000–11000/cumm
ESR	22 mm 1 <sup>st</sup> h	0–20 mm 1 <sup>st</sup> h
FBS	74 mg/dL	70–110 mg/dL
HBA <sub>1C</sub>	4.4%	4–6.5%
CRP	10.22 mg/L	< 1 mg/L
Free T3	11.0 pg/mL	2.3–4.2 pg/mL
Free T4	4.24 ng/mL	0.89–1.76 ng/mL
TSH	0.00500 microIU/mL	0.34–5.5 microIU/mL
Anti - TG	4000 U/mL	<60 IU/ml
Anti- TPO	590 U/mL	<60 U/mL
Urea	16 mg/dL	17–43 mg/dl
Creatinine	0.72 mg/dL	0.7–1.3 mg/dL
Uric acid	4.55 mg/dL	2.5–6.8 mg/dL
Sodium	143 mEq/L	135–145 mEq/L
Potassium	4.19 mEq/L	3.5–5 mEq/L
Chloride	106 mMol/L	102–109 mMol/L
Total calcium	9.3 mg/dL	9–11 mg/dL
Total bilirubin	0.37 mg/dL	0.3–1.2 mg/dL
AST	35 U/L	5–50 U/L
ALT	19 U/L	5–50 U/L
ALP	71 U/L	30–120 U/L
Total protein	7.2 g/dL	6.7–8.6 g/dL

TLC: Total leucocyte count, ESR: Erythrocyte sedimentation rate, FBS: Fasting blood sugar, HBA<sub>1C</sub>: Glycosylated hemoglobin, CRP: C reactive protein, TSH: Thyroid stimulating hormone, Anti TG: Anti-thyroglobulin antibody, Anti TPO- Anti-thyroid peroxidase antibody, AST: Aspartate aminotransferase, ALT: Alanine aminotransferase, ALP: Alkaline phosphatase, g/dL: Gram per deciliter, cumm: Per cubic millimeter, mm: Millimeter, mg/dL: Milligram per deciliter, mg/L: Milligram per liter, pg/mL: Picogram per milliliter, ng/mL: Nanogram per milliliter, microIU/mL: Micro international unit per milliliter, U/mL: Unit per milliliter, U/L: Unit per liter, mEq/L: Milli-equivalent per liter, mMol/L: Milli mole per liter

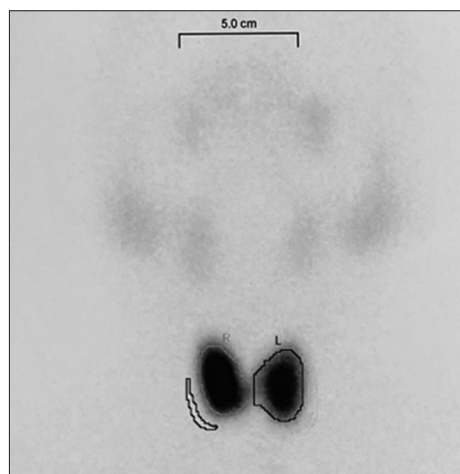
scintigraphy showed increased thyroid uptake and thyroid parotid ratio, suggesting Graves' disease (Fig. 1).

She was treated with tablet carbimazole 30 mg once daily before breakfast and tablet propranolol 10 mg thrice daily after food for 2 months. Pain, tenderness, and swelling over the right wrist disappeared after 1 week of treatment. On August 25<sup>th</sup>, 2025, after 2 months of follow-up, no symptoms were reported, and the thyroid-stimulating hormone, free T3, and free T4 values were 11.5 µIU/mL, 2.50 pg/mL, and 0.581 ng/mL, respectively.

## DISCUSSION

De Quervain's tenosynovitis is characterized by pain and inflammation in the region of the radial styloid. Repetitive and continued strain of tendons of abductor pollicis longus and extensor pollicis brevis, which pass through the thickened and swollen extensor retinaculum, causes pain over the radial side of the wrist exacerbated by movement of the thumb [3].

Graves' disease is a common cause of hyperthyroidism in women. It is due to autoimmune activation of the thyroid gland, causing diffuse enlargement of the

**Figure 1: Thyroid scintigraphy**

thyroid gland and hyperfunction of the gland [4]. The systemic manifestations of this disease are due to involvement of heart, skeletal muscles, eyes, skin, bone, and liver. Tendinopathy is more commonly associated with hypothyroidism. Primary differential diagnoses of a patient with symptoms of Graves' disease include tendinopathy, rheumatoid arthritis, gout, psoriatic arthritis, peripheral spondyloarthritis, and amiodarone-induced tendinopathy.

The relationship between Graves' disease and tendinopathies is not properly established, and it is a very rare manifestation. However, some orthopedic surgeons described the link between autoimmune thyroid diseases and tenosynovitis [5]. In our case, the symptoms started as unilateral de Quervain tenosynovitis, and after that, the common symptoms of Graves' disease developed.

The tendon sheath is composed of an outer fibrous layer and an inner synovial layer. The synovial layer consists of the outer parietal layer and the inner visceral layer [6]. Autoimmune diseases, overuse, infections, and trauma are the common etiologies for tenosynovitis. Rheumatoid arthritis, psoriatic arthritis, diabetes, thyroid disease, Dupuytren's contracture, fibromyalgia, and hand infections are the risk factors for tenosynovitis [7]. For our patient, an autoimmune condition may be a factor for tenosynovitis. Several studies show that rheumatoid arthritis and psoriatic arthritis are commonly associated with tenosynovitis [8,9]. Metabolic factors are more prevalent in non-athletic individuals with tendinopathy.

Use of antibiotics like fluoroquinolones increases the risk of tendinopathy. Specific occupations, including forceful repetitive activities, are associated with an increased risk of developing tendinopathy. Individuals such as food industry workers, assembly line packers, construction workers, sewing machine operators, musicians, cooks, and surgeons are more susceptible. Genetic factors also have an important role in tendon homeostasis and in the balance between repair and degeneration of the tendon injury.

Another possible cause may be in autoimmune diseases, tenosynovitis is initiated when activated T cells interact with macrophages, dendritic cells, and synoviocytes in the tendon sheath [10]. In some studies, it has been found that autoimmune thyroid disease is associated with musculoskeletal manifestations and chronic pain disorders [11]. Repetitive tendon overload leads to structural injury of the microscopic collagen fibrils. Initial structural alterations are typically clinically silent, progressive accumulation of matrix damage and the secreted cytokines, chemokines, inflammatory mediators, and activated nociceptors eventually lead to symptom manifestation. Reactive oxygen species are believed to impose cellular or tissue damage through lipid peroxidation, protein modification, DNA strand cleavage, and oxidative base modification, which may have a role in tendinopathy development. In autoimmune diseases, a dysregulated immune response occurs, where inflammatory mediators and immune cells create a harmful microenvironment within the tendon tissue, leading to degeneration and impaired healing. We present this case to further elucidate the relationship between de Quervain tenosynovitis and Graves' disease, especially autoimmune thyroid disease.

## CONCLUSION

We report a case of Graves' disease that presented initially with a complaint of de Quervain tenosynovitis, which is a rare symptom. In patients with Graves' disease who complaint of tendinopathy, it is important to consider the disease mechanism and the presence of other concomitant diseases. Graves' disease could be a differential diagnosis in patients who present with tenosynovitis.

## REFERENCES

1. Fakoya AO, Tarzian M, Sabater EL, Burgos DM, Maldonado Marty GI. De Quervain's disease: A discourse on etiology, diagnosis, and treatment. *Cureus* 2023;15:e38079.
2. Antonelli A, Fallahi P, Elia G, Ragusa F, Paparo SR, Ruffilli I, *et al.* Graves' disease: Clinical manifestations, immune pathogenesis (cytokines and chemokines) and therapy. *Best Pract Res Clin Endocrinol Metab* 2020;34:101388.
3. Larsen CG, Fitzgerald MJ, Nellans KW, Lane LB. Management of de quervain tenosynovitis: A critical analysis review. *JBJS Rev* 2021;9:e21.00069.
4. Pokhrel B, Bhusal K. Graves disease. In: StatPearls. StatPearls Publishing; 2025. Available from: <https://www.ncbi.nlm.nih.gov/books/nbk448195> [Last accessed on 2025 Aug 15].
5. Llaneras N, Ross V, Miki R. Trigger finger: An unusual clue to Hashimoto's thyroiditis. *Cureus* 2024;16:e71143.
6. Fussey JM, Chin KF, Gogi N, Gella S, Deshmukh SC. An anatomic study of flexor tendon sheaths: A cadaveric study. *J Hand Surg Eur Vol* 2009;34:762-5.
7. Muthu S, Annamalai S, Kandasamy V. Tenosynovitis of hand: Causes and complications. *World J Clin Cases* 2024;12:671-6.
8. Rogier C, Hayer S, Van Der Helm-Van Mil A. Not only synovitis but also tenosynovitis needs to be considered: Why it is time to update textbook images of rheumatoid arthritis. *Ann Rheum Dis* 2020;79:546-7.
9. McQueen F, Lassere M, Østergaard M. Magnetic resonance imaging in psoriatic arthritis: A review of the literature. *Arthritis Res Ther* 2006;8:207.
10. Izumiyama T, Miyazawa M. Importance of tenosynovitis in preventing the progression through rheumatoid arthritis continuum. *Mod Rheumatol* 2023;33:868-74.
11. Tagoe CE, Wang W, Barbour KE. Association of the anti-thyroid peroxidase antibody with chronic hand pain in older adults in the third national health and nutrition examination survey: A cross-sectional study. *Ther Adv Musculoskelet Dis* 2023;15:1759720X231154984.

*Funding: Nil; Conflicts of interest: Nil.*

**How to cite this article:** Pradhan AK, Giri P, Sahu SK. De quervain tenosynovitis is an atypical presentation of Graves' disease. *Indian J Case Reports*. 2026; 12(1):29-31.