

Bowel Evisceration through Vaginal Vault Following Vaginal Hysterectomy - A Case Report

Sendhil Coumary Arumugam, Rani Reddi

Department of Obstetrics and Gynaecology, Mahatma Gandhi Medical College, Sri Balaji Vidhyapeeth University, Puducherry, India

Correspondence to: Rani Reddi, Department of Obstetrics and Gynaecology, Mahatma Gandhi Medical College, Sri Balaji Vidhyapeeth University, Puducherry, India. E-mail: sreaddiranip@mgmcri.ac.in

Received – 29 August 2017

Initial Review – 27 September 2017

Published Online – 28 December 2017

ABSTRACT

Bowel evisceration through vaginal vault is a rare but serious complication of pelvic surgery specifically hysterectomy. It represents a surgical emergency and is associated with significant morbidity. Small bowel is the most common viscous to eviscerate. The present case is report of small bowel evisceration through vaginal vault in the immediate post-operative period managed vaginally. Bowel evisceration through vaginal vault following vaginal cuff dehiscence is a rare and serious complication of pelvic surgery; specifically, hysterectomy. Small bowel is the most common viscous to eviscerate. Bowel evisceration is usually managed abdominally either laparoscopically or by a laparotomy. We present a case of small bowel evisceration through vaginal vault in the immediate post-operative period which was managed vaginally.

Key words: *Vaginal evisceration, post operative, small bowel*

Bowel evisceration through vaginal vault following vaginal cuff dehiscence is a rare and serious complication of pelvic surgery; specifically, hysterectomy. Small bowel is the most common viscous to eviscerate. Bowel evisceration is usually managed abdominally either laparoscopically or by a laparotomy. We present a case of small bowel evisceration through vaginal vault in the immediate post-operative period which was managed vaginally.

CASE REPORT

A 45-year-old multiparous woman presented to the outpatient with a history of heavy menstrual bleed for the past 1 year. During the past year, she has been experiencing increase in frequency of menstrual cycles along with severe pain during cycles. Her previous menstrual cycles were regular with no pain. On examination, except for the marked pallor, the patient was otherwise normal. Gynecological examination revealed a uniformly enlarged, tender uterus of 14 weeks gravid uterus size. Both adnexa were normal. Her blood investigations revealed severe degree of iron deficiency anemia. Pelvic ultrasound showed uterus with features of adenomyosis with normal ovaries.

Anemia was corrected with red blood cells transfusions. It was planned for a vaginal hysterectomy. The patient underwent vaginal hysterectomy under spinal anesthesia uneventfully. The immediate post-operative recovery was good. She voided urine freely once the in-dwelling Foley's catheter was removed 6 h after surgery. The patient was ambulating normally, taking orally well and passed stools on post-operative day 2. The patient was planned

for discharge. On post-operative day 3, she complained of mass descending per vaginum after visiting the toilet. The patient was well and had no pain. On examination, she was stable. Abdomen was soft with normal bowel sounds. Speculum examination revealed a few loops of bowel eviscerating through the vaginal vault. The bowel was pink showing active peristalsis (Fig. 1).

The patient was counseled regarding the need for reexploration and possible laparotomy and shifted for examination under anesthesia. Under anesthesia in Trendelenburg position, the bowel was examined. Bowel looked normal with no evidence of strangulation. It was easily reducible back into the peritoneal cavity. The vaginal vault was examined after reducing the bowel; it appeared clean with no evidence of infection. The vault was closed vaginally with interrupted stitches using delayed absorbable material. The procedure was covered with broad-spectrum antibiotics. The post-operative recovery was uneventful. The iron deficiency was corrected with iron infusions. She was reviewed after 6 weeks, the vault having healed completely.

DISCUSSION

Evisceration of bowel through vaginal vault is disruption of the vaginal vault or apex with extrusion of intraperitoneal contents [1]. Vault dehiscence predisposes to evisceration. Small bowel is the most common viscous to eviscerate [2]. Vaults evisceration is a surgical emergency requiring immediate resuscitation and surgical intervention. The actual incidence of evisceration through vaginal vault is likely to be higher than published reports. The earliest reports of vaginal evisceration

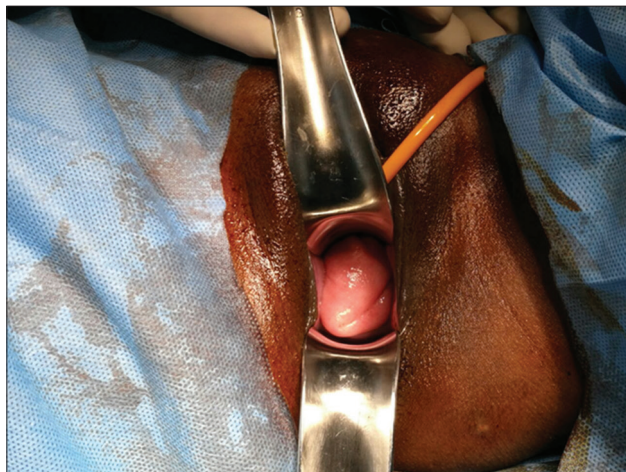


Figure 1: pink peristaltic bowel protruding through the vaginal vault seen in the literature are a complication of vaginal hysterectomy. However, now, it is scantily reported. Currently, the reported cases are after laparoscopic or robotic hysterectomies. Iaco *et al.* reported an overall incidence of 0.28% [2]. They also concluded that there were no statistical differences according to the route of surgery or closure versus non-closure of vault.

Hur *et al.* reported an incidence of vaginal dehiscence of 4.93% among total laparoscopic hysterectomies, 0.29% among vaginal, and 0.12% among abdominal hysterectomies [3]. 60% of these patients presented with both dehiscence and bowel evisceration. The most common risk factors are postmenopausal atrophy, presence of enterocele, or previous vaginal surgeries. Other risk factors include cuff infection or hematoma, poor surgical technique or factors interfering with healing such as diabetes, immunosuppression, steroid therapy, malignancy, and malnutrition [3,4]. Post-hysterectomy the vaginal axis is no longer horizontal, it becomes vertical. Hence, the vaginal apex takes the direct effect of any increase in intra-abdominal pressure. Furthermore, in the presence of an untreated enterocele, a sudden increase in the intra-abdominal pressure causes the enterocele sac to weaken and rupture [5]. It is generally agreed that peritoneum heals by 5–6 days after surgery or wounding. Smaller defects heal earlier. However, in the presence of factors that interfere with healing, healing may be delayed [6].

Patients with vaginal cuff dehiscence can present with pain, vaginal bleeding, foul-smelling discharge, and pelvic pressure [3]. In the presence of evisceration, they can present with an obvious mass protruding from the vagina. Small bowel, especially terminal ileum, is the common content; however, omentum, fallopian tubes, and appendix have been reported to eviscerate. The median time to eviscerate is different for the various routes of hysterectomy, the earliest being for total laparoscopic hysterectomy. Reports of immediate post-operative evisceration are rare. A case of evisceration during the third post operative day was reported following large loop excision of the transformation zone, similar to the present case [7]. Many of the review articles do not report about the time taken to vault evisceration from the time of surgery.

At present, there is no clear consensus as to the route of surgery for vault evisceration. In 2011, Preethi Gandhi in a review article

has given an algorithm for the management vaginal vault of evisceration [1]. In the present case, vaginal route of exploration was started with keeping laparotomy in mind if there was any difficulty in reducing the bowel contents back or any ischemic bowel. Fortunately, as the vaginal defect postsurgery was around 4 cm and the bowel loop that prolapsed out was seven to 8 cm long with active peristalsis and freely reducible, the procedure was completed vaginally. Literature does not support one route of approach over the other. Method of repair depends on the whether there is ischemia or damage to bowel, whether vaginal mucosa can be visualized and approximated. However, a combined approach would help in exploring the entire bowel to rule out ischemic bowel and also in approximating the vaginal edges, identifying untreated enterocele and managing them in the same sitting provide the patient is hemodynamically stable and will withstand long procedures. Recurrence of vault cuff dehiscence has also been reported [8]. Identifying risk factors leading to dehiscence need to be addressed to prevent further dehiscence.

CONCLUSION

Bowel evisceration through vaginal vault is rare but a serious complication of pelvic surgery specifically hysterectomy. Incidence is likely to be more than actually reported. Much of the information about pelvic evisceration is got from case reports. Initial reports are with vaginal hysterectomy; however, currently, most of the cases are related to laparoscopic or robotic hysterectomies. There are no standard treatment protocols available for vaginal vault evisceration at present.

REFERENCES

1. Gandhi P, Jha S. Vaginal vault evisceration. *Obstet Gynecol* 2011;13:231-7.
2. Iaco PD, Ceccaroni M, Alboni C, Roset B, Sansovini M, D'Alessandro L, *et al.* Transvaginal evisceration after hysterectomy: Is vaginal cuff closure associated with a reduced risk? *Eur J Obstet Gynecol Reprod Biol* 2006;125:134-8.
3. Hur HC, Guido RS, Mansuria SM, Hacker MR, Sanfilippo JS, Lee TT. Incidence and patient characteristics of vaginal cuff dehiscence after different modes of hysterectomies. *J Minim Invasive Gynecol* 2007;14:311-7.
4. Cronin B, Sung VW, Matteson KA. Vaginal cuff dehiscence: Risk factors and management. *Am J Obstet Gynecol* 2012;206:284-8.
5. Afifi R, Sayed AT. Post-hysterectomy vaginal vault prolapse. *Obstet Gynecol* 2005;7:89-97.
6. diZerega GS, Campeau JD. Peritoneal repair and post-surgical adhesion formation. *Hum Reprod Update* 2001;7:547-55.
7. Ghassani A, Andre B, Simon-Toulza C, Tanguy le Gac Y, Martinez A, Vidal F. Vaginal evisceration: An unexpected complication of conization. *Case Rep Obstet Gynecol* 2014;2014:983682.
8. Ribeiro SP, Silva AC, Maciel J, Antunes AS. Spontaneous transvaginal evisceration: A case of recurrence. *BMJ Case Rep* 2016. DOI: 10.1136/bcr-2015-211659.

Funding: None; Conflict of Interest: None Stated.

How to cite this article: Arumugam SC, Reddi R. Bowel Evisceration through Vaginal Vault Following Vaginal Hysterectomy - A Case Report. *Indian J Case Reports*. 2018;4(1):20-21.