

## Left renal agenesis with left ectopic ureter opening into vas deferens with urinary tract infection: Managed conservatively - A rare case report

Swanand S Rewatkar<sup>1</sup>, Vaishali P Paunekar<sup>2</sup>, Sneha D Shendre<sup>3</sup>, Yogesh R Barapatre<sup>4</sup>

From <sup>1</sup>Consultant Pediatrician and Neonatologist, <sup>2</sup>Consultant Obstetrician and Gynecologist, <sup>3</sup>Department of Medicine, <sup>4</sup>Consultant Urologist, Lotus Advanced Urology Center, Raipur, Chhattisgarh, India

**Correspondence to:** Swanand S Rewatkar, 102, Mangaldeep Apartment, Plot No. 77/B, Hanuman Nagar, Nagpur, Maharashtra, India. Phone: +91-9423625375. E-mail: drswanandsr@yahoo.com

Received - 10 July 2017

Initial Review - 25 July 2017

Published Online - 17 August 2017

### ABSTRACT

Renal agenesis with an ectopic ureter draining into the reproductive system is a rare entity. It usually presents before third decade of life. We are reporting a case of delayed presentation of left renal agenesis with ectopic ureter opening into the vas deferens without infertility presenting due to urinary tract infection and managed conservatively.

**Key words:** Ectopic ureter, Hypo plastic seminal vesicle, Renal agenesis, Urinary tract infection

An ectopic ureter has an orifice located outside the normal trigonal position with an uncertain prevalence, most of them being asymptomatic [1]. A rare variety of ectopic ureter is the ureter draining into the genital system [2]. Congenital vas deferens-ureteral connection presenting in the fourth decade of life is itself a rare possibility; although, it should be suspected in the children presenting with epididymitis, scrotal infections, and urinary incontinence [3,4]. The goal of treatment for patients with ectopic ureters who are presenting late is to ameliorate their symptoms as expeditiously as possible [5]. Most of these patients may need surgical intervention to alleviate the symptoms. This report describes a rare case of late presentation of the left renal agenesis with ectopic ureter opening into the vas deferens without infertility associated with repeated episodes of urinary tract infection (UTI) responded to the conservative management.

### CASE REPORT

A 37-year-old-married male patient, father of two children, presented with complaint of pain in the left iliac fossa and perineum for 1 month. He has previous history of dysuria and increased frequency of micturition for 1 year. On clinical examination, he had mild tenderness in left iliac fossa. His testis and vas deferens appeared to be normal bilaterally.

His routine blood investigations were normal. His urine routine examination shows plenty of pus cells and semen culture grew *Escherichia coli*. He was initially treated with analgesics and antibiotics but did not receive any benefit. Hence, he was further investigated. He was evaluated with the contrast-enhanced computed tomography (CT) of urogenital tract, in which, he was found to have left renal agenesis (Fig. 1) with marked dilatation (13 mm) and tortuosity of the middle and distal third segment

of dysplastic left ureter (Fig. 2) draining into the vas deferens with moderate dilatation (8 mm) of terminal segment of left vas deferens (Fig. 3). His left seminal vesicle was markedly hypoplastic. After confirming the diagnosis, he was started on the culture sensitive antibiotics for duration of 1 month and was asked to follow-up regularly. He responded to the treatment well in 10 days of antibiotic course. On follow up, the patient was placed on prophylactic antibiotic trimethoprim for 3 months. Now, he is following regularly for the past 1 year without any recurrence of the symptoms.

### DISCUSSION

Ectopic ureter draining into the reproductive system is a rare entity occurring because of a more cranial origin of the ureteral bud from the mesonephric duct and the resultant ureteral stump opening in the mesonephric duct derivatives, i.e., seminal vesicles, ejaculatory ducts, or vas deferens [1,2]. During the fetal development, ureteral bud arises from the distal Wolffian duct and grows in cephalic direction to invaginate the portion of the nephrogenic mass that will eventually become the kidney. Because the ureter arises as a bud from the Wolffian duct, a common channel connects both structures to the urogenital sinus. Eventually, this common channel is assimilated, resulting in the ureter, and future vas deferens entering separately into the primitive bladder. The part of the primitive bladder that receives the vas deferens is the precursor of the posterior urethra and carries the orifice of the vas deferens to its final position at the verumontanum. Here, if the portion of the Wolffian duct receiving both the ureter and vas deferens fails to obliterate then it can result in ectopy of the vas deferens into the ureter (or of the ureter into the genital tract) as has also been observed [6].

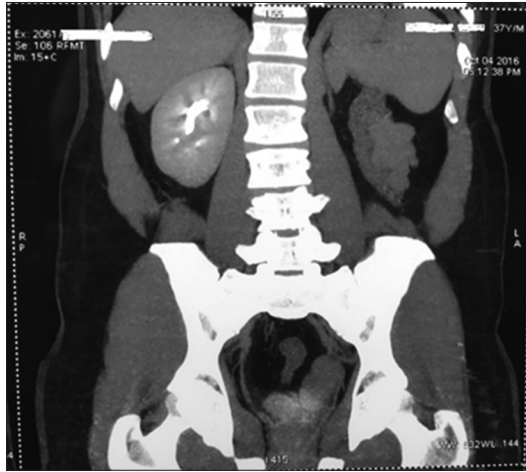

Figure 1: Left renal agenesis

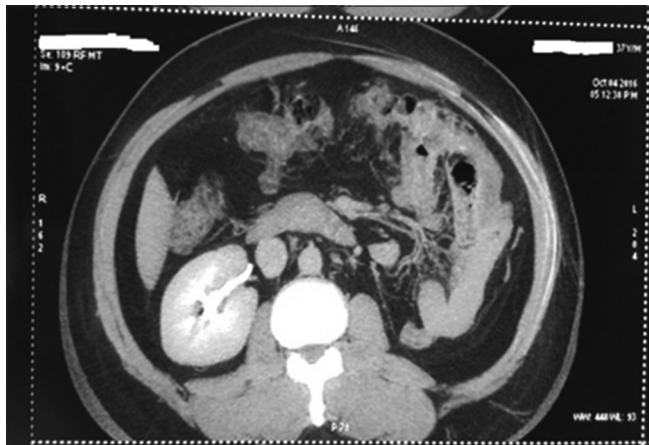

Figure 2: Dilated left ureter

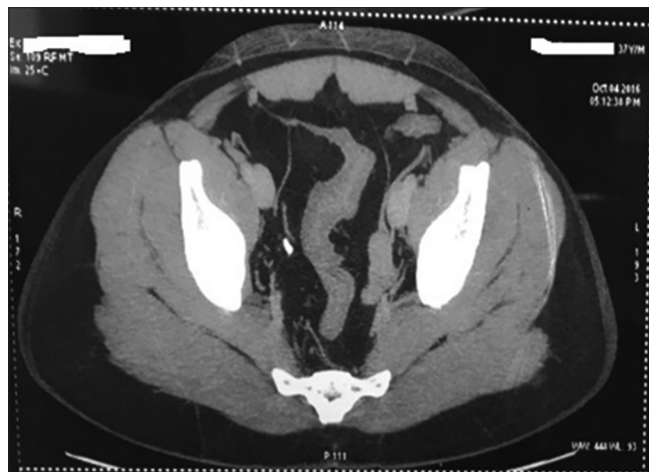


Figure 3: Left ureter opening in left vas deferens

Although ectopic ureters are more common in females and present early with incontinence [3,4], their presentation is often delayed in males to early adulthood [6]. The commonly reported symptoms are perineal or pelvic pain, UTI, prostatitis, epididymitis, hematuria, hematospermia, and infertility [7,8].

Our patient was investigated for persistent pain in the left iliac fossa and perineum along with the history of repeated episodes of dysuria and frequent urination. In men, ectopic ureteral implantation into the seminal system (seminal vesicle, ejaculatory duct, vas deferens, or epididymis) tends to present with peak incidence in the third decade of life through symptoms associated with voiding, ejaculation, or pain of the perineum or genitals. Several imaging techniques have been used in the evaluation of these anomalies. A CT scan can demonstrate the cystic pelvic mass and reveal the associated renal anomalies. Conservative management is recommended for asymptomatic to mild cases; more severe cases typically require surgical treatment, for which laparoscopic and robotic approaches are becoming increasingly favored [9].

## CONCLUSION

Due to the proximity during the intrauterine development, the aberrant course of urinary system development may cause cross connection with the genital system leading to opening of the ectopic ureter in the seminal vesicle and secondary agenesis of the renal tissue. Clinical presentation may be delayed and remain unnoticed till the third-or-fourth decade of life. Contrast-enhanced CT scan is the useful fast imaging technique for the diagnosis. Appropriate conservative treatment with regular follow-up can avoid the need for the invasive urological intervention.

## REFERENCES

- Schlüssel RN, Retik AB. Ectopic ureter, ureterocele, and other anomalies of the ureter. In: Campbell-Walsh Urology. 9<sup>th</sup> ed., Vol. 4. Philadelphia, PA: WB Saunders; 2007. p. 3383-422.
- Buogo G, Rodrigues H, Rodrigues P. Laparoscopic removal of seminal vesicle cyst with ectopic ureteral insertion and renal remnant. *Int Braz J Urol.* 2002;28(4):335-7.
- Freedman ER, Rickwood AM. Urinary incontinence due to unilateral vaginally ectopic single ureters. *Br J Urol.* 1994;73(6):716-7.
- Umeyama T, Kawamura T, Hasegawa A, Ogawa O. Ectopic ureter presenting with epididymitis in childhood: Report of 5 cases. *J Urol.* 1985;134(1):131-3.
- Duong DT, Shortliffe LM. A case of ectopic dysplastic kidney and ectopic ureter diagnosed by MRI. *Nat Clin Pract Urol.* 2008;5(11):632-6.
- Saifee Y, Modi P. Adult Presentation of ectopic vas deferens with dysplastic kidney. *J Endourol Case Rep.* 2016;2(1):6-7.
- Arora SS, Breiman RS, Webb EM, Westphalen AC, Yeh BM, Coakley FV. CT and MRI of congenital anomalies of the seminal vesicles. *AJR Am J Roentgenol.* 2007;189(1):130-5.
- Livingston L, Larsen CR. Seminal vesicle cyst with ipsilateral renal agenesis. *AJR Am J Roentgenol.* 2000;175(1):177-80.
- Boswell TC, Marien T, Herrell SD. Ectopic ureteral insertion into the seminal vesicle causing recurrent epididymitis in a 24-year-old. *J Endourol Case Rep.* 2015;1(1):14-6.

*Funding: None; Conflict of Interest: None Stated.*

**How to cite this article:** Rewatkar SS, Paunekar VP, Shendre SD, Barapatre YR. Left renal agenesis with left ectopic ureter opening into vas deferens with urinary tract infection: Managed conservatively - A rare case report. *Indian J Case Reports.* 2017;3(4):190-191.