

Valproate-induced reactive lymphoid hyperplasia in pediatric population: A rare case report

Kanwardeep Kaur¹, Mohanvir Kaur², Sanya Jain³

From ¹Assistant Professor, ²Associate Professor, ³Junior Resident, Department of Pathology, Government Medical College, Patiala, Punjab, India

ABSTRACT

Certain drugs may give rise to lymph node enlargement, predominantly in the neck known as drug-induced lymphadenopathy which may be associated with the involvement of DRESS syndrome (Drug Reaction with Eosinophilia and Systemic Symptoms) of drug reaction with eosinophilia and systemic symptoms also known as drug-induced hypersensitivity syndrome. It can also resemble lymphoma morphologically and this condition is known as pseudolymphoma. Valproate, a broad-spectrum antiepileptic, also used in bipolar disorders and migraine prophylaxis, is generally well tolerated. To date, very few cases of valproate monotherapy-induced lymphoid hyperplasia have been reported worldwide. Here, we are reporting one such rare case in a 13-year-old Indian male child who developed cervical lymphoid hyperplasia following the use of sodium valproate for 5 months for a seizure disorder.

Key words: Drug-induced, Lymphadenopathy, Valproate

Lymphadenopathy is a common clinical presentation of patients attending outdoor patient departments which can be due to inflammation, metastatic malignancy, or lymphoma [1]. Epilepsy is one of the major neurologic problems facing both developing and developed countries. It affects approximately 10 million children younger than 15 years of age [2]. Antiepileptic drugs (AEDs) are among the most frequent causes of adverse drug reactions (ADRs) in children, these reactions are often mild and tolerable. However, more severe, sometimes fatal, reactions can also occur [3]. Most of the epidemiological and clinical studies on ADRs to AEDs lack a clear description and differentiation between type A (predictable, dose-dependent, and pharmacologic associated) and type B reactions (unpredictable, not dose-dependent, and idiosyncratic), which mostly include drug hypersensitivity reactions [4].

Aromatic anticonvulsants such as carbamazepine, phenytoin, and lamotrigine have been the culprit drugs [5,6]. Although non-aromatic AEDs such as valproate were thought to be safer; there is 70% cross-reactivity between aromatic AEDs and non-aromatic AEDs [7]. Drug-induced lymphadenopathy has been recognized as a complication with AEDs. The first report of phenytoin-induced pseudolymphoma was published in 1940 [8]. Since then, this idiosyncratic reaction has also been described with carbamazepine, lamotrigine, nifedipine, captopril, and

methotrexate. Most of these drugs are associated with cutaneous pseudolymphomas but the AEDs are more likely to precipitate cervical lymphadenopathy.

CASE REPORT

A 13-year-old boy presented with non-painful swelling on the neck for the last month without any history of fever, weight loss, or trauma. The patient had been on sodium valproate for 5 months for epilepsy at a dose of 400 mg/day in two divided doses and the seizures had been under control.

On admission, the respiratory rate was 20/min, pulse rate was 88/min, blood pressure was 110/90 mmHg, and was maintaining oxygen saturation on room air. The liver and spleen were not palpable and all other systems were normal. Physical examination revealed a lymph node in the posterior triangle of the neck on the right side that was non-tender, firm, 1 cm × 1 cm in diameter, and freely mobile (Fig. 1). No other lymph nodes were palpable elsewhere.

Complete blood report showed a total leukocyte count of 8800/mm³ with 77% neutrophils, 14% lymphocytes, 4% eosinophils, and 5% monocytes. Erythrocyte sedimentation rate was reported to be 8 mm in the 1st h. The liver function test and renal function test were unremarkable. No radiological investigations were done. Fine needle aspiration was done using a 22 Gauge needle attached to a 10 ml syringe on Franzen handle under aseptic precautions from the site. Smears were air-dried and stained with May Grunwald-Giemsa and Papanicolaou.

Correspondence to: Dr. Sanya Jain, Girls Hostel 1, GMC, Rajindra Hostel, Patiala, Punjab, India. E-mail: jaindrsanya@gmail.com

© 2021 Creative Commons Attribution-NonCommercial 4.0 International License (CC BY-NC-ND 4.0).

Access this article online

Received - 15 January 2021
Initial Review - 31 January 2021
Accepted - 08 March 2021

Quick Response code



DOI: 10.32677/IJCR.2021.v07.i03.006

Cytological smears examined showed numerous singly scattered and collections of foamy macrophages admixed with eosinophils, plasma cells, and a rare ill-defined collection of epithelioid cells. Occasional foci of lymphoid series of cells against a necrotic background were also noted. However, no Reed-Sternberg cells were seen (Fig. 2). This along with the presence of a polymorphic population of lymphoid series of cells ruled out the possibility of Hodgkin lymphoma and diagnosis of drug-induced reactive lymphoid hyperplasia was made. Valproic acid was discontinued after which the swelling completely regressed and the patient was put on Levitiracetam 500 mg in two divided doses.

DISCUSSION

Anticonvulsants that are most frequently associated with lymphadenopathy are phenytoin, phenobarbital, and carbamazepine. Non-aromatic anticonvulsant drugs (e.g., topiramate and valproic acid) are generally considered safe. The pathogenesis seems to be multifactorial including metabolic, genetic, and immunologic factors, and has not been fully understood [9]. Metabolism of AEDs includes phase 1 (bioactivation) and phase 2 (detoxification) reactions that may be affected by metabolic enzyme genetic polymorphisms. An altered balance between drug bioactivation and detoxification pathways may elevate levels of the reactive metabolites, which either cause direct cell damage or bind irreversibly to cellular proteins.

These drug-modified proteins trigger an immune response with three pathways [10]. The first is the hapten/prohapten hypothesis,

which proposes that the AED is oxidatively metabolized to reactive, potentially cytotoxic intermediate molecules capable of interacting covalently with cellular macromolecules, that is, they behave as hapten or prohaptens [9,10]. These drug-modified proteins could then function as immunogens, with the potential to initiate antibody and/or cellular mediated immune response against drug-modified or native proteins. Most hypersensitivity reactions to AEDs are mediated by non-immediate (delayed) type IV reactions (e.g. maculopapular exanthem, drug reaction with eosinophilia and systemic symptom [DRESS], drug-induced liver injury) in which a specific human leukocyte antigen (HLA) allele presents and activates drug-specific T cells [9,10].

Besides the classical model of the antigen-presenting cell-T cell interaction, an alternative mechanism by which delayed hypersensitivity may occur is described by the so-called p-i concept, that is, pharmacological interaction with immune receptors. According to this concept, drugs or metabolites can interact directly and non-covalently with the MHC and/or T-cell receptor inducing the formation of HLA, drug complexes that activate T-cell immune responses without requiring a specific peptide ligand [11]. Carbamazepine and its reactive metabolites have been shown to directly activate T cells, confirming the hypothesis of “p-i concept” for AED hypersensitivity [12]. A third mechanism includes the “altered peptide repertoire” hypothesis, which postulates that the drugs or their metabolites can bind non-covalently within the pocket of the peptide-binding groove of certain HLA molecules, potentiating a new repertoire of endogenous self-peptides to be bound and presented [13].

Additional “danger signals” originating from stress induced by viral infections, cellular insult, and toxic intermediates may provide the co-stimulatory signals for the boosting of the immune response to AED-derived antigen. Concurrent medications, including both AEDs and non-AEDs such as antifungals and macrolides, can affect the susceptibility to developing hypersensitivity reactions to AEDs as a result of CYP450 metabolism, competition, and protein binding [10]. In general, enzyme inducers decrease the serum concentrations of other drugs metabolized by the system, and enzyme inhibitors have the opposite effect [14]. Overall, conventional AEDs such as carbamazepine, phenobarbital, phenytoin, and valproic acid are generally more prone to drug interactions.

Since the introduction of the various hydantoin derivatives and analogs into the therapy of convulsive disorders, scattered reports

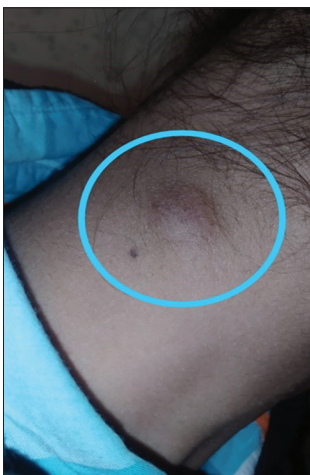

Figure 1: Enlarged cervical lymph node

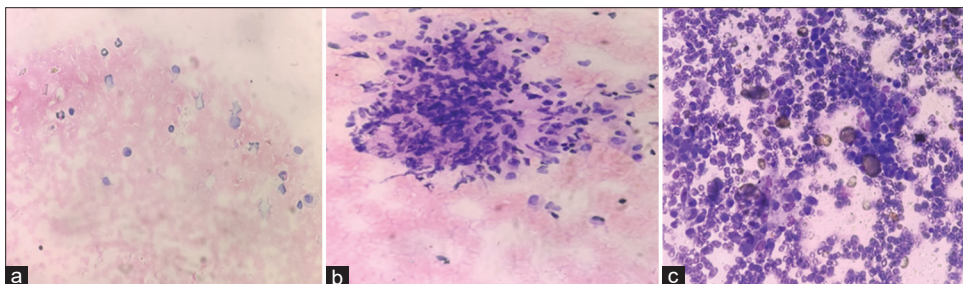


Figure 2: (a) Eosinophils and plasma cells (H and E 400 \times); (b) Ill-defined collection of epithelioid cells (May Grunwald-Giemsa 400 \times); (c) Polymorphous population of lymphoid series of cells

have appeared in the literature of peculiar lymphadenopathy directly related to this therapy. The lymphadenopathy may occur in conjunction with the more widely known reactions to these drugs, such as leukopenia, fever, and skin rashes, or it may appear in the absence of these other reactions. Saltzstein and Ackerman did a study wherein they reported lymphadenopathy induced by phenytoin which mimicked malignant lymphomas clinically and pathologically [8]. Wu *et al.* reported the first case of hypersensitivity syndrome in a 73-year-old Asian male taking valproic acid monotherapy for epilepsy who presented with generalized skin erythema, high fever, hyponatremia, thrombocytopenia, and high aminotransferase for 2 weeks [6]. Arevalo-Lorido *et al.* described the case of a 36-year-old man with acute hypersensitivity syndrome caused by valproic acid 2 weeks after initial carbamazepine therapy which was discontinued because of severe skin rash [15]. Bota *et al.* discussed the case of a 25-year-old woman with bipolar disorder who experienced DRESS caused by valproic acid 1 month after the withdrawal of Lamotrigine because of a non-specific skin rash [16].

Cytologic study of the aspirated material in the present study showed a polymorphic cell population composed of small and large lymphocytes, eosinophils, plasma cells, and numerous collections of macrophages. An occasional ill-defined collection of epithelioid cells were also seen. These cytologic features suggested Hodgkin's lymphoma, pseudolymphoma cutis, large-cell non-Hodgkin's lymphoma, and regressing atypical histiocytosis. However, because of the lack of typical Reed-Sternberg cells and due to the presence of polymorphic cells with fine chromatin, regular nuclear borders, and inconspicuous nucleoli, this case was diagnosed cytologically as valproate-induced benign lymphoproliferative disorder.

CONCLUSION

Given the number of patients regularly using valproate as an anticonvulsant and in psychiatric disorders, recognition of valproate-induced lymphoid hyperplasia is a rare finding and assumes significance as it is an important clinical entity that general physicians need to be cognizant of. Considering valproic acid has a potential risk of DRESS, doctors should be aware of possible multiple drug hypersensitivity when using valproic acid as replacement therapy.

REFERENCES

1. Linet OI, Metzler C. Practical ENT. Incidence of palpable cervical nodes in adults. *Postgrad Med* 1977;62:210-3.
2. Guerrini R. Epilepsy in children. *Lancet* 2006;367:499-524.
3. Bansal D, Azad C, Kaur M, Rudroju N, Vepa P, Guglani V. Adverse effects of antiepileptic drugs in North Indian pediatric outpatients. *Clin Neuropharmacol* 2013;36:107-13.
4. Demoly P, Adkinson F, Brockow K, Castells M, Chiriac AM, Greenberger PA, *et al.* International consensus on drug allergy. *Allergy* 2014;69:420-37.
5. Darban M, Bagheri B. Drug reaction with eosinophilia and systemic symptoms induced by valproic acid: A case report. *Iran Red Crescent Med J* 2016;18:e36825.
6. Wu XT, Hong PW, Suolang DJ, Zhou D, Stefan H. Drug-induced hypersensitivity syndrome caused by valproic acid as a monotherapy for epilepsy: First case report in Asian population. *Epilepsy Behav Case Rep* 2017;8:108-10.
7. Meik S, Arias M, Fernandez L, Santoro LM, Abeldano A, Pellerano G. Anti-convulsant hypersensitivity syndrome (DRESS syndrome): Report of 4 cases. *Dermatol Argent* 2010;16:272-7.
8. Saltzstein SL, Ackerman LV. Lymphadenopathy induced by anticonvulsant drugs and mimicking clinically pathologically malignant lymphomas. *Cancer* 1959;12:164-82.
9. Pichler WJ, Yawalkar N, Britschgi M, Depta J, Strasser I, Schmid S, *et al.* Cellular and molecular pathophysiology of cutaneous drug reactions. *Am J Clin Dermatol* 2002;3:229-38.
10. Ju C, Uetrecht JP. Mechanism of idiosyncratic drug reactions: Reactive metabolite formation, protein binding and the regulation of the immune system. *Curr Drug Metab* 2002;3:367-77.
11. Pichler WJ, Beeler A, Keller M, Lerch M, Posadas S, Schmid D, *et al.* Pharmacological interaction of drugs with immune receptors: The p-i concept. *Allergol Int* 2006;55:17-25.
12. Wu Y, Sanderson JP, Farrell J, Drummond NS, Hanson A, Bowkett E, *et al.* Activation of T cells by carbamazepine and carbamazepine metabolites. *J Allergy Clin Immunol* 2006;118:233-41.
13. Ostrov DA, Grant BJ, Pompeu YA, Sidney J, Harndahl M, Southwood S, *et al.* Drug hypersensitivity caused by alteration of the MHC-presented self-peptide repertoire. *Proc Natl Acad Sci U S A* 2012;109:9959-64.
14. Canevini MP, De Sarro G, Galimberti CA, Gatti G, Licchetta L, Malerba A, *et al.* Relationship between adverse effects of antiepileptic drugs, number of coprescribed drugs, and drug load in a large cohort of consecutive patients with drug-refractory epilepsy. *Epilepsia* 2010;51:797-804.
15. Arévalo-Lorido JC, Carretero-Gómez J, Bureo-Dacal JC, Montero-Leal C, Bureo-Dacal P. Antiepileptic drug hypersensitivity syndrome in a patient treated with valproate. *Br J Clin Pharmacol* 2003;55:415-6.
16. Bota RG, Ligasan AP, Najdowski TG, Novac A. Acute hypersensitivity syndrome caused by valproic acid: A review of the literature and a case report. *Perm J* 2011;15:80-4.

Funding: None; Conflicts of Interest: None Stated.

How to cite this article: Kaur K, Kaur M, Jain S. Valproate-induced reactive lymphoid hyperplasia in pediatric population: A rare case report. *Indian J Case Reports*. 2021;7(3):92-94.