

Metastatic malignant PEComa of the brain: An unusual entity with rare presentation

Reena Bharadwaj¹, Gaurav Pratap Singh Gahlot², Rekha Vashisth³, Rajeev Saxena⁴, Siddarth Shukla⁵, Beenu Singh⁶

From ¹Senior Consultant, Department of Lab Med, Indraprastha Apollo Hospital, New Delhi, ²Associate Professor, Department of Pathology, ⁴Professor, Department of Neurology, ⁵Assistant Professor, Department of GE Med, Command Hospital (WC) Chandimandir, Haryana, ³Assistant Professor, Department of Radiation Oncology, Command Hospital (CC) Lucknow, ⁶Graded Specialist, Department of ENT, 164 Military Hospital C/O 99 APO, Jalpaiguri, West Bengal, India

ABSTRACT

Perivascular epithelioid cell tumor (PEComa) is an unusual mesenchymal tumor comprised histological and immunohistochemically distinctive perivascular epithelioid cells exhibiting myomelanocytic phenotype. We hereby report the case of a 59-year-old female who presented with sudden headache, vomiting, and transient decreased vision with contrast MRI suggestive of the right occipital mass. Biopsy from the right occipital craniotomy mass was reported as metastatic malignant melanoma. The case was referred to our hospital for review. We considered a differential diagnosis of metastasis from malignant melanoma, poorly differentiated carcinoma, high-grade glioma, PEComa, hemangioblastoma, and high-grade sarcoma. A post-operative whole-body PET/CT scan revealed a metabolically active lesion in the endometrium that seems to be primary. It is suggested to consider PEComa as a differential diagnosis in poorly differentiated malignancy and to evaluate accordingly with appropriate immunohistochemistry markers. This is the third reported case of metastatic malignant PEComa to the brain as per the English literature.

Key words: Brain metastasis, Desmin, Endometrium, Malignant PEComa

In 1996, Zamboni coined the term “Perivascular epithelioid cell tumors” (PEComas) for rare tumors with characteristic histomorphology and immunohistopathological expression of myomelanocytic markers [1]. Malignant PEComa has been defined by Folpe *et al.* as infiltrative growth with marked hypercellularity, hyperchromatic nuclei, high mitosis, and coagulative necrosis [2]. Therefore, the malignant potential of PEComa depends on the histomorphology of the primary tumor irrespective of the site of origin. Frequent metastatic sites include lung, bone, liver, intestine, and lymph nodes, whereas, metastasis to the brain has been reported in only two cases as the central nervous system (CNS) always been a protected site due to the blood–brain barrier which restricts the free transfer of tumor cells [3-5]. Here, we are going to discuss the third documented case of metastatic malignant PEComa to the brain in a middle-aged female.

CASE REPORT


A 59-year-old female presented with complaints of sudden, headache involving the full head, non-projectile vomiting, and transient decreased vision. She was a known case of hypertension. No history of seizure/ear-nose-throat bleed was present. General examination reveals the fair condition of the patient without any pallor, icterus, or cyanosis. Systemic examination revealed left temporal hemianopia with bilateral 6 feet finger counting.

Hemoglobin was 13.5 gm/dl, total leukocytes count was 6900/mm³, and platelets were 380,000/mm³. Biochemical values comprise serum bilirubin of 0.8 g/dl, serum urea 16 mg/dl, serum creatinine 0.9 mg/dl, serum cholesterol of 198 mg/dl, blood sugar fasting 98 gm/dl, and blood sugar postprandial of 138 gm/dl.

Magnetic resonance imaging (MRI) brain with contrast revealed an irregular enhancing mass lesion in the right occipital region measuring 22 × 12 mm with intermediate signal intensity on T1 and T2W1. An associated acute hematoma in the right

Correspondence to: Dr. Gaurav Pratap Singh Gahlot, Department of Pathology, Command Hospital Western Command, Chandimandir Panchkula Haryana - 134 107, India. E-mail: gpsinghgahlot@gmail.com

© 2021 Creative Commons Attribution-NonCommercial 4.0 International License (CC BY-NC-ND 4.0).

Access this article online	
Received - 04 February 2021 Initial Review - 24 February 2021 Accepted - 04 March 2021	Quick Response code 
DOI: 10.32677/IJCR.2021.v07.i03.003	

occipital-posterior temporal lobe measuring $47 \times 24 \times 20$ mm causing partial effacement with low signal intensity on T2W1 and moderate edema of the surrounding region was noted. An opinion of likely neoplastic (primary/secondary hemorrhagic) lesion was offered.

Whole-body positron emission tomography (PET) scan revealed large, heterogeneously enhancing, mixed density soft-tissue mass with increased FDG uptake involving endometrial cavity measuring 9.7×7.9 cm and standardized uptake value (SUV) max of 7.16. Small subcentimeter nodular densities with increased FDG uptake in the anterior segment of the left upper lobe, the superior segment of the left lower lobe, and pleural-based soft-tissue mass with increased FDG uptake involving posterior pleura of the left lobe measuring 2×3.6 cm and SUVmax 4.34 was noted. Post-surgical gliotic changes were observed in the right occipital lobe without any increase in FDG avidity in the bilateral cerebral/cerebellar hemisphere. The paraffin blocks of the tumor were reviewed at our institute.

The right occipital craniotomy with tumor decompression was performed. Grossly, the tumor is composed of gray, brown, soft-tissue bits measuring $1.5 \times 1.0 \times 0.5$ cm. Histopathology diagnosis of metastatic malignant melanoma was given. Hematoxylin and eosin-stained section showed tumor cells arranged in a sheet with distinct vasculature and infiltration of the underlying brain parenchyma. These tumor cells had predominant polygonal epithelioid morphology with indistinct cell borders, clear, granular eosinophilic cytoplasm significant nuclear atypia, prominent single/multiple nucleoli, and tumor giant cells (Fig 1a-d). Spindle cell components comprised short fascicles, nests of slender fusiform cells, and foci of necrosis. PEComas and epithelioid smooth muscle tumors can be differentiated histomorphologically as the latter lacks the characteristic vascular network of the former.

The initial immunohistochemical panel showed HMB45 positivity (Fig. 1e) and vimentin/pancytokeratin/S-100/CD45 negativity. The second immunohistochemical panel revealed desmin (Fig. 1f), smooth muscle actin (SMA) (Fig. 1g), epithelial membrane antigen, calponin positivity, and 75–80% Ki67 (Fig. 1h), whereas, negative for Melan-A, GFAP, TFE-3, CD10, β -hCG, CK7, CK20, TTF1, CD117, neuron-specific enolase (NSE), chromogranin A, and PAX8.

The post-operative period was eventful. The patient was advised radiotherapy. Based on the histomorphological features and myomelanocytic immunohistochemical profile, a diagnosis of metastatic malignant PEComa was considered. An endometrial biopsy was advised for the confirmation of the primary lesion.

DISCUSSION

PEComas are a group of ubiquitous, mesenchymal neoplasms exhibiting specific morphological, immunohistochemical, ultrastructural, genetic features, and arise from distinctive perivascular epithelioid cells (PEC), that is, peritheliomatous cells with epithelioid or spindled cytology [6]. PEComa cells origin from neural crest cells or myoblastic or pericytes; progenitors of fat/muscle cells have been suggested [7]. PEComas are associated with genetic alterations of tuberous sclerosis complex (TSC) due to losses of TSC1 (9q34) or TSC2 (16p13.3) genes in 27% and 73% of cases, respectively. TSC genes are important in the regulation of Rheb/mTOR/p70S6K pathway [8]. Electron microscopy shows multiple granules resembling promelanosomes within a cytoplasm that displays ultrastructural features similar to those of smooth muscle cells.

Our patient is a 59-year-old female presented with sudden onset of headache, vomiting, and transient decrease of vision. MRI with the contrast of brain revealed right occipital mass as

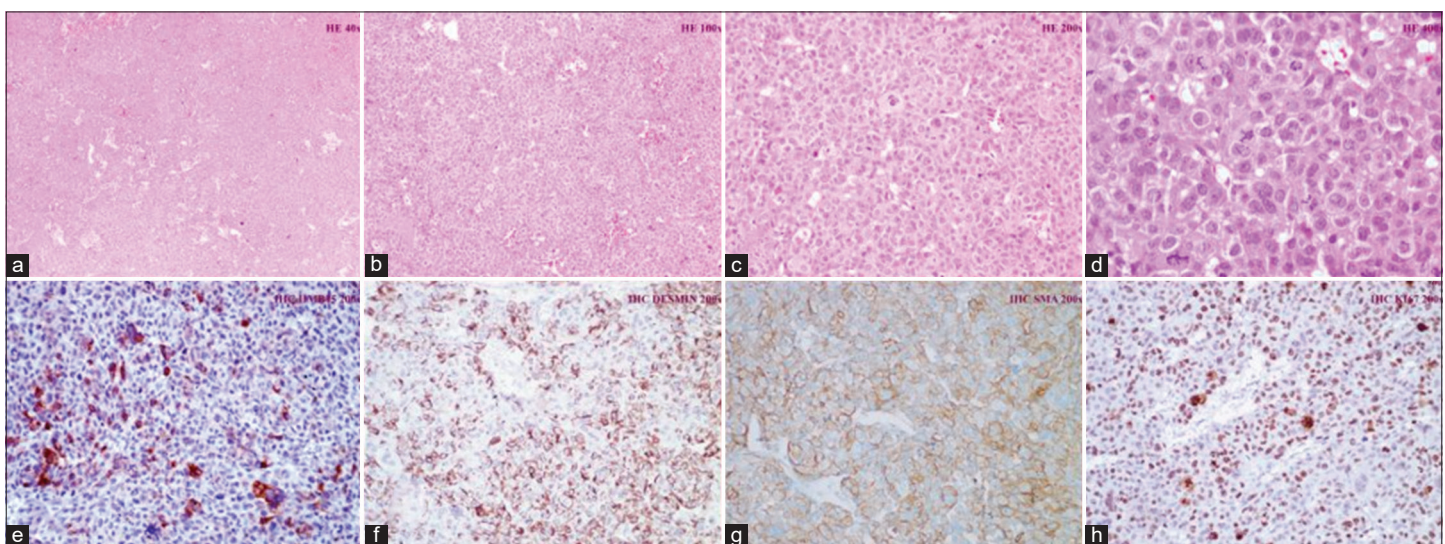


Figure 1: H&E stain (1a; $\times 40$) medium to large sized polygonal epithelioid cells arranged as sheet with distinct vasculature. Figure of higher magnification (1b; $\times 100$, 1c; $\times 200$, 1d; $\times 400$) depicts tumor cells with indistinct cell borders, clear, granular eosinophilic cytoplasm significant nuclear atypia, and prominent single/multiple nucleoli. Immunohistochemical profile of HMB45 (1e; $\times 200$), desmin (1f; $\times 200$), and SMA (1g; $\times 200$) positivity with 75–80% Ki67; (1h; $\times 200$) noted

non-specific, variable features of likely neoplastic lesion similar to as reported by Tirumani *et al.* [5]. The tumor tissue obtained by the right craniotomy was reported as metastasis of malignant melanoma.

On reviewing the hematoxylin and eosin-stained section from tumor tissue, we considered histomorphological differential diagnosis of malignant melanoma, poorly differentiated carcinoma (adrenocortical carcinoma, renal cell carcinoma, paraganglioma, and choriocarcinoma), high-grade sarcoma (clear cell sarcoma of soft part, angiosarcoma, alveolar soft part sarcoma, monophasic epithelioid angiomyolipoma, epithelioid leiomyosarcoma, endometrial stromal sarcoma, and epithelioid gastrointestinal stromal tumor), and primary CNS tumors (high-grade glioma, anaplastic oligodendroglioma, clear cell ependymoma, clear cell meningioma, and hemangioblastoma).

The initial immunohistochemical panel showed HMB45 positivity, vimentin/pancytokeratin/S-100/CD45 negativity. The second immunohistochemical panel revealed desmin, smooth muscle actin (SMA), epithelial membrane antigen, and calponin positivity, whereas, negative for Melan-A, GFAP, TFE-3, CD10, β -hCG, CK7, CK20, TTF1, CD117, neuron-specific enolase (NSE), chromogranin A, and PAX8. Based on this immunohistochemical profile, malignant melanoma (HMB45 positive and desmin/SMA negative), adrenocortical carcinoma/paraganglioma (chromogranin, synaptophysin positive, and HMB45 negative), renal cell carcinoma (CD10 positive and HMB45 negative), clear cell sarcoma of the soft part (S100 positive and desmin/SMA negative), angiosarcoma (SMA, CD34 positive, and HMB45 negative), alveolar soft part sarcoma (TFE3 positive and HMB45 negative), monophasic epithelioid angiomyolipoma (no adipocytes present), epithelioid leiomyosarcoma (vimentin positive and HMB45 negative), endometrial stromal sarcoma (vimentin, CD10 positive, and HMB45 negative), epithelioid GIST (CD117 positive and HMB45 negative), choriocarcinoma (PANCK, β -hCG positive, and HMB45 negative) and high-grade glioma, anaplastic oligodendroglioma, clear cell ependymoma (GFAP positive and HMB45 negative), clear cell meningioma (EMA positive and HMB45 negative), and hemangioblastoma (NSE positive and HMB45 negative) were ruled out.

Occasional uterine epithelioid sarcoma being HMB45 positive in addition its inherent desmin/SMA positivity possesses a diagnostic challenge for PEComa, however, in our case, vimentin negativity ruled out the possibility of metastatic epithelioid sarcoma, therefore, a definitive diagnosis of metastatic malignant PEComa was offered [9]. Our immunohistochemical results were similar to a study conducted by Folpe *et al.* who observed PEComa as 100% HMB-45 positive, 59% SMA positive, 41% Melan-A positive, 38.5% TFE3, 33% CD117 positive, 31% 26.1% CD10, desmin positive, 11% S-100 positive, and 0% was cytokeratin positive [2].

PEComa occurring at “non-classic” anatomic distributions is known as PEComa-not otherwise specified (PEComa-NOS)

and has been reported in gynecological, genitourinary, gastrointestinal, extremities, skin, heart, breast, oral cavity, and orbit with uterus as the most prevalent site [10]. The first case of PEComa of the uterus was reported by Pea *et al.* as a polypoid neoplasm of the endometrium [11]. Our case fulfilled “Folpe criteria” of malignant PEComa due to the presence of frequent mitosis, necrosis in addition to marked hypercellularity, and marked nuclear pleomorphism. Malignant PEComa can be a very aggressive disease with multiple metastases similar to high-grade sarcoma. Post-operative whole-body PET scan findings of our case were suggestive of primary endometrial malignancy with pleural based and the left lung parenchymal metastatic deposits.

Optimal treatment for locally advanced/metastatic disease portends a poor prognosis and treatment strategies of active surveillance to surgery, radiotherapy, or targeted therapy have been suggested. Our patient being metastatic was offered mTOR pathway inhibitor therapy, that is, everolimus 5 mg once a day with six monthly follow-up and is doing well. However, larger randomized trials are advised to establish malignant potential of PEComa and its therapeutic strategy [12].

CONCLUSION

The index case is an extremely rare third documented case of metastatic malignant PEComa of the brain with a suggested primary tumor of endometrial origin. Their distinct histomorphology with characteristic myomelanocytic immunohistochemical profile clinched the diagnosis at the unexpected sites. In metastatic disease, the result of mTOR inhibitors (sirolimus) is encouraging and thus warrants further investigation of TSC1/TSC2 tumor suppressor genes that can destabilize the rapamycin (mTOR) pathway.

REFERENCES

- Jungbluth AA, Busam KJ, Gerald WL, Stockert E, Coplan KA, Iversen K, *et al.* An anti-melan-a monoclonal antibody for the detection of malignant melanoma in paraffin-embedded tissues. *Am J Surg Pathol* 1998;22:595-602.
- Folpe AL, Mentzel T, Lehr HA, Fisher C, Balzer BL, Weiss SW. Perivascular epithelioid cell neoplasms of soft tissue and gynecologic origin. *Am J Surg Pathol* 2005;29:1558-75.
- Parfitt JR, Keith JL, Megyesi JF, Ang LC. Metastatic PEComa to the brain. *Acta Neuropathol* 2006;112:349-51.
- Jayapalan RR, Bahuri NFA, Mun KS, Narayanan V. A rare case of perivascular epithelioid cell tumor metastases to the brain. *SAGE Open Med Case Rep* 2019;7:2050313X19828539.
- Tirumani SH, Shinagare AB, Hargreaves J, Jagannathan JP, Hornick JL, Wagner AJ, *et al.* Imaging features of primary and metastatic Malignant perivascular epithelioid cell tumors. *Am J Roentgenol* 2014;202:252-8.
- Bonetti F, Pea M, Martignoni G, Zamboni G. PEC and sugar. *Am J Surg Pathol* 1992;16:307-8.
- Selvaggi F, Risio R, Claudi R, Cianci R, Angelucci D, Pulcini D, *et al.* Malignant PEComa: A case report with emphasis on clinical and morphological criteria. *BMC Surgery* 2011;11:3.
- Van Slegtenhorst M, de Hoogt R, Hermans C, Nellist M, Janssen B, Verhoef S, *et al.* Identification of the tuberous sclerosis gene TSC1 on

- chromosome 9q34. *Science* 1997;277:805-8.
9. Silva EG, Bodurka DC, Scouros MA, Ayala A. A uterine leiomyosarcoma that became positive for HMB45 in the metastasis. *Ann Diagn Pathol* 2005;9:43-5.
 10. Fadare O. Perivascular epithelioid cell tumor (PEComa) of the uterus: An outcome-based clinicopathologic analysis of 41 reported cases. *Adv Anat Pathol* 2008;15:63-75.
 11. Pea M, Martignoni G, Zamboni G, Bonetti F. Perivascular epithelioid cell. *Am J Surg Pathol* 1996;20:1149-53.
 12. Dickson MA, Schwartz GK, Antonescu CR, Kwiatkowski DJ, Malinowska IA. Extrarenal perivascular epithelioid cell tumors (PEComas)

respond to mtor inhibition: Clinical and molecular correlates. *Int J Cancer* 2013;132:1711-7.

Funding: None; Conflicts of Interest: None Stated.

How to cite this article: Bharadwaj R, Gahlot GP, Vashisth R, Saxena R, Shukla S, Singh B. Metastatic malignant PEComa of the brain: An unusual entity with rare presentation. *Indian J Case Reports*. 2021;7(3):83-86.