

## Clinical approach to palatal necrosis in an immunocompromised patient: A dental professional's role

Nivethitha Nagarajan<sup>1</sup>, Sadaksharam Jayachandran<sup>2</sup>, Jayaram Vidya<sup>3</sup>

From <sup>1</sup>Postgraduate Student, <sup>2</sup>Professor and Head, <sup>3</sup>Assistant Professor, Department of Oral Medicine and Radiology, Tamil Nadu Government Dental College and Hospital, Chennai, Tamil Nadu, India

### ABSTRACT

Mucormycosis is a rare, emerging fungal infection caused by Mucormycetes/Zygomycetes/Phycomycetes. It is an airborne infection that shows systemic dissemination. The prevalence of mucormycosis varies and is 14/100,000 population in India. The rhino-orbitocerebral form is common in the maxillofacial region. Effective antifungal therapy, surgical debridement, a reversal of immunosuppression, and management of the underlying medical condition are the treatment modalities followed in mucormycosis. The dental professionals play a pivotal role in the early diagnosis of mucormycosis allowing timely initiation of the therapy and surgical debridement reducing morbidity and mortality. This case report presents a case of mucormycosis affecting the left maxillary posterior region in a 42-year-old male who reported with a chief complaint of swelling, nasal obstruction, nasal discharge, and headache, diagnosed at an early stage, and treated with surgical debridement through a multidisciplinary approach.

**Key words:** Diabetes mellitus, Fungal, Maxilla, Mucormycosis, Rhino-orbitocerebral

**M**ucormycosis is a fulminant fungal infection caused by the fungi of class Phycomycetes. This disease is prevalent in patients with suppressed resistance or immunodeficiencies [1]. Lichtheim in 1884 was the first to establish the pathogenicity in experimental studies in rabbits [1]. It is an airborne infection and the primary disease is initiated in the upper or lower respiratory tract. Dissemination of infection to the skin, brain, and other sites is less common, but the direct extension of the infection to contiguous sites is common [2]. Most infections are life threatening due to systemic complications. The risk factors include diabetic ketoacidosis, hematologic malignancies, hematopoietic stem cell transplantation, and neutropenia [3]. Rhinocerebral mucormycosis is the most common form of mucormycosis and is seen particularly in cases of uncontrolled diabetes mellitus [4]. Originating from the nasal cavity and the paranasal sinuses, rhinocerebral mucormycosis extends to the hard palate, soft palate, pharynx, and orbits. It causes facial pain, visual loss, nasal discharge, headache, orbital cellulitis, ophthalmoplegia, and proptosis. In the oral cavity, it can manifest as an ulcer/swelling/necrosis of the hard palate, soft palate, or maxillary buccal vestibular region which mimics the carcinoma of the maxillary sinus or palate. The prevalence of mucormycosis varies and is 14/100,000 population in India [5].

The management requires an early diagnosis of the disease, aggressive medical, and surgical interventions to prevent high morbidity and mortality associated with the disease progress [4].

This case report presents a case of swelling in the left maxillary posterior region in an otherwise normal adult whose diabetic status was eventually identified during routine blood investigations which aided the diagnosis of mucormycosis in a dental health-care setting and treated at an early stage through a multidisciplinary approach.

### CASE REPORT

A 42-year-old male reported to the department of oral medicine and radiology with a chief complaint of swelling in the upper left back region of the jaw for the past 3 weeks. The swelling was associated with nasal obstruction, nasal discharge, and headache. History revealed that the swelling was present for the past 2 weeks. It was insidious in onset, which gradually increased and attained the present size. Nasal obstruction was present for the past 2 weeks, gradually progressive with difficulty in breathing through the nose. The nasal discharge was present for the past 3 weeks, mucopurulent in nature and predominantly from the left nose. Headache was associated with the left-sided facial pain which was present for the past 3 weeks. There was no history of

#### Access this article online

Received - 08 October 2020  
Initial Review - 23 October 2020  
Accepted - 29 October 2020

#### Quick Response code



DOI: 10.32677/IJCR.2020.v06.i11.006

**Correspondence to:** Dr. Nivethitha Nagarajan, Department of Oral Medicine and Radiology, Tamil Nadu Government Dental College and Hospital, Dr. M.G.R. Medical University, Chennai - 600 003, Tamil Nadu, India. E-mail: nive\_revathi@yahoo.co.in

© 2020 Creative Commons Attribution-NonCommercial 4.0 International License (CC BY-NC-ND 4.0).

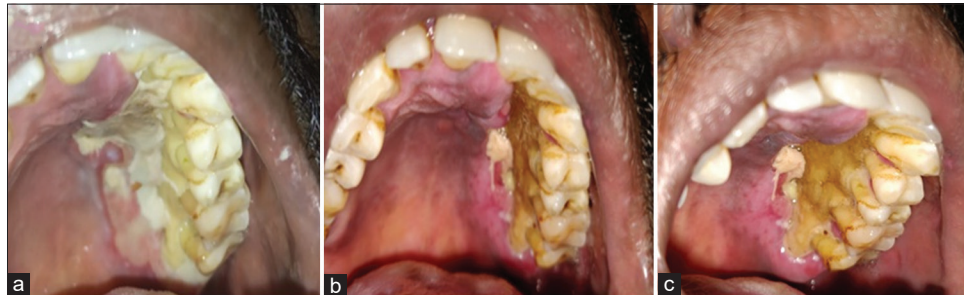fever, trauma, ear pain, ear discharge, bleeding, or pus discharge related to the swelling. The medical history, dental history, and habit history were not contributory.

On general examination, the patient appeared moderately built and nourished. On extraoral examination, the facial swelling was approximately 2.5 cm × 2.0 cm with a mild facial asymmetry which was observed in the left maxillary region. On palpation, the swelling was firm to hard in consistency, tender, fixed to the underlying bone, and free from the overlying skin with mild tenderness. No secondary changes were evident in the extraoral skin over the swelling and no cervical lymphadenopathy was present. Intraorally, necrosis of the mucosa was present in the left hard palate measuring approximately 3 cm × 3 cm and extending anteriorly from the gingival margin of the maxillary left lateral incisor (22) till the retromolar (27) region posteriorly (Fig. 1a). The necrotic area extended within the midline and the surrounding mucosa appeared erythematous. The labial gingiva and labial mucosa appeared normal. Tenderness was present on palpation and no bleeding was evident.

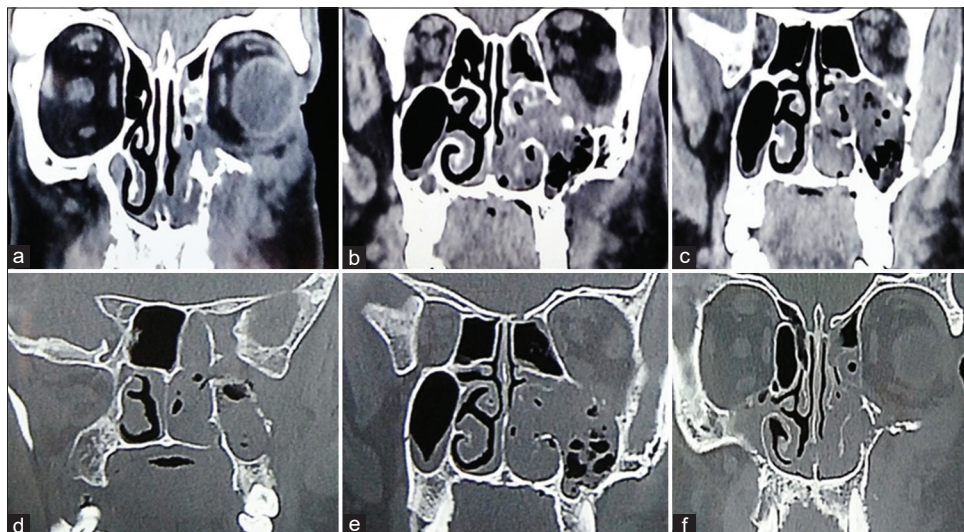
The patient consent was obtained and mild debridement using hydrogen peroxide and saline was done to remove the superficial necrotic slough. The underlying bone was exposed and the roots of the maxillary posterior teeth were partially exposed (Figs. 1b and c). The necrotic margins were ill-defined and erythematous.

Biochemical investigations revealed a random blood glucose level of 320 mg/dl and Glycated hemoglobin 11.2 associated with glycosuria and ketonuria. The other biochemical parameters were within normal limits. Axial and coronal sections of the computed tomography (CT) scan revealed a homogenous soft-tissue density in the left maxillary sinus and the left nasal area. The lateral wall of the left maxillary sinus, floor of the left orbit, nasal turbinates, nasal concha, and the palatal region appeared to be involved. CT also revealed mild mucosal thickening of the left maxillary sinus with complete obliteration. There was an expansion of the left maxillary air sinus and orbital region with partial destruction of the lateral wall of the maxillary air sinus and inferior wall of the orbit. The brain area appeared apparently normal without any involvement. The nasal septum and right maxillary sinus appeared normal (Figs. 2a-f). The clinical presentation, medical history, and radiological investigation led to the provisional diagnosis of the rhino-orbital form of mucormycosis.

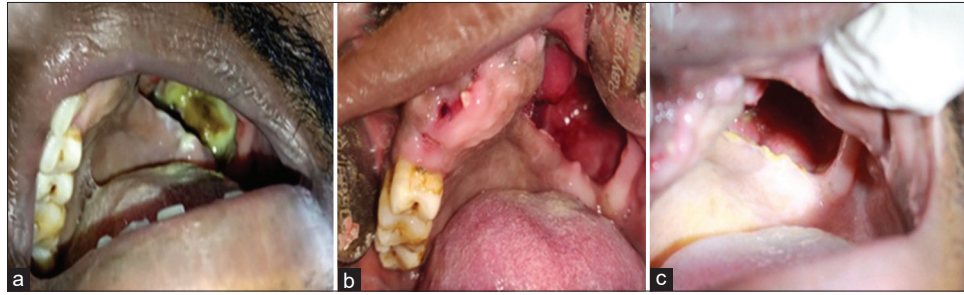
Extensive debridement with inferior and posterior maxillectomy was done under anesthesia. The necrotic bone in the hard palate (inferior and posterior walls of maxilla) was removed, drainage of purulent discharge was done, and adequate hemostasis was achieved. The maxillary anterior and posterior teeth (21, 22, 23, 24, 25, 26, and 27) were removed



**Figure 1:** (a) Necrosis of the mucosa in the left hard palate extending anteriorly from the gingival margin of the maxillary left lateral incisor till the retromolar region posteriorly (b and c). Mild debridement using hydrogen peroxide and saline to remove the superficial necrotic slough and underlying bone was exposed



**Figure 2 (a-f)** Computed tomography scan revealed a homogenous soft-tissue density in the left maxillary sinus and left nasal area. The lateral wall of the left maxillary sinus, floor of the left orbit, nasal turbinates, nasal concha, and the palatal region appear to be eroded



**Figure 3:** (a) Immediate post-operative photograph; (b) 1-week post-operative photograph; (c) 1-month post-operative photograph

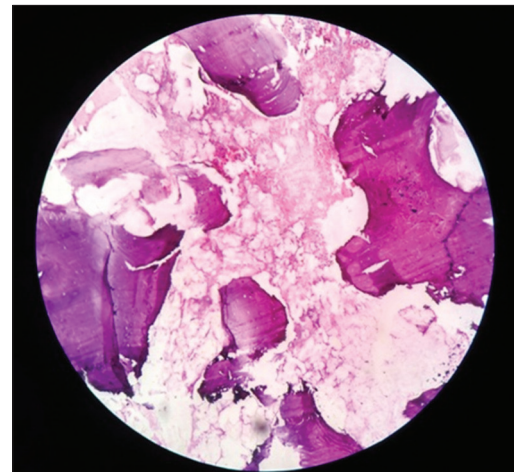
as the bone surrounding the teeth were involved (Fig. 3a). The palatal defect was packed with antiseptic wound dressing and regularly monitored (Fig. 3b). Amphotericin B (50 mg) and ciprofloxacin (200 mg) twice daily were administered intravenously. Insulin was administered to maintain the blood sugar level and the random blood sugar level was 88 mg/dl at the time of surgery.

The fungal culture revealed no fungal elements. Hematoxylin and eosin stained histological section under 4× revealed respiratory epithelium lining with underlying stroma showing a dense collection of inflammatory cells composed of lymphocytes, plasma cells, neutrophils, and congested blood vessels (Fig. 4). It also showed an extensive area of necrosis with broad aseptate fungal hyphae with right-angle branching and bony spicules. Angioinvasion was evident suggestive of invasive mucormycosis.

He was monitored regularly for drug-induced toxicity and diabetic profile. The 1-month post-operative follow-up revealed proper wound healing in the surgical site and the patient was planned for a temporary palatal obturator (Fig. 3c). The biochemical investigation revealed a random blood sugar level of 88 mg/dl with no glycosuria and ketonuria. The patient is under regular follow-up for the past 3 months with no recurrence.

## DISCUSSION

Platauf first described the zygomycosis in his paper entitled “Mycosis mucorina” [6]. They are considered opportunistic pathogens that breakdown the host immune defenses that lead to neutropenia or neutrophil dysfunction. The hallmarks of this disease are angioinvasion, infarction, thrombosis, and necrosis of the involved bone/tissue [7]. The prevalence of mucormycosis varies and is 14/100,000 population in India [5]. The overall mortality rate was 46% with the highest percentage in disseminated mucormycosis (68%) [8]. Mucormycosis can occur after inhalation of spores that may deposit in the nasal turbinates or pass into the lungs [9]. Five clinical forms of mucormycosis are recognized, namely, rhino-orbitocerebral, pulmonary, gastrointestinal, cutaneous, and disseminated. The mortality rates for mucormycosis range from 40% to 80% depending on the underlying medical conditions and site of infection [10]. Unilateral facial edema, sinus pain, cranial nerve, palsy proptosis, periorbital swelling, and palatal or palpebral fistula developing into necrosis are commonly present.



**Figure 4:** Photomicrograph of the H and E stained histological section under 4× reveals respiratory epithelium lining with underlying stroma showing dense collection of inflammatory cells and congested blood vessels. It also shows extensive area of necrosis with broad aseptate fungal hyphae with acute angle branching and bony spicules. Angioinvasion was evident suggestive of invasive mucormycosis

The dental professionals play a pivotal role in the early diagnosis of mucormycosis as the disease presents as a palatal ulcer in the majority of the cases and as in the above patient. The clinical differential diagnosis of mucormycosis includes tertiary syphilis, Wegener's granulomatosis, carcinoma of the palate (squamous cell carcinoma/mucoepidermoid carcinoma), midline lethal granuloma, osteomyelitis, tuberculosis, other deep fungal infections, and ulcer due to bisphosphonate therapy [11]. Intraoral gummas/syphilitic ulcers occur most often in the midline of the palate with a reddish-brown ulcer and a copper halo surrounding [12]. Wegener's granulomatous rarely presents with a palatal ulcer but can be easily distinguished by systemic involvement (kidney, lung, and upper respiratory tract). Additional elevation of the serum creatinine and antineutrophil cytoplasmic antibodies is present in nearly 90% of the patients. Squamous cell carcinoma and mucoepidermoid carcinoma appear as deep ulcers with a firm, raised, and rolled borders. The ulcer in the posterolateral region of the hard palate is most likely to be mucoepidermoid carcinoma since the hard palate is an unlikely site for squamous cell carcinoma [12]. The midline lethal granuloma involving the palate cause perforation and is usually bordered by inflamed granulation tissue. Several biopsies are often required before a definitive diagnosis can

be made [13]. Oral lesions/ulcers are present in less than 0.1% of tuberculosis patients [14]. A typical lesion appears with ragged undermined edges, minimal induration, and often with a yellowish apple jelly-like granular base. Ulcers which occur secondary to the systemic disease are usually short term, but they may persist if the predisposing systemic disease is not managed [12]. These ulcers secondary to systemic disease are usually painful and have minimal bases in contrast to early squamous cell carcinoma or early mucoepidermoid tumors. A traumatic ulcer can generally be ruled out by establishing the absence of physical injury [12].

Direct clinical examination, fungal culture, histopathology, and radiological (computed tomography and magnetic resonance imaging) examination are the main diagnostic modalities of mucormycosis. Direct microscopy shows hyphae of variable width (6–25  $\mu\text{m}$ ), non-septate or pauciseptate, and an irregular/ribbon-like appearance. The angle of the hyphae branching is variable and includes wide angle (90°) bifurcations.

The treatment modalities of mucormycosis include the risk stratification for the severity of the disease condition and early clinical and laboratory diagnosis. Effective antifungal therapy (monotherapy or combination therapy), aggressive surgical debridement of necrotic debris, a reversal of immunosuppression (discontinuation of the chemotherapy and increase of immune cells), and management of the underlying medical condition are the treatment modalities followed in mucormycosis [3]. Amphotericin B is the mainstay antifungal treatment and isavuconazole or posaconazole may be administered as maintenance therapy [15]. Endoscopic endonasal surgical debridement, pansinusectomy, maxillectomy, orbital decompression, orbital exenteration, and intracranial surgery are the common surgical modalities.

This clinical presentation is not very uncommon in a dental health-care setting. Hence, intricate history taking and elaborate knowledge of the pathogenesis of the disease by an oral diagnostician yields a precise diagnosis of this disease. Routine testing should include complete and differential blood cell counts, erythrocyte sedimentation rate, hepatic profile, and renal chemistry profile [12]. Radiological diagnosis by intraoral periapical radiograph, occlusal radiography, orthopantomography, and cone-beam computed tomography may aid in establishing a provisional diagnosis. The proper diagnosis by an oral diagnostician and interdisciplinary management aids in a positive prognosis of the disease.

## CONCLUSION

Mucormycosis is a fulminant, uncommon fungal infection with a persistently high mortality rate predominantly in an immunocompromised patient. Ambiguous and elusive clinical presentation of the disease delays the diagnosis which leads to significant tissue damage. Higher suspicion index facilitates early diagnosis of the mucormycosis by the oral diagnosticians with a multidisciplinary approach. Early diagnosis allows aggressive control of the underlying medical condition and timely initiation of the therapy and surgical debridement which is necessary for proper healing, reducing the morbidity and mortality.

## REFERENCES

1. Pillsbury H, Fischer M. Rhinocerebral mucormycosis. *Arch Otolaryngol* 1977;103:600-4.
2. Sugar AM. Mucormycosis. *Clin Infect Dis* 1992;14:S126-9.
3. Sipsas NV, Gamaletsou MN, Anastasopoulou A, Kontoyiannis DP. Therapy of mucormycosis. *J Fungi (Basel)* 2018;4:90.
4. Lehrer RI, Howard DH, Sypherd PS, Edwards JE, Segal GP, Winston DJ. Mucormycosis. *Ann Intern Med* 1980;93:93-108.
5. Chakrabarti A, Singh R. Mucormycosis in India: Unique features. *Mycoses* 2014;57:85-90.
6. Paltauf A. Mycosis mucorina. *Arch Pathol Anat Physiol Klin Med* 1885;102:543-64.
7. Jayachandran S, Krithika C. Mucormycosis presenting as palatal perforation. *Indian J Dent Res* 2006;17:139-42.
8. Jeong W, Keighley C, Wolfe R, Lee WL, Slavin MA, Kong DC, *et al.* The epidemiology and clinical manifestations of mucormycosis: A systematic review and meta-analysis of case reports. *Clin Microbiol Infect* 2019;25:26-34.
9. Nussbaum ES, Hall WA. Rhinocerebral mucormycosis: Changing patterns of disease. *Surg Neurol* 1994;41:152-6.
10. Roden MM, Zaoutis TE, Buchanan WL, Knudsen TA, Sarkisova TA, Schaufele RL, *et al.* Epidemiology and outcome of zygomycosis: A review of 929 reported cases. *Clin Infect Dis* 2005;41:634-53.
11. Kyrmizakis DE, Doxas PG, Hajitioannou JK, Papadakis CE. Palate ulcer due to mucormycosis. *J Laryngol Otol* 2002;116:146-7.
12. Wood NK, Goaz PW. Oral ulcers and fissures. In: Wood NK, Goaz PW, editors. *Differential Diagnosis of Oral Lesions*. St. Louis: C.V. Mosby; 1980. p. 162-82.
13. Cottrell DA, Mehra P, Malloy JC, Ghali GE. Midline palatal perforation. *J Oral Maxillofac Surg* 1999;57:990-5.
14. Farber JE, Friedland E, Jacobs WE. Tuberculosis of the tongue. *Am Rev Tuber* 1940;42:766-75.
15. Jayachandran S, Jayaram V. Mucormycosis of maxilla: A multifarious disease: A report of two cases. *J Int Med Sci Acad* 2018;31:177-80.

*Funding: None; Conflicts of Interest: None Stated.*

**How to cite this article:** Nagarajan N, Jayachandran S, Vidya J. Clinical approach to palatal necrosis in an immunocompromised patient: A dental professional's role. *Indian J Case Reports*. 2020;6(11):625-628.