

## Vanishing headache in a young female: An interesting case report

D Balasubramanian<sup>1</sup>, V Chandramouleeswaran<sup>1</sup>, S Balasubramanian<sup>1</sup>, R Lakshmi Narasimhan<sup>1</sup>, V Kannan<sup>2</sup>, A Nithyanandam<sup>2</sup>, S Venkatesan<sup>2</sup>

From <sup>1</sup>Professor; <sup>2</sup>Assistant Professor, Department of Neurology, Institute of Neurology and Neurosurgery, Madras Medical College, Chennai, India.

**Correspondence to:** Dr V. Chandramouleeswaran, House no-44, Bhuvanewari Street, Madipakkam, Chennai, Tamil Nadu - 600091, India. E-mail: drvcmdp@gmail.com.

Received - 11 April 2019

Initial Review - 03 May 2019

Accepted - 18 May 2019

### ABSTRACT

Headache is one of the most common neurological symptom occurring worldwide. Here, we present a unique case of secondary headache in a young female which got reversed with appropriate treatment. A young female who presented with a severe subacute unilateral left-sided intractable headache with papilledema and obstructive hydrocephalus was found to have 4<sup>th</sup> ventricular neurocysticercosis causing obstruction of the foramen of Magendi and Luschka, relieved on timely surgical excision and with medical management. This case is reported to highlight the rare causes of secondary headache and various presentations of neurocysticercosis, in endemic areas like India as it causes neurological morbidity which can be alleviated on appropriate treatment, thereby preventing economic hardship and improving the quality of life.

**Keywords:** Headache, Neurocysticercosis, Reversible, *Taenia solium*.

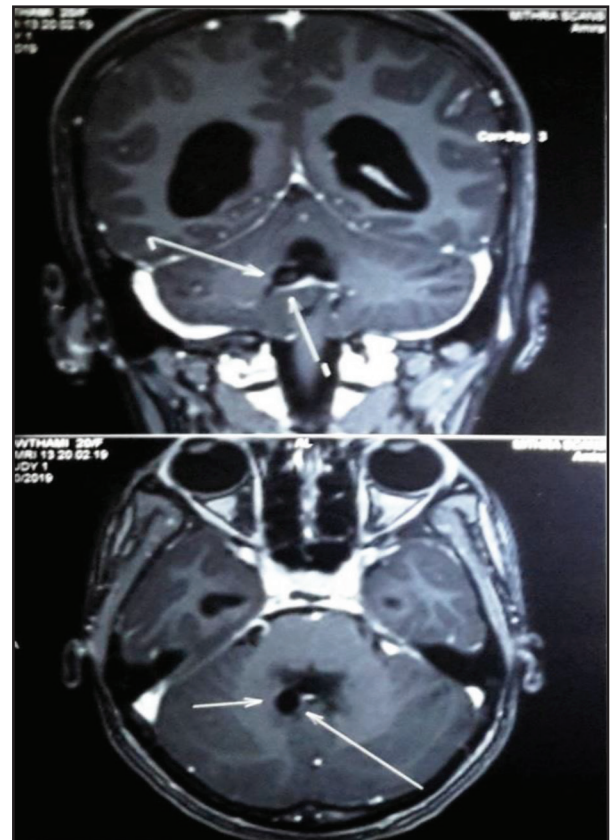
**H**eadache is a common neurological symptom presenting to neurology outpatient department. The headache is classified into two main groups: primary headache, which is the most common and secondary headache which is due to various etiologies such as intracranial mass lesions, giant cell arteritis, CNS infection etc [1]. Cysticercosis is one of the rare cause of secondary headache often encountered in endemic countries like India. Cysticercosis is a parasitic infection that results from ingestion of eggs of the adult pork tapeworm, *Taenia solium* (*T. solium*). Neurocysticercosis results from the hatching of larval forms in the digestive tract, which then penetrates the gut wall and spread via the bloodstream to encyst in the central nervous system (CNS). The resultant symptoms and pathology vary with the final resting site of the cysts in the CNS [2-4].

We present a rare cause of secondary headache in an endemic region of cysticercosis with the unusual manifestation of unilateral headache. The case highlights the need to exclude various causes of secondary headache so that early intervention and appropriate treatment cures it.

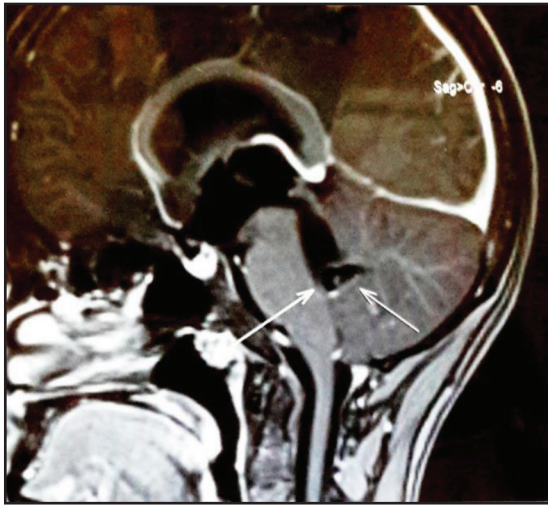
### CASE REPORT

A 20-year-old female from a rural village of Tamil Nadu presented with a severe dull aching headache for the past one and half months which was predominantly left-sided, continuous associated with nausea and vomiting without any visual disturbances, postural imbalance, focal weakness, and seizures. There was no history of fever, nodular skin lesions,

rash or multiple joint pain and loss of weight/appetite. No history of any co-morbid conditions.



**Figure 1:** T1 contrast MRI Brain axial and coronal cut showing cystic lesion in 4th ventricle with obstructive hydrocephalus.

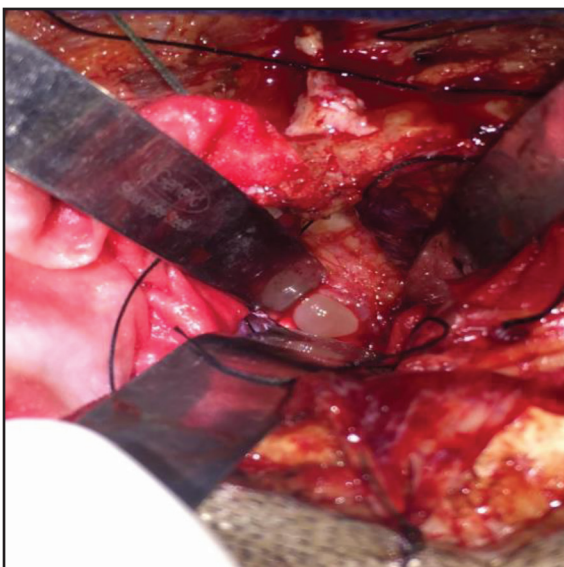


**Figure 2:** T1 contrast sagittal cut showing neurocysticercosis in 4th ventricle.

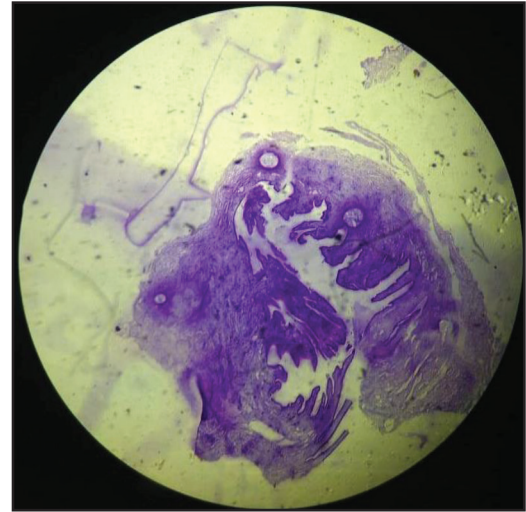
On examination, the patient was conscious oriented. Blood pressure was 130/80 mmHg, pulse rate was 82/minute and respiratory rate was 16/minute. Neurological examination revealed bilateral papilledema with an enlarged blind spot, however, rest neurological examinations were normal. Her other system examination was normal.

Routine blood examination including complete blood count, liver function test (LFT), renal function test (RFT) was normal. On brain magnetic resonance imaging (MRI), there was a cyst with eccentric scolex in the 4<sup>th</sup> ventricle causing obstructive hydrocephalus (Fig. 1 and 2).

The patient was started on Albendazole 400mg BID with steroids. The patient underwent surgical excision of the cyst within a week. The cyst was approached through sub-occipital craniotomy through an incision extending from the external occipital protuberance to the spinous process of C7 cervical spine. Duramater was opened in a Y-shaped manner. The fourth ventricle was approached using a vermian split approach (Fig. 3). The cyst was a transparent structure of 2cm in size with a



**Figure 3:** Peroperative picture showing cyst in the 4th ventricle



**Figure 4:** Histopathology picture showing scolex with H & E stain

central nodule lying on the floor of the fourth ventricle. Complete excision of the cyst done in toto. After securing hemostasis, the closure was done in layers. On microscopic examination, the cyst showed scolex on H & E confirming active neurocysticerci (Fig. 4). The patient showed dramatic relief from headache after surgery and papilledema resolved within 2 weeks time. The patient is on follow-up and doing well with a resolution of symptoms and papilledema.

## DISCUSSION

The lifetime prevalence of any type of headache as estimated from population-based studies is more than 90% for men and 95% for women [5]. The extraparenchymal disease varies in its symptoms and prognosis according to the location of the parasites. The prognosis for intraventricular neurocysticercosis is worse than that for the intraparenchymal forms of the disease [6].

As a result of the mass effect, distortion of the normal anatomy of CSF pathways, direct obstruction of the ventricular system by a cyst, or an inflammatory reaction in the meninges leading to arachnoiditis, there will be an increase in intracranial CSF pressure. In our patient, CSF obstruction due to a cyst in the 4<sup>th</sup> ventricle causing obstruction of the foramen of Magendi and Luschka resulting in obstructive hydrocephalus with dilated lateral and 3<sup>rd</sup> ventricle with increasing intracranial pressure producing a severe intractable headache.

The various clinical presentations of the disease are due to the underlying different pathological processes which include space occupation, inflammation around the cyst, impaired cerebrospinal fluid flow, meningeal inflammation and vasculitis [7,8]. The most common presentation is a seizure (70–90% of patients) [9]. In 10%-20% of cases, symptoms are non-specific like nausea, vomiting, headache, ataxia, and confusion due to ventricular cysts. Hydrocephalus, vasculitis, and stroke can be a presentation of cysts of the basal cisterns. Rarer manifestations, like altered mental state, spinal cysticercosis with radicular

pain, paresthesia, progressive cord compression, ophthalmic cysticercosis, migraine headaches, neurocognitive deficits, and cerebral oedema are common in young girls [9]. The commonest pathological presentations are degenerating or calcified cyst (52%), followed by leptomeningitis (48%), which is most often basal and may cause hydrocephalus. In intraventricular forms, the 4th ventricle is most frequently involved; the cyst may attach to the ventricular wall.

A set of diagnostic criteria was proposed in 1996 and recently revisited to diagnose neurocysticercosis. Proper interpretation of these criteria permits two degrees of diagnostic certainty: definite or probable [10]. MRI is more accurate than computed tomography (CT) for the diagnosis of neurocysticercosis. In our case, MRI was used for the diagnosis of neurocysticercosis.

Treatment options include antihelminthic drugs (albendazole, praziquantel), surgery, and symptomatic medications. As inflammation is the conspicuous accompaniment in most forms of neurocysticercosis, corticosteroids are the mainstay in the treatment for cysticercal encephalitis, meningitis, and angiitis. The preferred drug is Albendazole which has got higher CSF penetration independent of steroid concentration [9,11].

Extra-parenchymal cysticercosis is associated with poor prognosis and requires a more aggressive approach. When feasible, complete surgical excision of lesions remains the definitive therapy [7,8]. The most common surgical indication for neurocysticercosis is ventricular neurocysticercosis causing obstructive hydrocephalus. Sometimes neurocysticercosis remains in the brain without causing any apparent symptoms; this form is called as asymptomatic neurocysticercosis [12,13].

## CONCLUSION

Neurocysticercosis is a chronic parasitic disease that remains endemic in developing countries like India and has increasingly affecting developed countries also due to increased migration, tourism, and travel to endemic areas. This case has been presented to highlight the potentially treatable cause of subacute headache in a young female with neurocysticercosis. Appropriate measures

like health education, mass awareness, deworming may help to reduce the disease burden in the endemic areas.

## REFERENCES

1. Mateen FJ, Dua T, Steiner T, Saxena S. Headache disorders in developing countries: research over the past decade. *Cephalalgia*. 2008;28(11):1107-14.
2. Esberg G, Reske-Nielsen E. Sudden death from cerebral cysticercosis. *Scand J Infect Dis*. 1988;20:679-84.
3. Bent MH, Moulounguet A, Romano P, Gray F. Confrontation at the Salpêtrière hospital. May 1991. Cephalalgia developing in depressive background and sudden death in a 26 year-old woman. *Revue neurologique*. 1993;149(5):362-6.
4. Ndhlovu CE. An uncommon presentation of cysticercosis. *Cent Afr J Med* 1997;43:207-9.
5. Daroff, Robert B, and W G. Bradley. *Bradley's Neurology in Clinical Practice*. Philadelphia, PA: Elsevier/Saunders, 2016, 7th edition, 103 - 1686.
6. Takayanagui OM, Odashima NS. Clinical aspects of neurocysticercosis. *Parasitology International*. 2006;55:S111-5.
7. Gubbay AD, Brophy BP, Henley S, Sage M. Neurocysticercosis. *J Clin Neurosci*. 1998;5:203-7.
8. Pitella JEH. Neurocysticercosis. *Brain Pathol*. 1997;7:681-93.
9. Deb KP, Carpio A, Sander JWAS. Neurocysticercosis and epilepsy in developing countries. *J Neurol Neurosurg Psychiatry*. 2000;68:137-43.
10. Del Brutto OH, Rajshekhkar V, White AC Jr, Tsang VC, Nash TE, Takayanagui OM *et al.* Proposed diagnostic criteria for neurocysticercosis. *Neurol*. 2001;57:177-83.
11. Matthaïou DK, Panos G, Adamidi ES, Falagas ME. Albendazole versus praziquantel in the treatment of neurocysticercosis: a meta-analysis of comparative trials. *PLoS neglected tropical diseases*. 2008;12;2(3):e194.
12. Montano SM, Villaran MV, Ylquimiche L, Figueroa JJ, Rodriguez S, Bautista CT, *et al.* Neurocysticercosis: association between seizures, serology, and brain CT in rural Peru. *Neurology*. 2005;65:229-33.
13. Prasad A, Gupta RK, Pradhan S, Tripathi M, Pandey CM, Prasad KN. What triggers seizures in neurocysticercosis? A MRI-based study in pig farming community from a district of North India. *Parasitology international*. 2008;57(2):166-71.

*Funding: None; Conflict of Interest: None Stated.*

**How to cite this article:** Balasubramanian D, Chandramouleswaran V, Balasubramanian S, Narasimhan RL, Kannan V, Nithyanandam A, *et al.* Vanishing headache in a young female: An interesting case report. *Indian J Case Reports*. 2019;5(3):247-249.

Doi: 10.32677/IJCR.2019.v05.i03.017