

## Massive hemorrhagic pleural effusion - A rare presentation of acute pancreatitis

Javed Ismail, Gautam Kamila, Mullai Baalaji

From Department of Pediatrics, Advanced Pediatric Centre, Post Graduate Institute of Medical Education and Research, Chandigarh, India

**Correspondence to:** Javed Ismail, Pediatric Intensive Care Unit, Level-3B, Department of Pediatrics, Advanced Pediatric Centre, Post Graduate Institute of Medical Education and Research, Sector 12, Chandigarh - 160012, India. E-mail: javedisi86@gmail.com

Received - 27 December 2018

Initial Review - 24 January 2019

Accepted - 01 February 2019

### ABSTRACT

Acute pancreatitis typically presents with a sudden-onset severe epigastric pain radiating to the back. Presentation with respiratory distress secondary to massive pleural effusion has been rarely reported. We report a 12-year-old girl presenting with complaints of fever, cough, dyspnea, and chest pain. Her chest radiograph showed massive pleural effusion and the pleural fluid amylase was markedly elevated. The patient recovered gradually with conservative medical management and the right side chest tube drainage. This report highlights the rare presentation of pancreatitis which requires a high index of suspicion for prompt diagnosis.

**Key words:** Acute pancreatitis, Child, Pleural effusion

Minimal reactive pleural effusion with elevated amylase levels is common in acute pancreatitis. Typically, they present with severe abdominal pain radiating to the back which was accompanied with nausea and vomiting. Respiratory distress with bilateral pleural effusion as a presenting manifestation of acute pancreatitis is relatively uncommon in adults [1,2] and only a few case reports exist in children [3,4]. We report a case of pancreatitis with massive hemorrhagic pleural effusion with respiratory distress as the sole manifestation.

### CASE REPORT

A 12-year-old girl presented with 10 days' history of cough and progressively worsening dyspnea. She was managed as a case of right pleural effusion under evaluation for 5 days before referral to our hospital. On further probing, there was a vague intermittent epigastric pain sometimes radiating to the back about 15 days prior, which subsided over the next 3 days. She was presented to our pediatric emergency ward in respiratory distress with examination findings suggestive of the right-sided pleural effusion. Chest X-ray was suggestive of bilateral pleural effusion (right>left) (Fig. 1a). Diagnostic thoracentesis revealed hemorrhagic pleural effusion and intercostal drainage tube was inserted in view of respiratory distress due to pleural effusion.

Pleural fluid cytology revealed 1200 white blood cells/mm<sup>3</sup> with 90% polymorphs, 10% lymphocytes, and red blood cells full field. Acid-fast staining was negative and cultures were sterile. Pleural fluid for malignant cytology was also negative. Pleural fluid protein was elevated (4 g/dl), the initial reports suggesting exudative effusion. Pleural fluid amylase was elevated out of the range of laboratory estimation and serum amylase was 1154 U/L. She had an elevated total leukocyte count (20,100/mm<sup>3</sup>) with

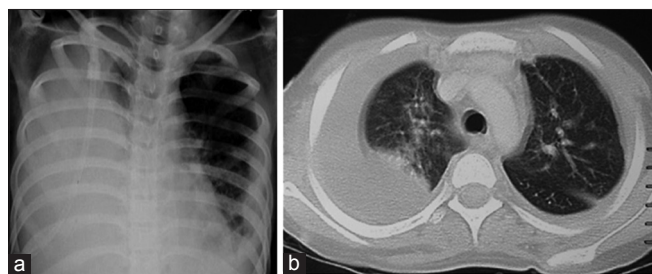
elevated CRP (166.07 mg/L), normal platelet count (528,000/mm<sup>3</sup>), and normal coagulation studies. Liver enzymes were within normal limits (SGOT - 30 U/L and SGPT - 18 U/L). A diagnosis of acute pancreatitis with complicating pleural effusion was made.

Further, investigations were done to determine the etiology of acute pancreatitis. Contrast-enhanced computed tomography (CT) of chest and abdomen revealed bilateral pleural effusion (right >> left) (Fig. 1b) and dilated main pancreatic duct (MPD) involving head and proximal body with ill-defined soft tissue density seen within the duct in the region of the head and the MPD measuring around 8 mm. Magnetic resonance cholangiopancreatography revealed a dilated MPD (8 mm) with multiple T2 hypointense filling defects suggestive of intraductal calculi. The lobulated insinuating T2 hyperintense collection was posterior to the tail of the pancreas, superiorly extending along the esophageal hiatus into the posterior mediastinum (Fig. 2).

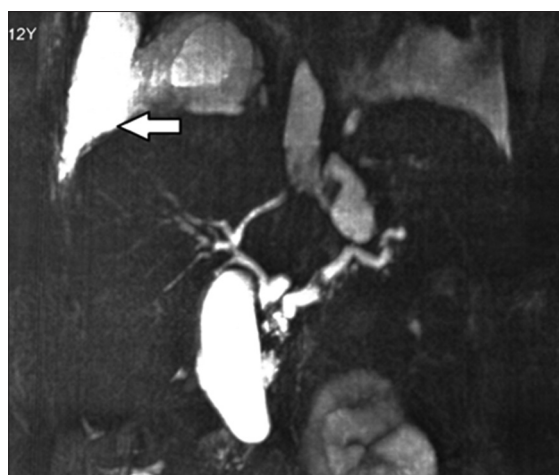
The cause of pancreatitis was probably the presence of calculi in the MPD. The child was managed conservatively and the clinical symptoms, dyspnea, chest pain improved over 2 weeks, and pleural effusion decreased over the next 3 weeks. The child was discharged after 4 weeks of hospital stay.

### DISCUSSION

Common causes of hemorrhagic pleural effusion are trauma, intrathoracic neoplasms, bleeding diathesis, vascular malformations, and chronic anticoagulant medication. Respiratory distress with bilateral massive pleural effusion, as the sole presenting manifestation of acute pancreatitis, has rarely been reported in children [3,4]. The postulated mechanisms for hemorrhagic effusion in acute pancreatitis are the action of proteolytic enzymes on pleural capillaries producing erosion and disturbance of the



**Figure 1:** (a) Chest X-ray PA view showing bilateral pleural effusion (Right >> Left), (b) Computed tomography chest showing bilateral pleural effusion with massive collection on the right pleural cavity



**Figure 2:** Magnetic resonance cholangiopancreatography showing dilated main pancreatic duct and peripancreatic collections with enhancement in the right pleural cavity (arrow)

clotting mechanism, leading to fall in antithrombin levels or a possible communication of a pancreatic pseudocyst with the pleural space. The possible mechanism of the fistula connecting pancreatic pseudocyst with pleural cavity seems more likely [5-7].

Most of the pleural effusions due to pancreatitis are reactive in nature, with only a mild elevation of pleural fluid amylase level. However, high levels can be explained by rupture of a pancreatic pseudocyst into the pleural cavity [8]. In the index case, rupture of any of the collections into the pleural cavities is the possible cause of hemorrhagic pleural effusion and high pleural fluid amylase levels (Fig. 2). Other conditions which can cause elevated pleural fluid amylase levels are malignant tumors and esophageal rupture [9].

In most of the cases reported, the pleural effusion occurs concomitantly with the signs and symptoms of pancreatitis. On the contrary, the index child manifested predominantly with pleuropulmonary symptoms, and the pancreatic condition remained in the background. While pleural fluid amylase levels provide an early clue, the abdominal CT scan aids in rapidly establishing the diagnosis. Treatment is conservative with drainage by a chest tube to relieve respiratory distress, and the effusion tends to resolve over days.

## CONCLUSION

Respiratory distress with bilateral massive pleural effusion is a rare manifestation of acute pancreatitis. Pleural fluid amylase helps in rapid diagnosis.

## REFERENCES

1. Dixit R, Sharma S, Dave L. Massive haemothorax in asymptomatic pseudocyst pancreas. *Lung India* 2008;25:126-8.
2. Gowrinath K, Raghavendra C. Massive recurrent pleural effusion in a 35-year-old non-smoking male. *Indian J Chest Dis Allied Sci* 2015;57:107-8.
3. Raghu MB, Balasubramanian S, Balasubramanyam G. Hemorrhagic pleural effusion-sole manifestation of pancreatitis. *Indian J Pediatr* 1992;59:767-9.
4. Namazi MR, Mowla A. Massive right-sided hemorrhagic pleural effusion due to pancreatitis; A case report. *BMC Pulm Med* 2004;4:1.
5. Imai Y, Taniguchi M, Tagawa K, Toda N, Tanzawa Y, Okamoto M, *et al.* A case of chronic pancreatitis complicated by massive pericardial and right pleural effusion. *Gastroenterol Jpn* 1993;28:734-8.
6. Dewan NA, Kinney WW, O'Donohue WJ Jr. Chronic massive pancreatic pleural effusion. *Chest* 1984;85:497-501.
7. Gumaste V, Singh V, Dave P. Significance of pleural effusion in patients with acute pancreatitis. *Am J Gastroenterol* 1992;87:871-4.
8. Siwczyński H. Chronic pleural effusion from the pancreas. *Wiad Lek* 1998;51:190-5.
9. Gupta D, Chakraborty KL, Gomber S, Krishna A, Mehrotra G. Massive pancreatico-pleural effusion-an often unrecognised entity. *Indian J Pediatr* 2001;68:883-5.

*Funding: None; Conflict of Interest: None Stated.*

**How to cite this article:** Ismail J, Kamila G, Baalaji M. Massive hemorrhagic pleural effusion - A rare presentation of acute pancreatitis. *Indian J Child Health*. 2019; 6(2):95-96.

Doi: 10.32677/IJCH.2019.v06.i02.011