

## Herpes simplex virus encephalitis in an 8 years old with normal cerebrospinal fluid and negative herpes simplex virus polymerase chain reaction - A clinical and radiological diagnosis

Parminder Singh<sup>1</sup>, Divya Gupta<sup>2</sup>

From <sup>1</sup>Departments of Pediatrics and <sup>2</sup>Pathology, Base Hospital, Tezpur, Assam, India

**Correspondence to:** Parminder Singh, Department of Pediatrics, 155 Base Hospital, Tezpur, Assam – 784 001, India.

E-mail: param\_rules@yahoo.co.in

Received - 02 December 2018

Initial Review - 18 December 2018

Accepted - 26 December 2018

### ABSTRACT

Herpes simplex encephalitis is known to cause significant morbidity and mortality both in children and adults. Polymerase chain reaction (PCR) for herpes simplex virus (HSV) in cerebrospinal fluid (CSF) is the diagnostic modality accepted worldwide. However, a negative CSF HSV PCR result should always be interpreted in the context of the timing of specimen collection and also considering the clinical picture. We report a case of HSV encephalitis in an 8-year-old male child whose initial CSF picture was normal and CSF for HSV PCR was also negative. However, the magnetic resonance imaging brain findings and clinical profile along with a marked response to acyclovir therapy started very early in the course of illness left little doubts about the diagnosis.

**Key words:** *Acyclovir, Herpes simplex virus encephalitis, Polymerase chain reaction negative, Temporal lobe involvement*

Encephalitis caused by herpes simplex virus (HSV) is the most common cause of sporadic (non-epidemic) encephalitis in the United States, with an incidence of approximately 4 cases/million [1,2]. In large number of such cases of the suspected viral encephalitis (60–70%), the etiology at times remains uncertain due to various causes. However, studies suggest that HSV accounts for 35-50 % of all cases where an etiology has been found.

Overall, mortality due to this condition has decreased from 70% in the past before the use of acyclovir to <20% in the present scenario [3,4]. However, there are inadequate data on the number of acute encephalitis syndrome due to HSV in the Indian setting [5]. It causes such significant morbidity that only 2–3% of patients survive with a fully normal neurological function. Although anterograde memory is most commonly impaired, retrograde memory, executive function, and language ability may also be compromised [3]. The diagnosis of choice is cerebrospinal fluid-polymerase chain reaction (CSF-PCR) for HSV. Other tests such as electroencephalogram (EEG), computed tomography, and magnetic resonance imaging (MRI) which have characteristic findings may also aid in the diagnosis [2,3]. However, PCR in the very early course of disease can be negative, and hence, a repeat lumbar puncture to decide the duration of the therapy has been advised [5-7].

### CASE REPORT

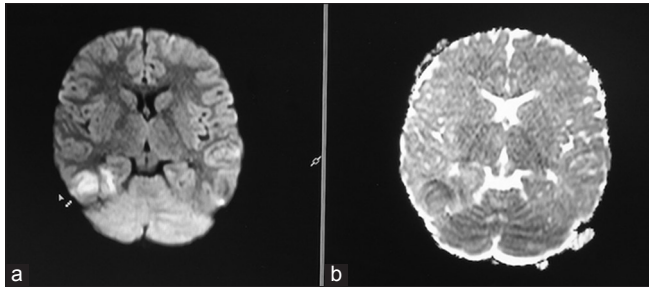
We present a case of an 8-year-old male child developmentally normal for his age with no significant past or family history

presented with fever, headache, and recurrent vomiting of 3 days duration. On examination, the child was disoriented, had abnormal behavior in the form of incomprehensible words, occasional agitation with excessive drowsiness. There were no signs of meningeal irritation or raised intracranial pressure or any focal neurological deficit.

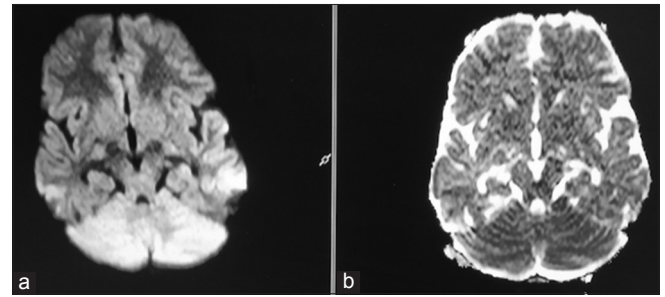
CSF study done at 36 h of presentation to the hospital was normal with few red blood cells. Based on the clinical profile, the child was empirically given injection ceftriaxone with injection acyclovir at 500 mg/m<sup>2</sup> 8 hourly. His blood investigations revealed neutrophilic leukocytosis with blood and urine culture showing no growth. MRI brain was done on day 3 of presentation revealed features of HSV encephalitis with asymmetrical temporal lobe involvement with mass effect as shown in Figs. 1 and 2.

However, PCR for HSV was negative. Since the child belonged to an endemic area for Japanese encephalitis (JE), CSF was also sent for JE virus studies, which was also found to be negative. Furthermore, investigation for HIV was also negative. EEG was normal with no characteristic finding of HSV encephalitis, i.e., periodic lateralized epileptiform discharges (PLEDs) as characteristic findings. Differential diagnosis considered in this case was JE, another viral encephalitis, NMDA encephalitis, and intracranial tumor.

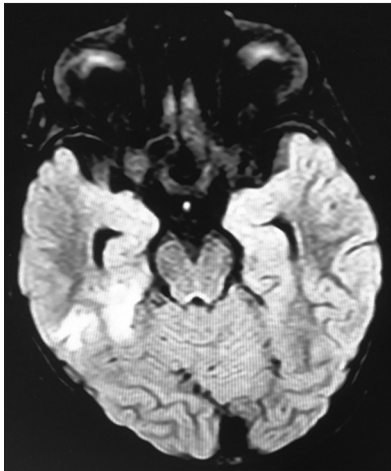
The child responded to acyclovir gradually and became asymptomatic after 5 days of hospitalization. However, acyclovir was continued for a total duration of 14 days. Since the child had recovered fully at the end of 14 days, a repeat lumbar puncture was not done. In the absence of the symptoms, marked response to



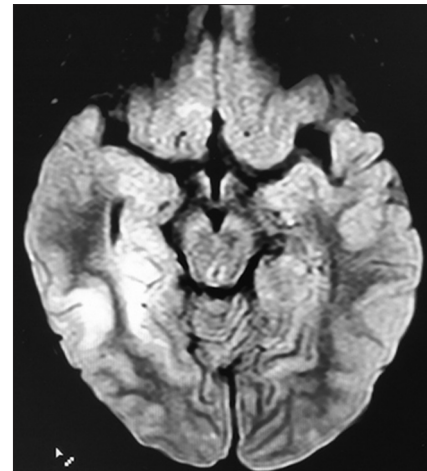
**Figure 1:** (a and b) Magnetic resonance imaging brain of the child at the time of presentation -diffusion-weighted image and analog-to-digital converter showing restriction of diffusion in the right temporal lobe



**Figure 3:** (a and b) Magnetic resonance imaging brain of the child after 1 month of treatment -diffusion-weighted image and analog-to-digital converter showing no restriction of diffusion in the right temporal lobe



**Figure 2:** Fluid attenuation inversion recovery sequence showing hyperintensity over right temporal lobe at the time of presentation



**Figure 4:** Fluid attenuation inversion recovery sequence repeated after 1 month showing reduction in area of hyperintensity involving right temporal lobe

the acyclovir therapy, and completion of recommended duration of antibiotics, the need for doing invasive procedure such as repeat CSF, to further confirm the diagnosis, seemed unjustified. However, many studies have advocated a repeat CSF study. The child was discharged without any neurological impairment (minor or major) which is uncommon in this disease. Repeat MRI scan of child after 1 month showed marked reduction in the size area involving temporal lobe when compared with previous MRI brain done on admission as shown in Figs. 3 and 4. The child remains on our follow-up and has shown no features of relapse till now.

## DISCUSSION

PCR in CSF is considered as the standard for the diagnosis of HSV encephalitis as it allows for the detection of minute quantities of the viral DNA or RNA present in fluids and tissues by nucleic acid amplification over a short time period [3,6]. Negative PCR tests are associated with low CSF protein and leukocyte counts, and in such cases, clinical suspicion should dictate the treatment course [8-11]. Possible explanations for a negative PCR result can be: PCR sent very early in the disease development (days 1-4 with neurological symptoms) and viral load too low for detection, although this is unlikely as PCR technique by virtue of the amplification process allows for the detection of minute amounts of viral copies, as low as 10 copies of viral inhibitors, and a small volume of CSF sample

[8,11]. Furthermore, variations in primers used during PCR processing, sample dilution, low CSF cell counts, and location of infection in the central nervous system could alter the result [8]. Studies have advocated a repeat CSF for PCR in later course of disease and deciding the course of antiviral therapy accordingly.

The most common areas of involvement are the medial temporal lobes, which are best observed with MRI. Sensitivity of MRI is best when done 48 h after the onset of symptoms and approaches 85%, although it can also be falsely negative in very early stages on infection [8]. The role of doing HSV viral studies in serum is also limited and non-specific; hence, it was avoided in our case. EEG may help in the diagnosis of HSE, demonstrating PLEDs as characteristic findings (PLEDs).

In our case, the clinical features, characteristic MRI findings with marked response to acyclovir therapy, leave little doubt about the diagnosis of HSE despite CSF PCR being negative. Medical literature is full of case reports with relapses in such patients, and hence, regular follow-up is advised [7-10].

## CONCLUSION

Early initiation of acyclovir therapy in a case of suspected HSV encephalitis can prevent mortality and neurological sequelae. Delay in initiation of acyclovir in view of initial CSF picture

being normal and CSF PCR being negative can prove to be fatal for the patient. In such cases, clinical wisdom must be applied and duration of the therapy should depend on the response and improvement in the neurological status of the patient.

## REFERENCES

1. Tyler KL. Update on herpes simplex encephalitis. *Rev Neurol Dis* 2004;1:169-78.
2. Dwibedi B, Rathore SK. Herpes simplex encephalitis in childhood. *J Infect Dis Ther* 2016;4:2
3. Skelly MJ, Burger AA, Adekola O. Herpes simplex virus-1 encephalitis: A review of current disease management with three case reports. *Antivir Chem Chemother* 2012;23:13-8.
4. McGrath N, Anderson NE, Croxson MC, Powell KF. Herpes simplex encephalitis treated with acyclovir: Diagnosis and long term outcome. *J Neurol Neurosurg Psychiatry* 1997;63:321-6.
5. Sharma S, Mishra D, Aneja S, Kumar R, Jain A, Vashishtha VM, *et al.* Consensus guidelines on evaluation and management of suspected acute viral encephalitis in children in India. *Indian Pediatr* 2012;49:897-910.
6. Puchhammer-Stöckl E, Heinz FX, Kundi M, Popow-Kraupp T, Grimm G, Millner MM, *et al.* Evaluation of the polymerase chain reaction for diagnosis of herpes simplex virus encephalitis. *J Clin Microbiol* 1993;31:146-8.
7. Weil AA, Glaser CA, Amad Z, Forghani B. Patients with suspected herpes simplex encephalitis: Rethinking an initial negative polymerase chain reaction result. *Clin Infect Dis* 2002;34:1154-7.
8. Adler AC, Kadimi S, Apaloo C, Marcu C. Herpes simplex encephalitis with two false-negative cerebrospinal fluid PCR tests and review of negative PCR results in the clinical setting. *Case Rep Neurol* 2011;3:172-8.
9. Lahat E, Barr J, Barkai G, Paret G, Brand N, Barzilai A, *et al.* Long term neurological outcome of herpes encephalitis. *Arch Dis Child* 1999;80:69-71.
10. De Tiège X, Rozenberg F, Burlot K, Gaudelus J, Ponsot G, Héron B, *et al.* Herpes simplex encephalitis: Diagnostic problems and late relapse. *Dev Med Child Neurol* 2006;48:60-3.
11. De Tiège X, Héron B, Lebon P, Ponsot G, Rozenberg F. Limits of early diagnosis of herpes simplex encephalitis in children: A retrospective study of 38 cases. *Clin Infect Dis* 2003;36:1335-9.

*Funding: None; Conflict of Interest: None Stated.*

**How to cite this article:** Singh P, Gupta D. Herpes simplex virus encephalitis in an 8 years old with normal cerebrospinal fluid and negative herpes simplex virus polymerase chain reaction - A clinical and radiological diagnosis. *Indian J Child Health*. 2018; 5(12):741-743.

Doi: 10.32677/IJCH.2018.v05.i12.009